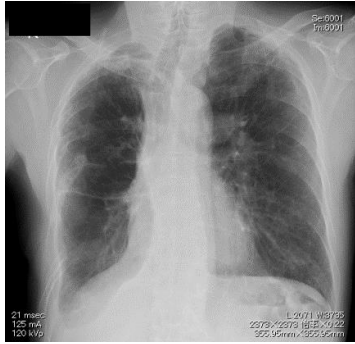


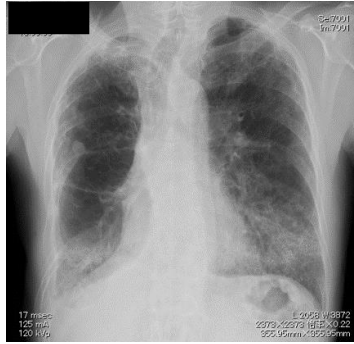
Supplementary Fig.1. Chest radiograph of the study patients before admission and during follow-up

A. Patient 1

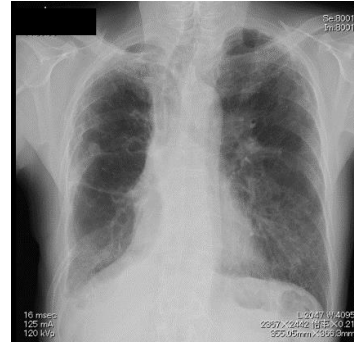
3 months before onset



2 weeks after vaccination

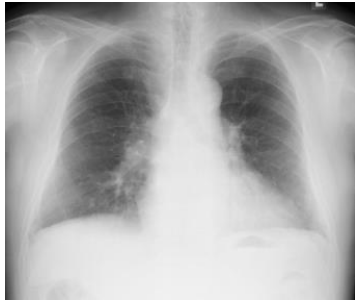

2 months after vaccination

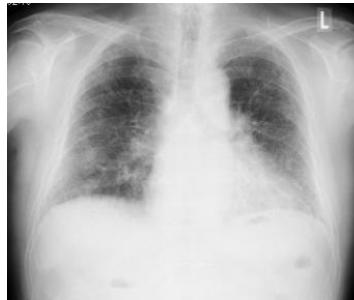

B. Patient 2

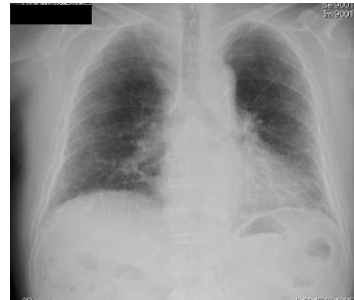18 months before onset



1 month after vaccination

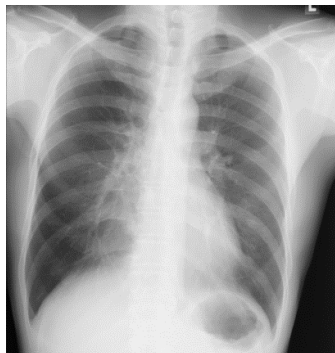


1 month after steroid administration

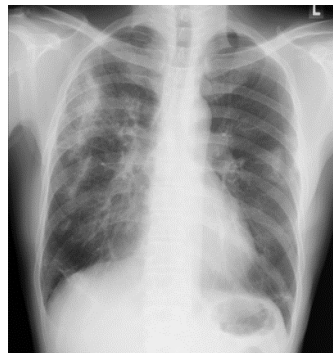


C. Patient 3

3 months before onset



10 days after second vaccination



10 days after steroid administration

