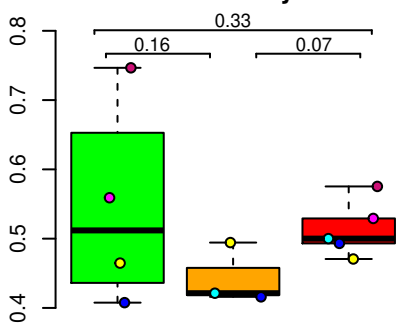
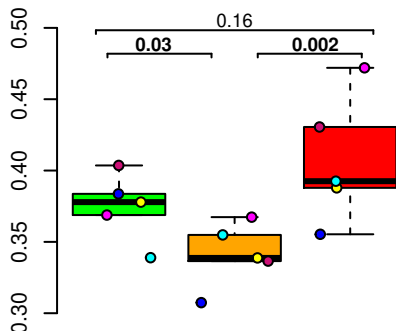


Mn

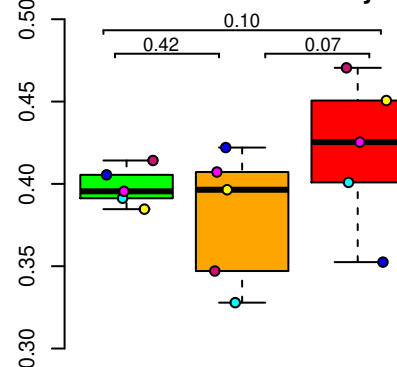
Olfactory bulb



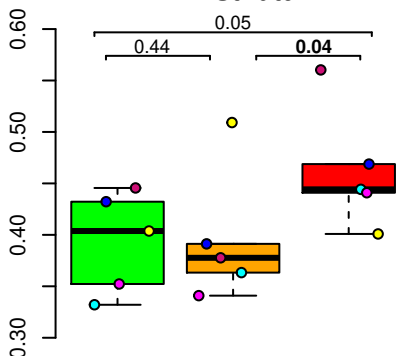
Anterior frontal cortex



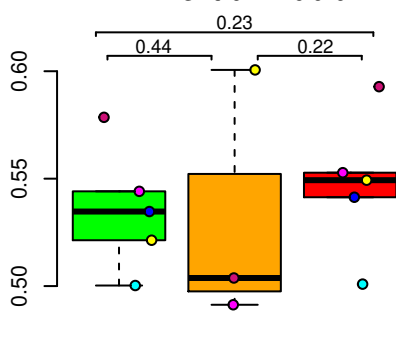
Motor-somatosensory cortex



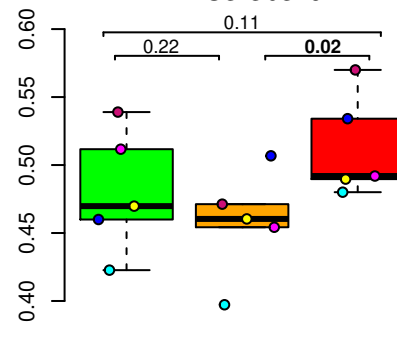
Striatum



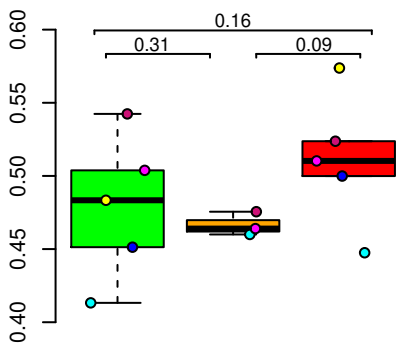
Ventral midbrain



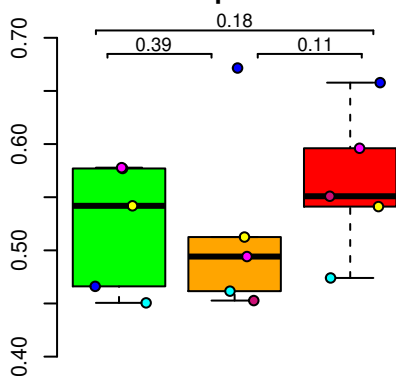
Cerebellum



Brainstem



Spinal cord



Remaining brain tissue

