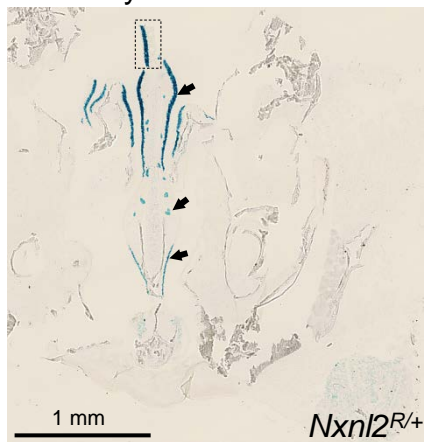
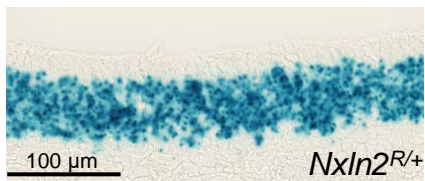


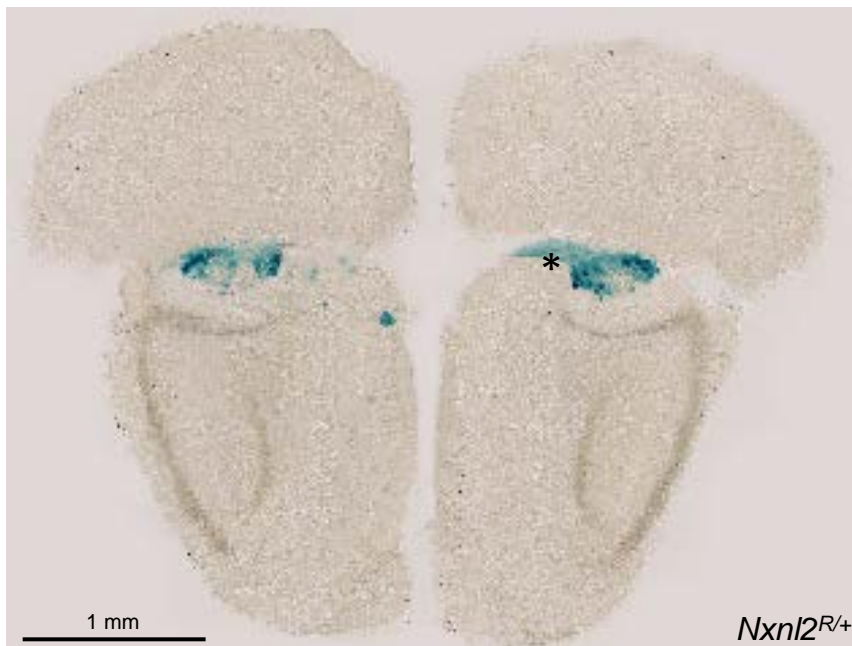
A Olfactory tube



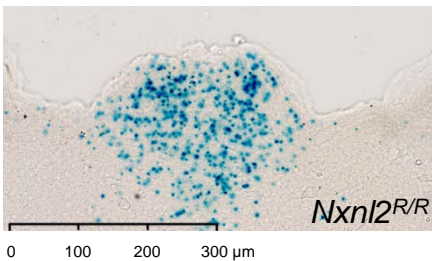
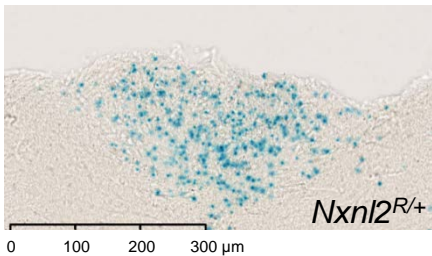
B





C



D *area postrema*



E Subfornical organ



F Median preoptic nucleus

