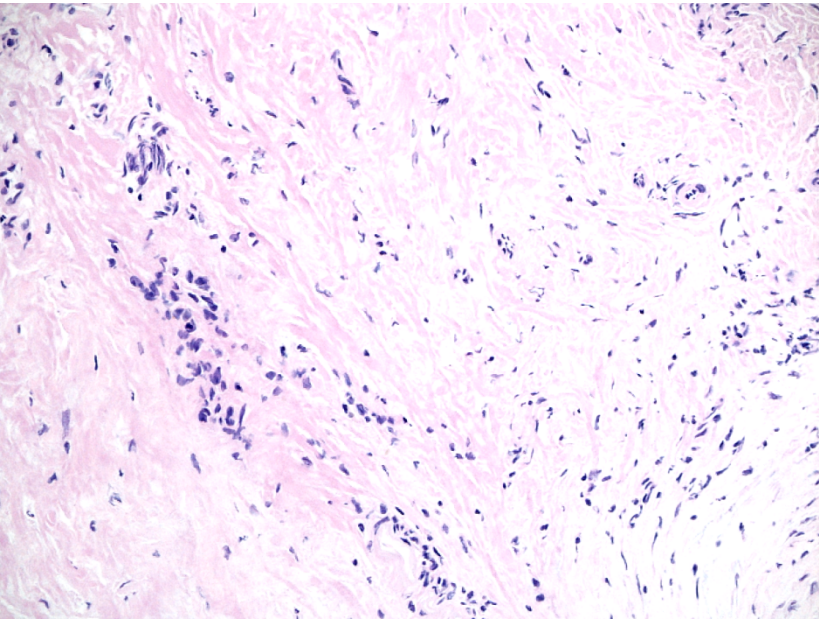
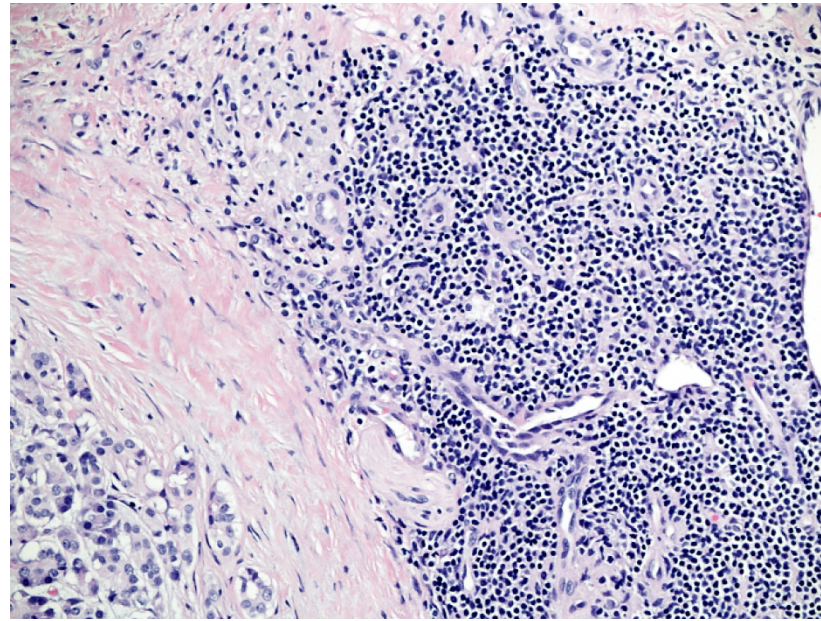


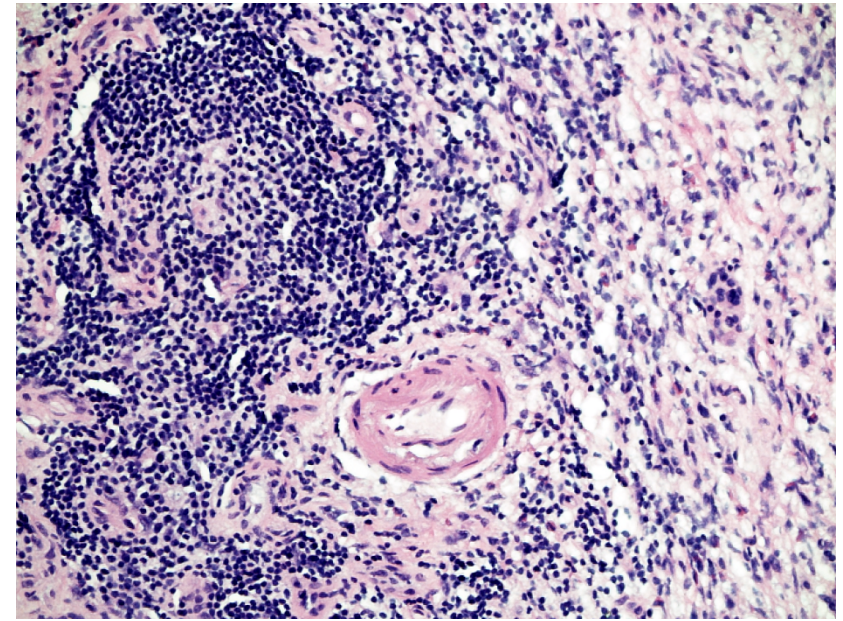
A



B



C



Additional Figure 2. Histological presentation of chronic inflammation. A. Mild chronic inflammation (H&E stain; 200X). B. Moderate chronic inflammation (H&E stain; 200X). C. Severe chronic inflammation (H&E stain; 200X).