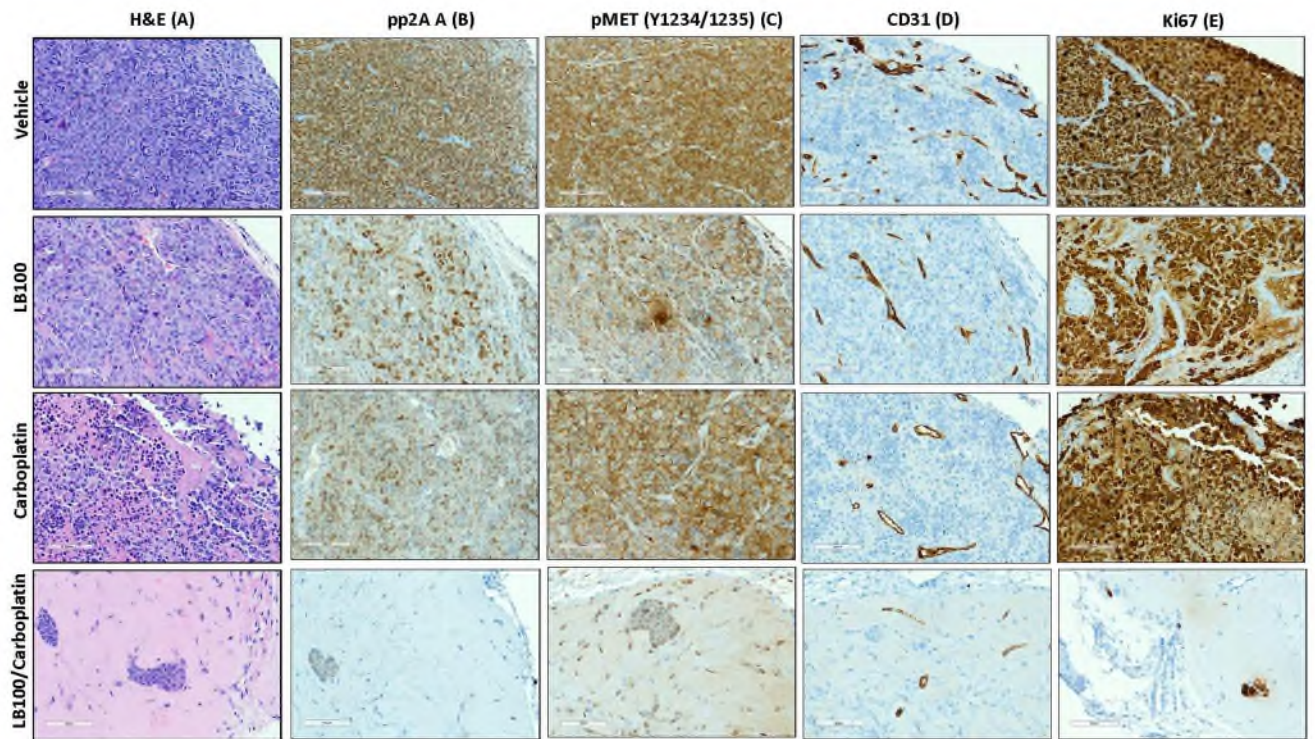


### Immunohistochemical staining

Histological sections at a thickness of 5  $\mu$ m were stained for the following markers: pp2A A and pMet (Tyr 1234/1235) from CST (City of Industry, CA), CD31 (VENTANA, clone JC70) and Ki67 (VENTANA, clone 30-9) in Pathology: Solid Tumor Core.

### Supplemental Figure 4



**Fig. S4. IHC evaluation of mouse tumors.** H&E staining of mouse tumors (A) showed dense nuclear staining and high number of mitotic cells. Treatment with LB100 or carboplatin increased the necrotic area in tumor tissue and combined treatment contained fewer tumor cells. IHC staining with PP2A A, pMET, CD31 (for angiogenesis) and Ki-67 (for cell proliferation) antibodies indicated reduction of staining intensity in tumor sections with combined treatment. Representative images of tumor sections are shown for each group. Scale bar 100  $\mu$ m.