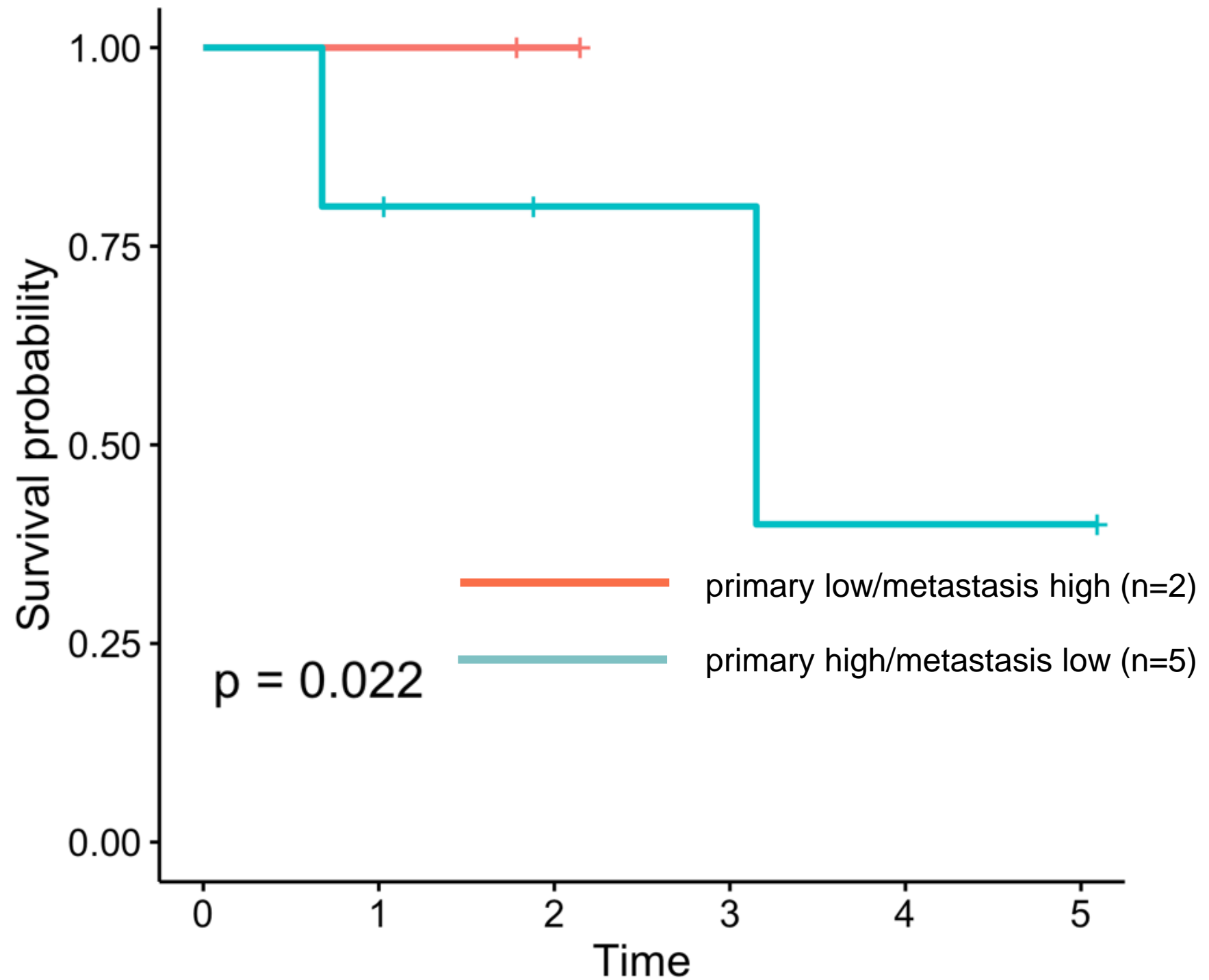


Supplementary Figure 1



Prognostic curve with TMB status divided into cases of primary high / metastasis low and primary low / metastasis high. As a result, the prognosis of the primary high / metastasis low group was poor.