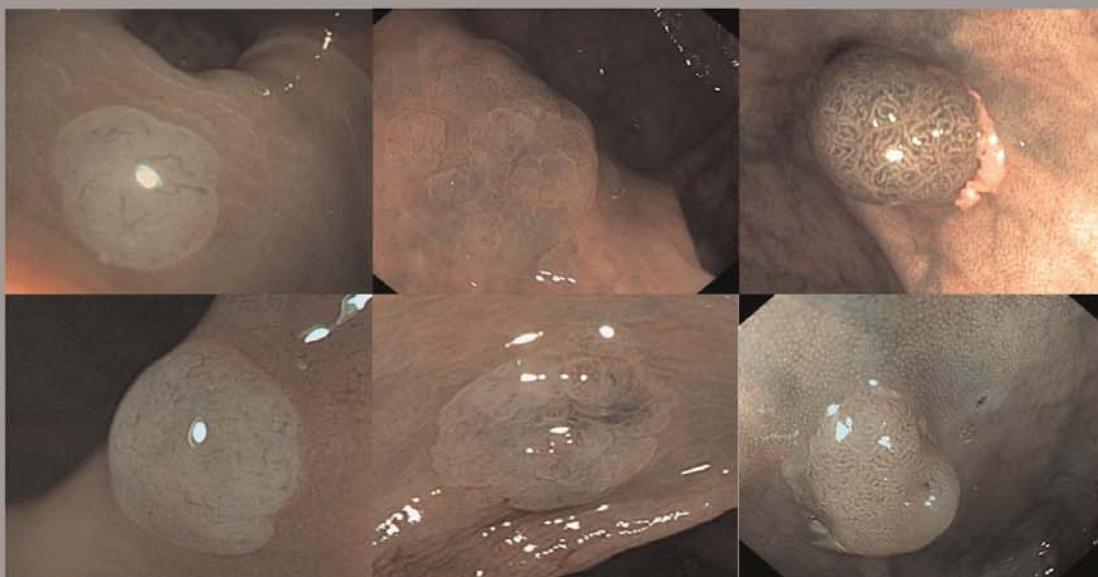
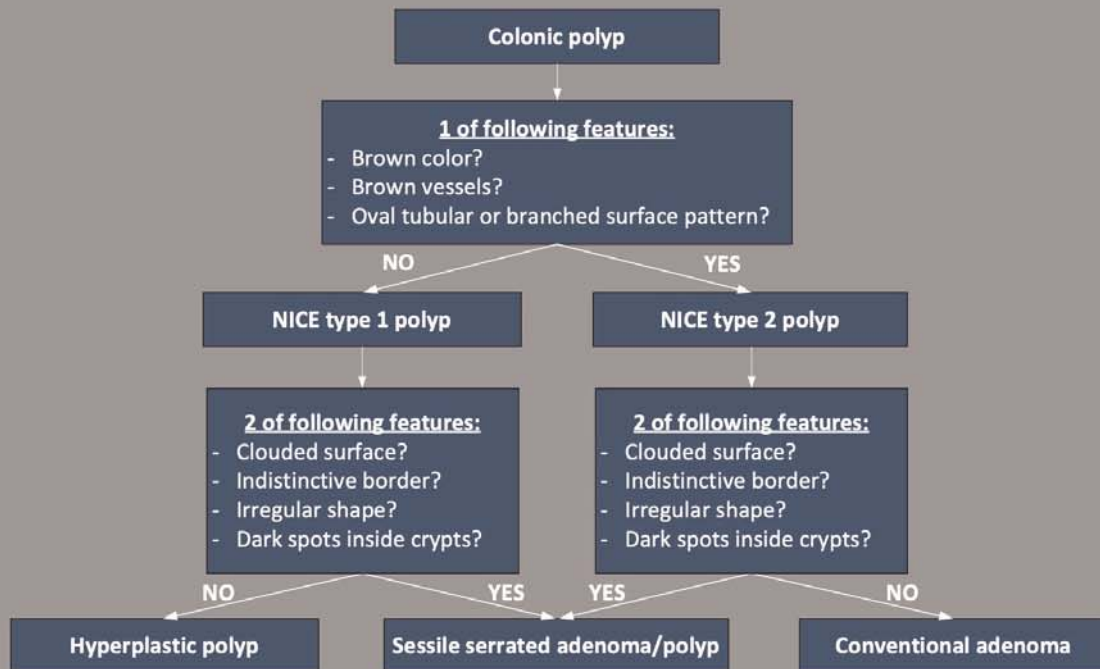


Supplementary material

The WASP-classification for differentiation of colonic polyps using Narrow Band Imaging



Designed by the Dutch workgroup serrated polyps & polyposis

Supplementary material

Supplementary Table 1 Two-by-two table for endoscopic characterization with histopathology as reference standard.

	Histopathology		
	Adenoma	SSL	HP
Endoscopic characterization all polyps, (N = 269)			
Adenoma	132	4	10
SSL	7	12	9
HP	26	11	58
Endoscopic characterization with high-confidence all polyps, (N = 223)			
Adenoma	118	2	8
SSL	7	11	8
HP	14	10	45
Endoscopic characterization diminutive polyps, (N = 220)			
Adenoma	108	1	10
SSL	3	3	6
HP	26	10	53
Endoscopic characterization diminutive polyps with high-confidence, (N = 178)			
Adenoma	94	0	8
SSL	3	3	5
HP	14	9	42

SSL, sessile serrated lesions; HP, hyperplastic polyps.