

Supplementary materials for

**Investigation of Correlations Between Optical Coherence Tomography
Biomarkers and Visual Acuity in X-Linked Retinoschisis**

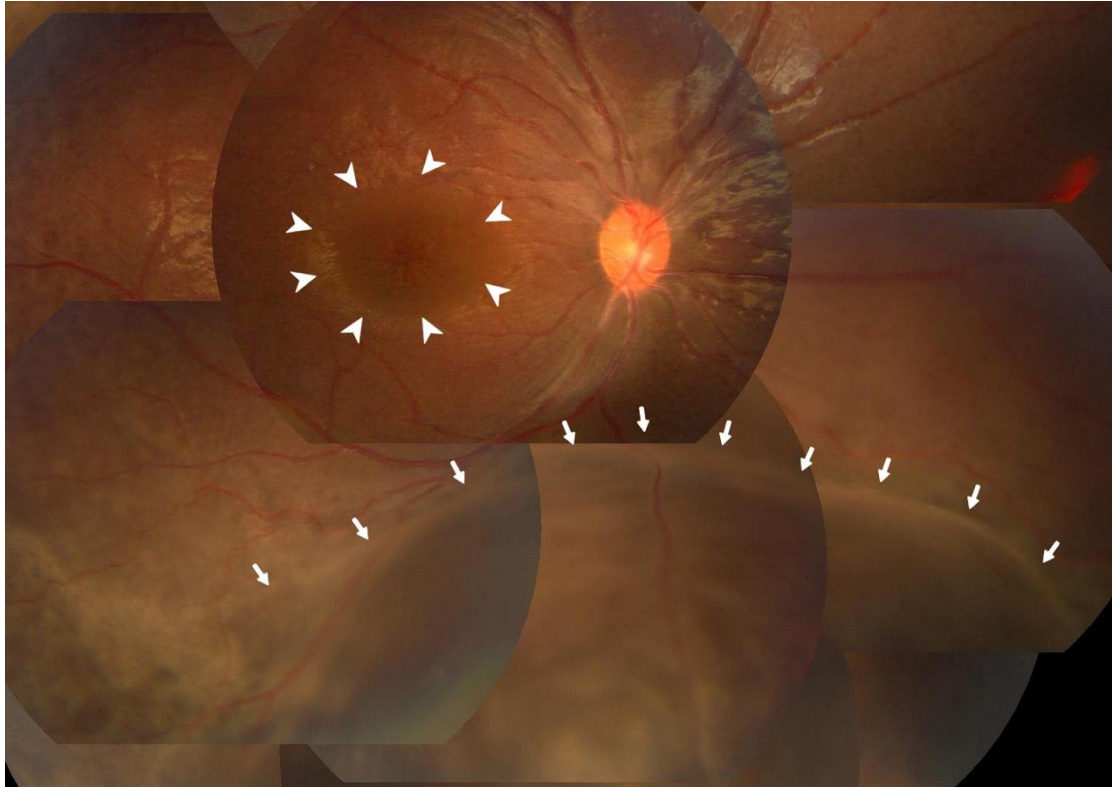


Figure S1. Fundus photograph of an XLRS patient with spoke-like macular retinoschisis (arrowheads) and peripheral retinoschisis (arrows).