

## SUPPLEMENTARY APPENDIX

### **Barotrauma in COVID-19 patients undergoing invasive mechanical ventilation: a systematic literature review**

A. Belletti, G. Todaro, G. Valsecchi, R. Losiggio, D. Palumbo, G. Landoni, A. Zangrillo

PubMed search string	page 2
Supplementary Table 1	page 3
Supplementary Table 2	page 4
Supplementary Table 3	page 5
Supplementary Table 4	page 6
Supplementary Table 5	page 7
Supplementary Table 6	page 8
Supplementary Table 7	page 9
Supplementary Figure 1	page 14
Supplementary Figure 2	page 15
Supplementary Figure 3	page 16
Supplementary Figure 4	page 17
Supplementary Figure 5	page 18
Supplementary Figure 6	page 19
Supplementary Figure 7	page 20
Supplementary Figure 8	page 21
Supplementary Figure 9	page 22
Supplementary Figure 10	page 23
Supplementary References	page 24

## **Pubmed Search String**

((Sars-cov-2) or (covid19) or (coronavirus 19)) and ((subcutaneous emphysema) or (pneumomediastinum) or (pneumothorax) or (pneumatocele) or (barotrauma))

**Supplementary Table 1.** Details of major exclusions

<b>First Author</b>	<b>Year</b>	<b>Journal</b>	<b>Reason for exclusion</b>
Gordo MLP	2020	Radiologia	No event rate
Diaz A	2020	Heart Lung	No event rate
Jia L	2020	Zhonghua Wei Zhong Bing Ji Jiu Yi Xue	No event rate
Shrift D	2020	J Ultrasound Med	No event rate
Hameed M	2020	Respir Med Case Rep	No event rate
Bellini R	2020	J Cardiothorac Surg	No event rate
Urigo C	2020	Radiol Case Rep	No event rate
Marsico S	2020	Arch Bronconeumol	No event rate
Marsico S	2020	Arch Bronconeumol	No event rate
do Lago VC	2020	Am J Med Sci	No event rate
Volpi S	2020	Eur J Cardiothorac Surg	No event rate
Gorospe L	2020	Arch Bronconeumol	No event rate
Underner M	2020	Rev Mal Respir	No event rate
Büttner R	2020	MMW Fortschr Med	No event rate
Onigbinde SO	2020	Biomed Res Int	Not COVID-19
Çinkooğlu A	2020	Diagn Interv Radiol	Not-ICU setting
Murk W	2021	CMAJ	Not ICU setting
Protti A	2021	Minerva Anesthesiol	Survey design
Yang F	2020	J Med Virol	No event rate
Wong K	2020	Cureus	No event rate
Quincho-Lopez A	2020	Am J Trop Med Hyg	Review
Long CJ	2020	BMC Med Imaging	No event rate
Jamous F	2020	S D Med	No IMV data available
Xang C	2020	Medicine	No event rate
Chen X	2020	Chin Med Sci J	Review
Yang X	2020	Lancet Respir Med	No IMV data available
Zantah M	2020	Respir Res	Not ICU setting

COVID-19: coronavirus disease 2019; ICU: intensive care unit; IMV: invasive mechanical ventilation;

**Supplementary Table 2.** Events rate and time from intubation to barotrauma development in included studies

First Author	Non-COVID ARDS control group	COVID-19 IMV patients, number	Control IMV patients, number	PNX rate, COVID-19	PNX rate, control	PMD rate, COVID-19	PMD rate, control	Barotrauma rate, combined events, COVID-19*	Barotrauma rate, combined events, control*	Time from intubation to barotrauma, mean +/- SD, days
Belletti	No	116	N/A	22 (19%)	N/A	13 (11%)	N/A	28 (24%)	N/A	14.0±11.0
Capaccione	No	132	N/A	18 (14%)	N/A	N/A	N/A	N/A	N/A	14.9±10.0
Edwards	No	137	N/A	4 (2.9%)	N/A	12 (8.8%)	N/A	13 (9%)	N/A	3.4±0.8
Fiacchini	Yes	30	45	6 (20%)	0 (0%)	10 (33%)	0 (0%)	14 (47%)	0 (0.0%)	N/A
Housman	No	171	N/A	N/A	N/A	29 (17%)	N/A	N/A	N/A	2.5±2.3
Kahn	No	39	N/A	N/A	N/A	N/A	N/A	13 (33%)	N/A	N/A
Lemmers	Yes	169	163	N/A	N/A	23 (14%)	3 (2%)	N/A	N/A	3.8±5.7
Mart	No	92	N/A	0 (0%)	N/A	5 (5.4%)	N/A	5 (5%)	N/A	9-24 <sup>†</sup>
McGuinness	Yes	601	285	54 (9%)	N/A	59 (10%)	N/A	89 (15%)	28 (10%)	N/A
Talan	No	96	N/A	6 (6%)	N/A	6 (6%)	N/A	9 (9%)	N/A	5.1±3.1
Udi	No	20	N/A	5 (25%)	N/A	5 (25%)	N/A	8 (40%)	N/A	17.3±10.8
Wang	No	9	N/A	5 (56%)	N/A	N/A	N/A	N/A	N/A	19.6±10.2
Yao	No	202	N/A	12 (6%)	N/A	N/A	N/A	N/A	N/A	N/A

\* Patients with at least one barotrauma event, after exclusion of studies reporting only one event type.

<sup>†</sup> data as range

ARDS: acute respiratory distress syndrome; COVID-19: coronavirus disease 2019; IMV: invasive mechanical ventilation; N/A: not available; PNX: pneumothorax; PMD: pneumomediastinum

**Supplementary Table 3.** Details on mortality data in included studies

First Author	Non-COVID ARDS control group	COVID-19 IMV patients, number	Control IMV patients, number	PNX mortality, COVID-19	PNX mortality, control	PMD mortality, COVID-19	PMD mortality, control	Mortality in COVID-19 patients w/o barotrauma	Mortality in control patients w/o barotrauma
Belletti	No	116	N/A	N/A	N/A	N/A	N/A	34 (39%)	N/A
Capaccione	No	132	N/A	6 (33%)	N/A	N/A	N/A	55 (48%)	N/A
Edwards	No	137	N/A	3 (75%)	N/A	N/A	N/A	N/A	N/A
Fiacchini	Yes	30	45	N/A	N/A	N/A	N/A	N/A	N/A
Housman	No	171	N/A	N/A	N/A	N/A	N/A	N/A	N/A
Kahn	No	39	N/A	N/A	N/A	N/A	N/A	N/A	N/A
Lemmers	Yes	169	163	N/A	N/A	13 (57%)	N/A	73 (50%)	N/A
Mart	No	92	N/A	N/A	N/A	N/A	N/A	N/A	N/A
McGuinness	Yes	601	285	N/A	N/A	N/A	N/A	298 (58%)	102 (40%)
Talan	No	96	N/A	N/A	N/A	N/A	N/A	N/A	N/A
Udi	No	20	N/A	N/A	N/A	N/A	N/A	N/A	N/A
Wang	No	9	N/A	4 (80%)	N/A	N/A	N/A	N/A	N/A
Yao	No	202	N/A	N/A	N/A	N/A	N/A	N/A	N/A

ARDS: acute respiratory distress syndrome; COVID-19: coronavirus disease 2019; IMV: invasive mechanical ventilation; N/A: not available; PNX: pneumothorax; PMD: pneumomediastinum; w/o: without

**Supplementary Table 4.** Details on treatment of pneumothorax/pneumomediastinum

First Author	Barotrauma rate, any event, COVID-19	PNX rate, COVID-19	PMD rate, COVID-19	COVID-19 barotrauma patients requiring chest tube drainage	COVID-19 PNX patients requiring chest tube drainage	COVID-19 PMD patients requiring chest tube drainage	COVID-19 barotrauma patients requiring surgery	COVID-19 PNX patients requiring surgery	COVID-19 PMD patients requiring surgery
Belletti	28 (24%)	22 (19%)	13 (11%)	18 (64%)	18 (81.8%)	0 (0.0%)	2 (7.1%)	1 (4.5%)	1 (7.7%)
Capaccione	18 (14%)	18 (14%)	N/A	N/A	N/A	N/A	N/A	N/A	N/A
Edwards	13 (9%)	4 (2.9%)	12 (8.8%)	6 (46%)	4 (100%)	2 (16.7%)	0 (0%)	N/A	N/A
Fiacchini	14 (47%)	6 (20%)	10 (33%)	N/A	N/A	N/A	N/A	N/A	N/A
Housman	29 (17%)	N/A	29 (17%)	5 (17%)	2*	3 (10.4%)	0 (0%)	N/A	N/A
Kahn	13 (33%)	N/A	N/A	N/A	N/A	N/A	N/A	N/A	N/A
Lemmers	23 (14%)	N/A	23 (14%)	N/A	N/A	N/A	N/A	N/A	N/A
Mart	5 (5.4%)	0 (0%)	5 (5.4%)	0 (0%)	0 (0%)	0 (0%)	0 (0%)	N/A	N/A
McGuinness	89 (15%)	54 (9%)	59 (10%)	N/A	N/A	N/A	N/A	N/A	N/A
Talan	9 (9%)	6 (6%)	6 (6%)	0 (0%)	0 (0%)	0 (0%)	0 (0%)	N/A	N/A
Udi	8 (40%)	5 (25%)	5 (25%)	5 (63%)	5 (100%)	N/A	N/A	N/A	N/A
Wang	5 (56%)	5 (56%)	N/A	2 (40%)	2 (40%)	N/A	N/A	N/A	N/A
Yao	12 (6%)	12 (6%)	N/A	N/A	N/A	N/A	N/A	N/A	N/A

\* the total number of patients with PNX was not available in the study.

ARDS: acute respiratory distress syndrome; COVID-19: coronavirus disease 2019; IMV: invasive mechanical ventilation; N/A: not available; PNX: pneumothorax; PMD: pneumomediastinum

**Supplementary Table 5.** Mechanical ventilation settings for COVID-19 ARDS patients at beginning of invasive mechanical ventilation

	TV, PBT (ml/Kg)	TV, w/o PBT (ml/Kg)	RR, PBT (Breaths /min)	RR, w/o PBT (Breaths /min)	Peak pressure, PBT (cm H2O)	Peak pressure, w/o PBT (cm H2O)	Plateau pressure, PBT (cm H2O)	Plateau pressure, w/o PBT (cm H2O)	PEEP, PBT, (cm H2O)	PEEP, w/o PBT, (cm H2O)	FiO <sub>2</sub> , PBT, (%)	FiO <sub>2</sub> , w/o PBT (%)	Prone position, PBT	Prone position w/o PBT
<b>Belletti</b>	6.8 (5.9 – 7.6) *	6.8 (6.0 – 7.4) *	N/A	N/A	28* (26 – 30)	28* (21 – 32)	N/A	N/A	11* (10 – 14)	12* (10 – 14)	N/A	N/A	N/A	N/A
<b>Capaccione</b>	N/A	N/A	24.9†	24.8†	N/A	N/A	N/A	N/A	12.1†	13.3†	90.6†	69†	N/A	N/A
<b>Edwards</b>	N/A	N/A	N/A	N/A	N/A	N/A	N/A	N/A	N/A	N/A	N/A	N/A	N/A	N/A
<b>Fiacchini</b>	N/A	N/A	N/A	N/A	N/A	N/A	N/A	N/A	12 (3)*	12 (2)*	N/A	N/A	N/A	N/A
<b>Housman</b>	N/A	N/A	N/A	N/A	N/A	N/A	N/A	N/A	N/A	N/A	N/A	N/A	N/A	N/A
<b>Kahn</b>	7.1±2.1†	8.4±2.5†	N/A	N/a	25.3±8.8 †	25.0±1.4 †	N/A	N/A	6.5±2.1†	7.0±2.4†	N/A	N/A	N/A	N/A
<b>Lemmers</b>	6.1±0.9†	5.9±0.8†	N/A	N/A	30±5†	29±5†	24±6	23±4	12 (8-15)*	12 (10-14)*	N/A	N/A	N/A	N/A
<b>Mart</b>	N/A	N/A	N/A	N/A	N/A	N/A	N/A	N/A	N/A	N/A	N/A	N/A	N/A	N/A
<b>McGuinness</b>	N/A	N/A	N/A	N/A	N/A	N/A	N/A	N/A	N/A	N/A	N/A	N/A	N/A	N/A
<b>Talan</b>	N/A	N/A	N/A	N/A	30.6±4.1	N/A	N/A	N/A	8.8±1.0	N/A	N/A	N/A	1	N/A
<b>Udi</b>	N/A	N/A	N/A	N/A	N/A	N/A	N/A	N/A	N/A	N/A	N/A	N/A	N/A	N/A
<b>Wang</b>	5.4±0.3†	N/A	N/A	N/A	21.5±3.9 †	N/A	N/A	<30	N/A	9.3±2.6†	N/A	N/A	N/A	N/A
<b>Yao</b>	N/A	N/A	N/A	N/A	N/A	N/A	N/A	N/A	N/A	N/A	N/A	N/A	N/A	N/A

\* data as median (IQR); † data as mean or mean ± standard deviation

FiO<sub>2</sub>: fraction of inspired oxygen; N/A: not available; PBT: pulmonary barotrauma; PEEP: positive end expiratory pressure; RR: respiratory rate; TV: tidal volume; w/o: without

**Supplementary Table 6.** Mechanical ventilation settings for COVID-19 ARDS patients at time of first barotrauma event

	TV, PBT (ml/Kg)	TV w/o PBT (ml/Kg)	RR, PBT (Breaths /min)	RR, w/o PBT (Breaths /min)	Peak pressure, PBT (cm H2O)	Peak pressure, w/o PBT (cm H2O)	Plateau pressure, PBT (cm H2O)	Plateau pressure, w/o PBT (cm H2O)	PEEP, PBT, (cm H2O)	PEEP, w/o PBT, (cm H2O)	FiO <sub>2</sub> , PBT, (%)	FiO <sub>2</sub> , w/o PBT (%)	Prone position, PBT	Prone position w/o PBT
<b>Belletti</b>	N/A	N/A	N/A	N/a	N/A	N/A	N/A	N/A	N/A	N/A	N/A	N/A	N/A	N/A
<b>Capaccione</b>	N/A	N/A	N/A	N/A	N/A	N/A	N/A	N/A	N/A	N/A	N/A	N/A	N/A	N/A
<b>Edwards</b>	5.5 ± 0.8*	N/A	20±5.9*	N/A	33.1±9.9 *	N/A	N/A	N/A	15.5±4.6 *	N/A	71.5±22. 3*	N/A	N/A	N/A
<b>Fiacchini</b>	N/A	N/A	N/A	N/A	N/A	N/A	N/A	N/A	N/A	N/A	N/A	N/A	N/A	N/A
<b>Housman</b>	N/A	N/A	N/A	N/A	32 (24 – 38)	N/A	N/A	N/A	13 (10- 15)	N/A	N/A	N/A	N/A	N/A
<b>Kahn</b>	6.8±1.5	7.7±2.6	N/A	N/a	29.4±7.5	35.7±9.3	N/A	N/A	12±5.5	11.8±5.5	N/A	N/A	N/A	N/A
<b>Lemmers</b>	6.7±1.7	N/A	N/A	N/A	29±5	N/A	22±4	N/A	9 (6 – 13)	N/A	N/A	N/A	N/A	N/a
<b>Mart</b>	N/A	N/A	N/A	N/A	N/A	N/A	N/A	N/A	N/A	N/A	N/A	N/A	N/A	N/A
<b>McGuinness</b>	N/A	N/A	N/A	N/A	N/A	N/A	N/A	N/A	N/A	N/A	N/A	N/A	N/A	N/A
<b>Talan</b>	N/A	N/A	N/A	N/A	N/A	N/A	N/A	N/A	N/A	N/A	N/A	N/A	1	N/A
<b>Udi</b>	5.4 (0.4 – 8.6)‡	N/A	24 (15 – 32) ‡	N/A	29 (27 – 35) ‡	N/A	27 (19 – 30) ‡	N/A	14 (5 – 24) ‡	N/A	60 (35 – 90) ‡	N/A	4	N/A
<b>Wang</b>	N/A	N/A	N/A	N/A	N/A	N/A	N/A	N/A	N/A	N/A	N/A	N/A	N/A	N/A
<b>Yao</b>	N/A	N/A	N/A	N/A	N/A	N/A	N/A	N/A	N/A	N/A	N/A	N/A	N/A	N/A

\* Data as mean ± SD; † data as mean (range); ‡ data as median (range)

FiO<sub>2</sub>: fraction of inspired oxygen; N/A: not available; PBT: pulmonary barotrauma; PEEP: positive end expiratory pressure; RR: respiratory rate; TV: tidal volume; w/o: without



**Supplementary Table 7.** Case reports details

Suppl Ref	n of patients included	Ventilation at time of event	# of survivors	Treatment for PNx/PMD	Time from intubation to PNx/PMD
1	1	NIV	1	chest tube drainage	not reported
2	1	IMV	1	conservative	not reported
3	1	HFNC	1	conservative	not reported
4	1	NIV	0	conservative	not reported
5	1	NIV	1	chest tube drainage	not reported
6	5	IMV	3	chest tube drainage (4) conservative (1)	4 hours (1) 2 days (2) 5 days (1) 6 days (1) 14 days (1)
7	1	spontaneous breathing	1	conservative	not reported
8	1	spontaneous breathing	1	conservative	not reported
9	1	spontaneous breathing	1	conservative	not reported
10	1	spontaneous breathing	1	conservative	not reported
11	1 (barotrauma)	CPAP	1	conservative	not reported
12	1	IMV	1	chest tube drainage	not reported
13	1	IMV	not reported	not reported	present before the intubation
14	1	spontaneous breathing	1	chest tube drainage	not reported
15	2	spontaneous breathing	2	conservative	not reported
16	1	IMV	1	chest tube drainage	not reported
17	2	IMV	not reported	chest tube drainage	caused by the intubation
18	1	NIV	1	conservative	not reported
19	11	IMV (7); NIV (4)	7	not reported	not reported
20	1	spontaneous breathing	1	conservative	not reported
21	2	IMV	0	conservative	present before the intubation
22	1	IMV	0	chest tube drainage	5 days
23	1	oxygen therapy	1	conservative	not reported
24	75	NIV (69)	4 (C); 19 (I)	chest tube drainage (64)	conservative (4.4 days) invasive (8.2 days)

25	3	NIV (2); CPAP (1)	0	conservative (2) - pleural drainage (1)	not reported
26	1	IMV	1	conservative	14 days
27	1	oxygen therapy	1	chest tube drainage	not reported
28	3	NIV	2	conservative (2); chest tube drainage (1)	not reported
29	1	NIV	1	chest tube drainage	not reported
30	2	IMV	2	chest tube drainage	5 days (1); 2 days (1)
31	10	NIV (7); IMV (3)	4 (NIV); 3 (IMV)	chest tube drainage (5); conservative (5)	on average. 5,5 days
32	1	NIV	1	conservative	not reported
33	1	spontaneous breathing	1	chest tube drainage	not reported
34	1	NIV	1	conservative	not reported
35	1	spontaneous breathing	1	conservative	not reported
36	1	oxygen therapy	1	decompression; then, chest tube drainage	not reported
37	7	IMV (5); NIV (2)	6	conservative (4); chest tube drainage (3)	present before the intubation (5)
38	1	NIV	1	conservative	not reported
39	1	NIV	0	conservative	not reported
40	1	spontaneous breathing	1	chest tube drainage	not reported
41	1	spontaneous breathing	1	chest tube drainage	not reported
42	1	spontaneous breathing	1	chest tube drainage	not reported
43	3	oxygen therapy	3	chest tube drainage (2); conservative (1)	not reported
44	1	NIV	1	chest tube drainage	not reported
45	1	spontaneous breathing	1	conservative	not reported
46	1	spontaneous breathing	1	chest tube drainage	not reported
47	1	NIV	0	conservative	not reported
48	3	IMV (1); HFNC (1)	1	chest tube drainage (2); conservative (1)	4 days (1); 3 days (1); 9 days (1)
49	1	IMV	1	chest tube drainage	not reported
50	3	NIV	3	conservative	not reported
51	3	NIV (2); oxygen therapy (1)	1	conservative (3)	not reported

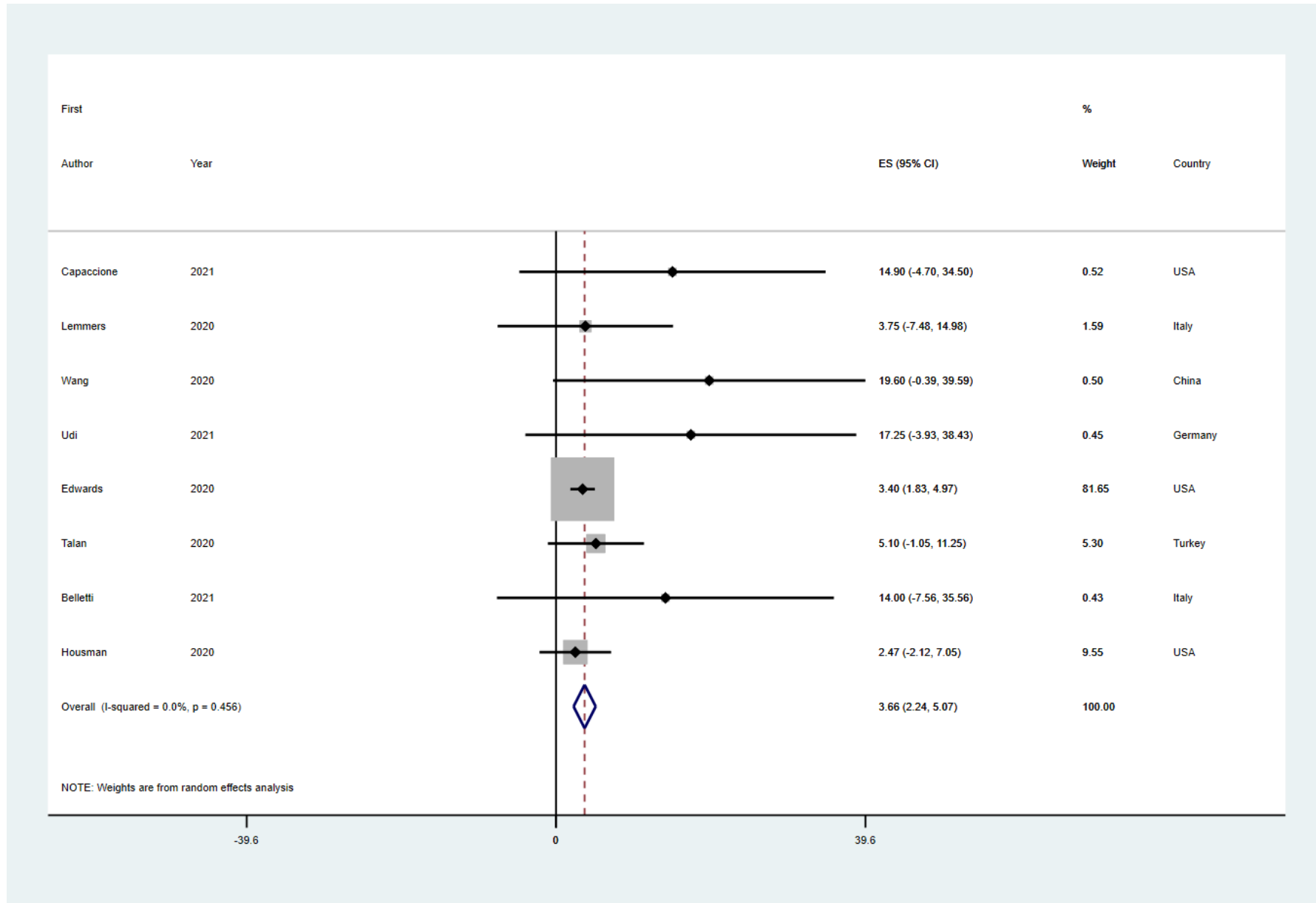
52	1	IMV	1	decompression; then, chest tube drainage	not reported
53	1	NIV	1	conservative	not reported
54	9	IMV	6	chest tube drainage (8); conservative (1)	5 days (1); 4 days (1); 1 day (2); 34 days (1); 2 days (1); 47 days (1); 16 days (1)
55	1	IMV	1	chest tube drainage	19 days
56	1	IMV	1	chest tube drainage	not reported
57	1	IMV	1	chest tube drainage	30 days
58	1	IMV	0	chest tube drainage	2 days
59	1	IMV	0	chest tube drainage	1 day
60	2	NIV	2	conservative	not reported
61	1	IMV	1	chest tube drainage	14 days
62	1	IMV	1	chest tube drainage	3 days
63	1	IMV	1	chest tube drainage	7 days
64	2	IMV	2	chest tube drainage	not reported
65	1	CPAP	1	chest tube drainage	not reported
66	1	IMV	1	conservative	12 days
67	1	spontaneous breathing	1	conservative	not reported
68	3	spontaneous breathing	3	chest tube drainage (2); thoracic surgery (1)	not reported
69	11 (6 only with hydrothorax; 5 also with PNX)	IMV	3 (only hydrothorax)	chest tube drainage	not reported
70	4	IMV	3	chest tube drainage	not reported
71	1	NIV	1	conservative	not reported
72	1	IMV	1	conservative	0 days
73	5	IMV	2	chest tube drainage	from 1 to 12 days
74	1	IMV	0	conservative	17 days
75	1	IMV	0	conservative	not reported
76	1	IMV	1	chest tube drainage	2 days

77	2	IMV	2	chest tube drainage, then blebs resection and pleurectomy	0 days
78	1	IMV	1	chest tube drainage	47 days
79	1	spontaneous breathing	1	chest tube drainage	not reported
80	2	NIV (1); oxygen therapy (1)	2	conservative (1); chest tube drainage (1)	not reported
81	1	IMV	1	chest tube drainage	3 days
82	2	IMV	2	decompression (1); decompression, then chest tube drainage (1)	5 days (1); 2 days (1)
83	1	IMV	1	chest tube drainage	not reported
84	1	IMV	1	chest tube drainage	not reported
85	4	IMV	2	conservative	4 days (1); not reported (1); 31 days (1); 1 day
86	1	IMV	1	chest tube drainage	26 days
87	1	IMV	1	chest tube drainage	21 days
88	1	IMV	1	conservative, then chest tube drainage	not reported
89	1	IMV	1	emergency compression + chest tube drainage	28 days
90	1	IMV	1	surgery	10 days
91	6	NIV	5	chest tube drainage	not reported
92	1	spontaneous breathing	1	chest tube drainage	not reported
93	2	CPAP	2	Needle thoracentesis followed by chest tube drainage	not reported
94	1	spontaneous breathing	1	conservative	not reported
95	1	IMV	1	chest tube drainage	30 days
96	1	not reported	1	chest tube drainage	not reported
97	1	IMV	1	chest tube drainage	10 days
98	1	NIV	1	chest tube drainage	not reported
99	1	IMV	1	chest tube drainage	not reported
100	1	IMV	1	chest tube drainage	16 days
101	1	NIV	0	chest tube drainage	present before the intubation
102	2 (only 1 with PNX)	IMV (1)	2	chest tube drainage (1)	5 days

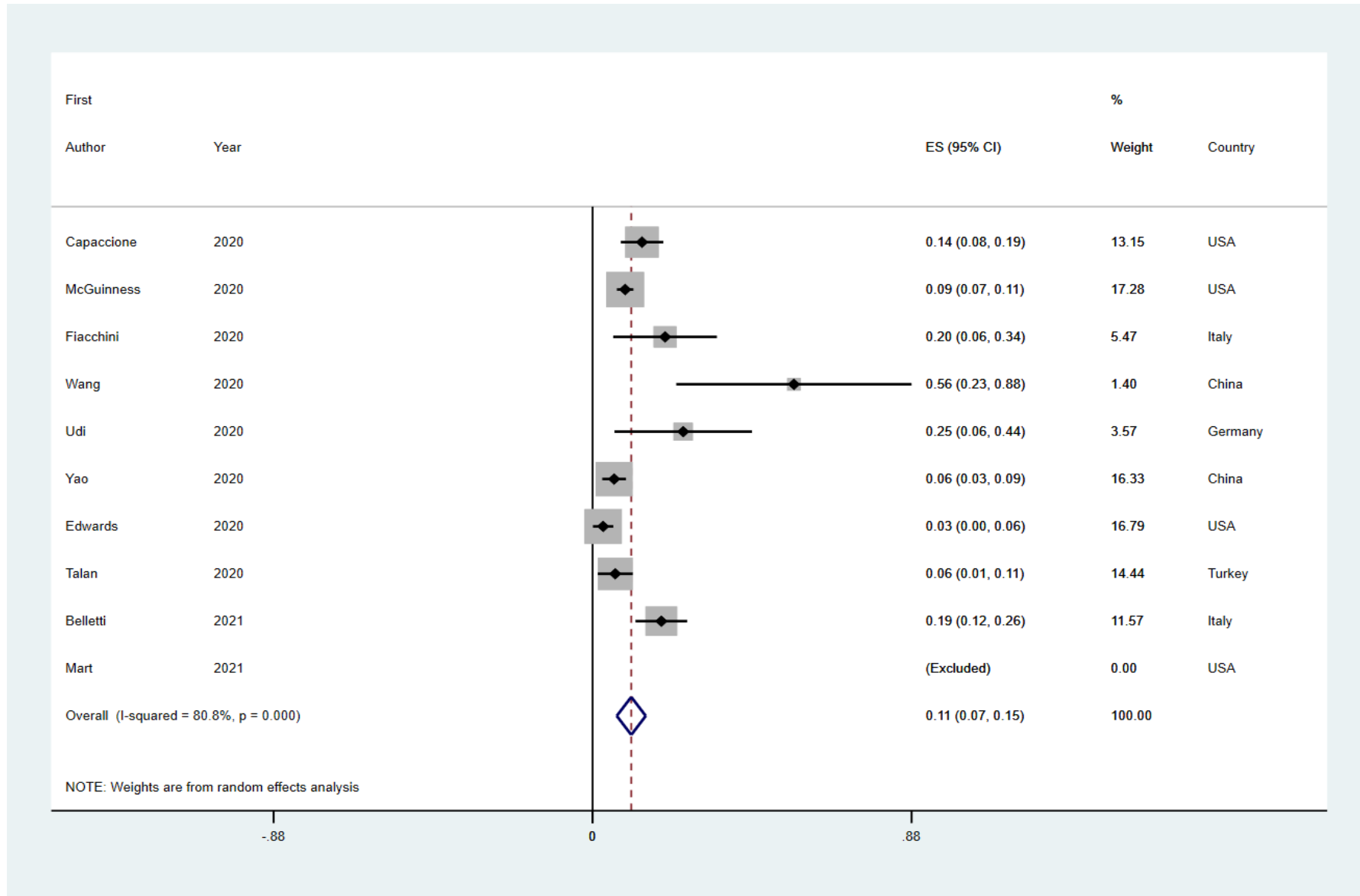
103	1	IMV	1	chest tube drainage	5 days
104	1	HFNC	1	conservative	not reported
105	1	HFNC	1	chest tube drainage	not reported
106	1	IMV	1	chest tube drainage	4 weeks
107	2	HFNC (1); IMV (1)	not reported	not reported	not reported

CPAP: continuous positive airway pressure; HFNC: high-flow nasal cannula; IMV: invasive mechanical ventilation; NIV: non-invasive ventilation; PMD: pneumomediastinum; PNX: pneumothorax

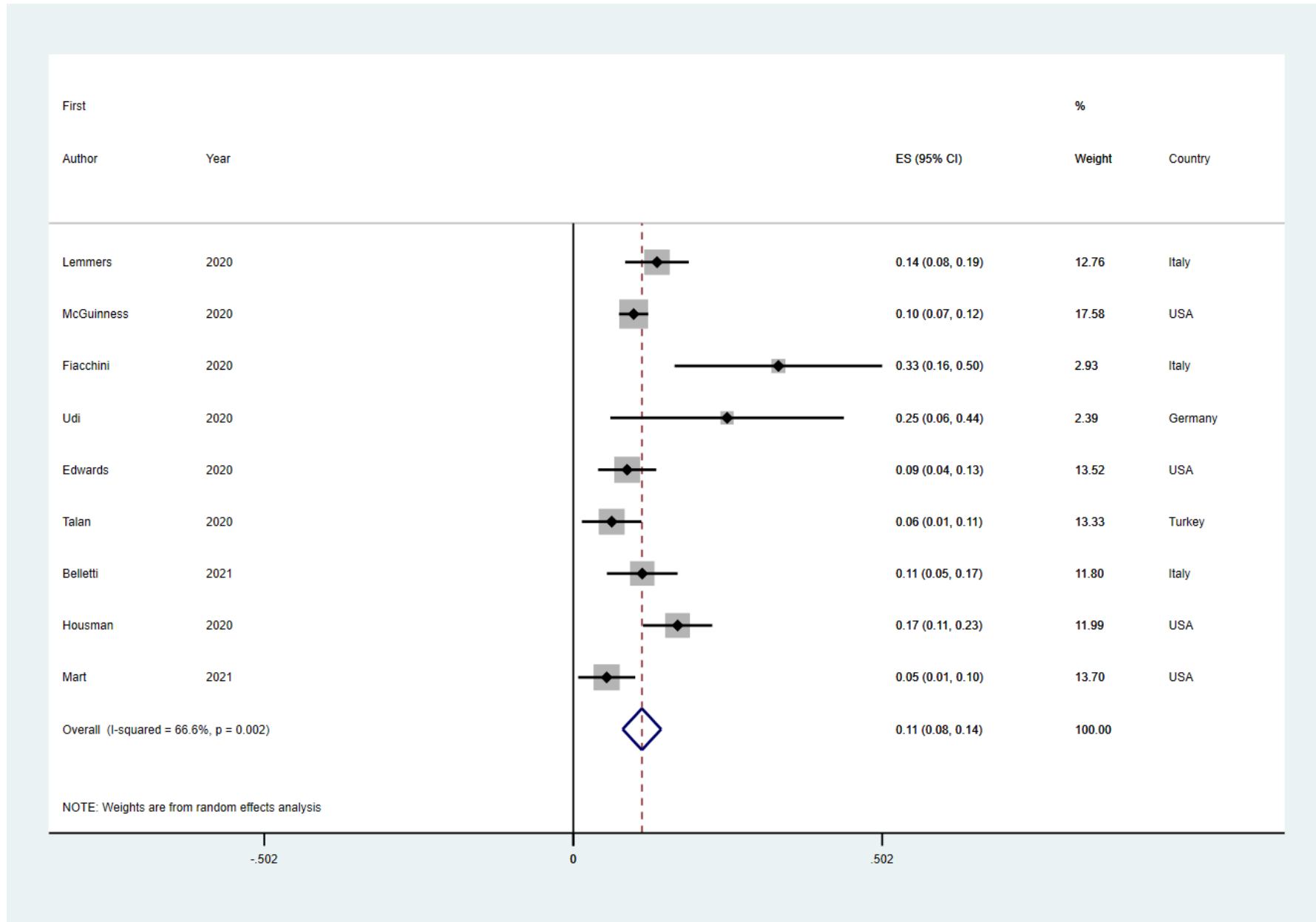
**Supplementary Figure 1.** Forest plot for time from intubation to first barotrauma event



**Supplementary Figure 2.** Forest plot for pneumothorax rate in COVID-19 ARDS patients

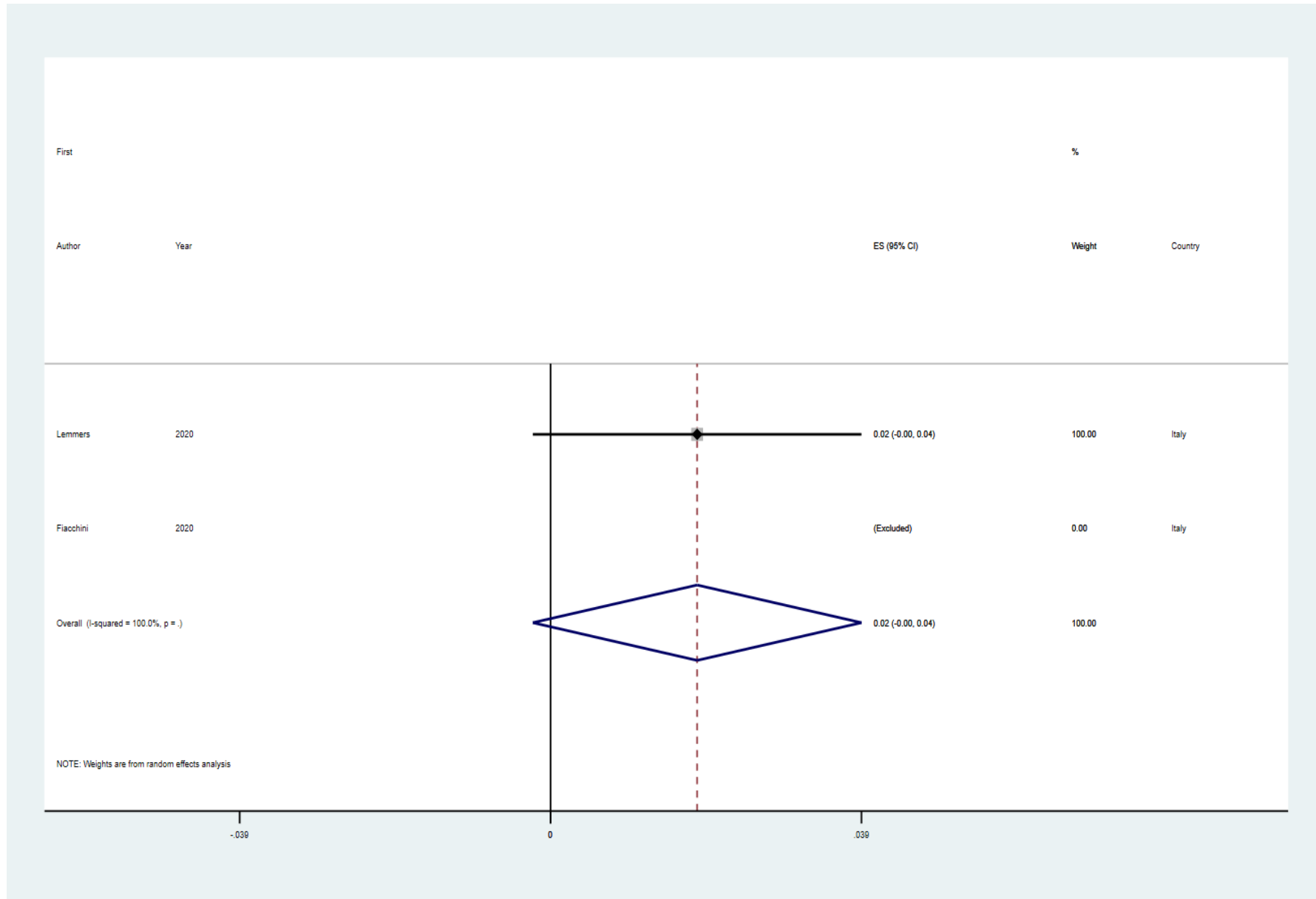


**Supplementary Figure 3.** Forest plot for pneumomediastinum rate in COVID-19 ARDS patients

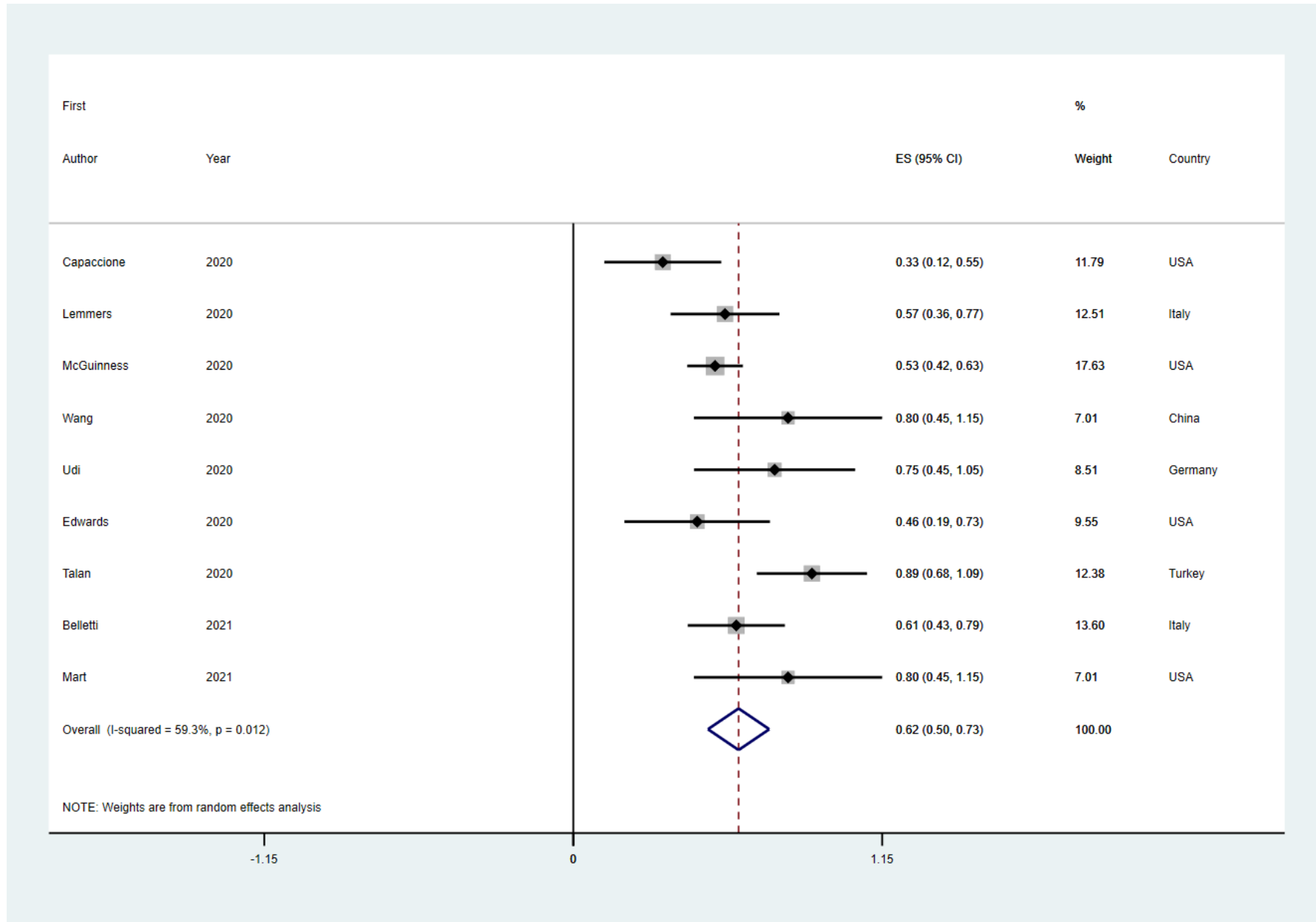




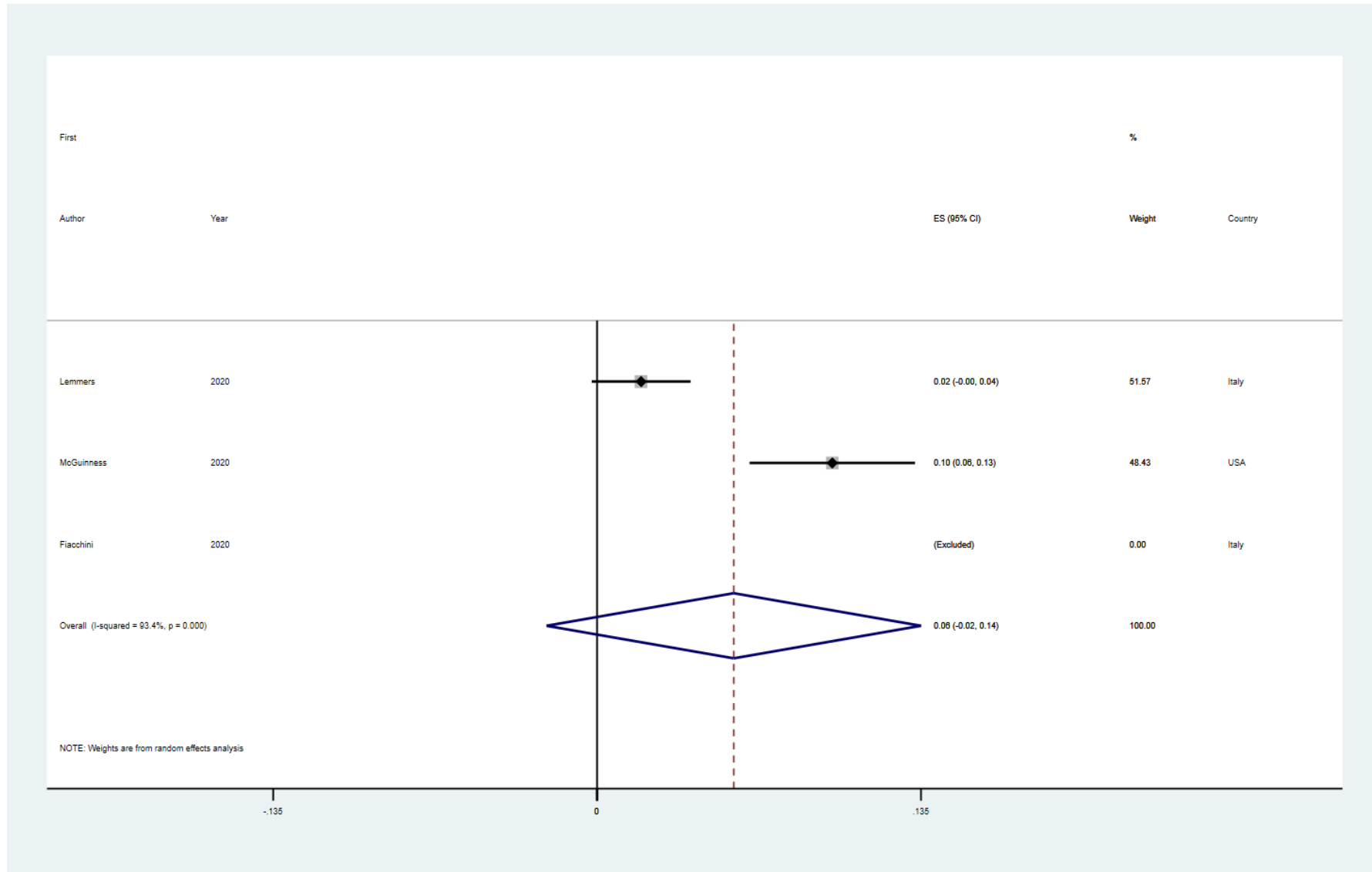
**Supplementary Figure 4.** Forest plot for pneumomediastinum rate in non-COVID-19 ARDS patients



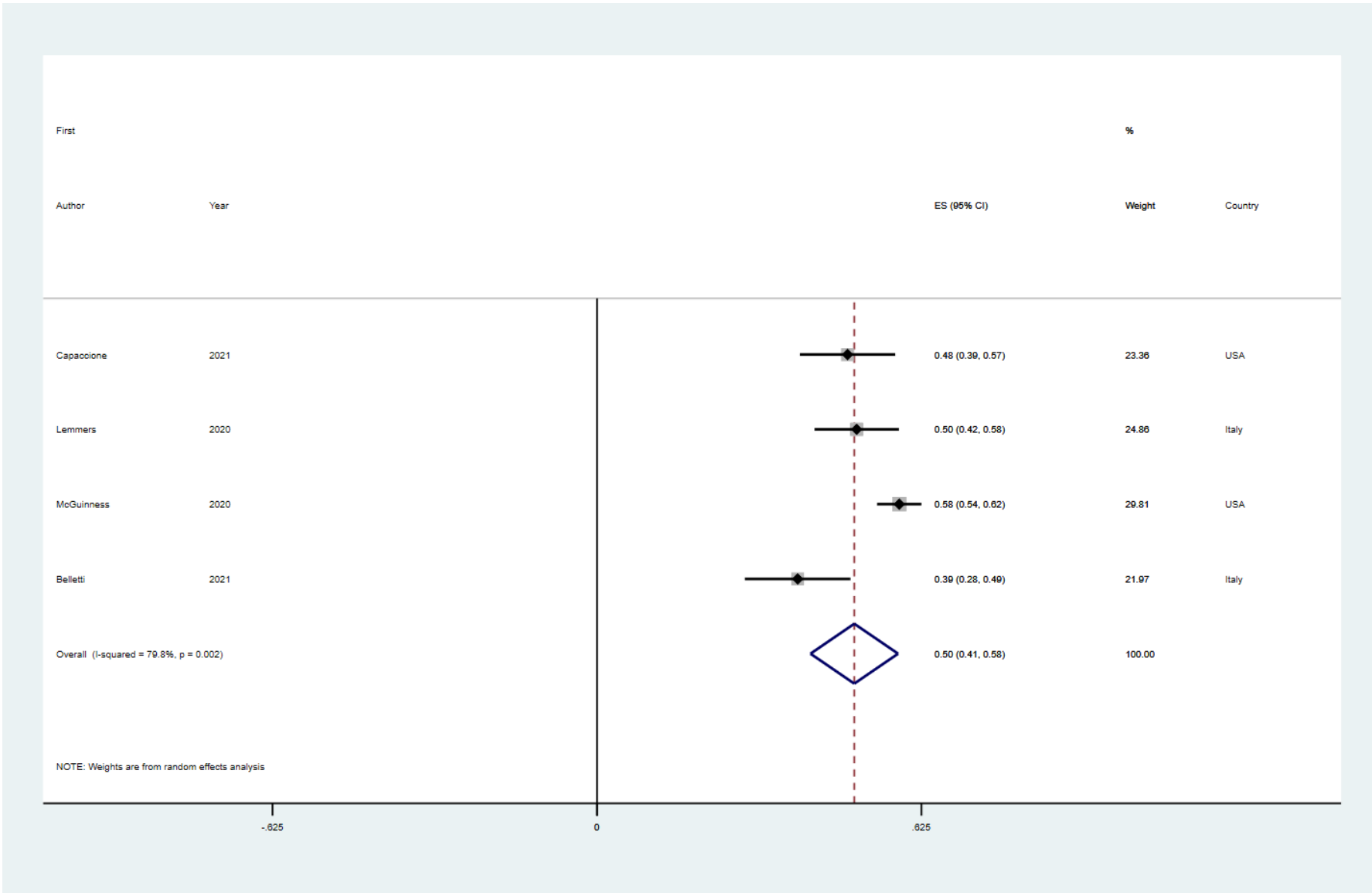
**Supplementary Figure 5.** Forest plot for mortality rate in COVID-19 ARDS patients with barotrauma events



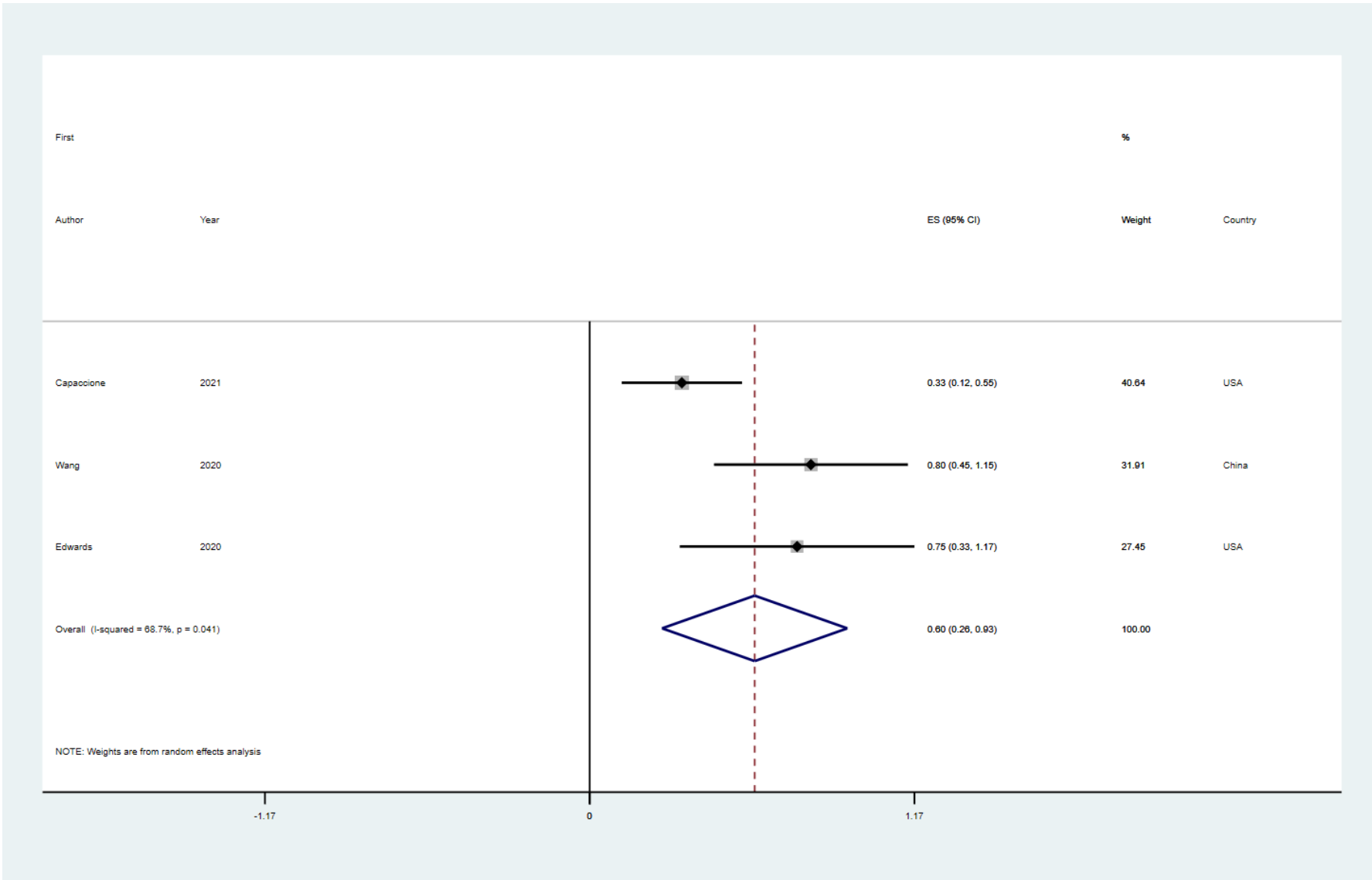
**Supplementary Figure 6.** Forest plot for barotrauma rate in non-COVID-19 ARDS patients



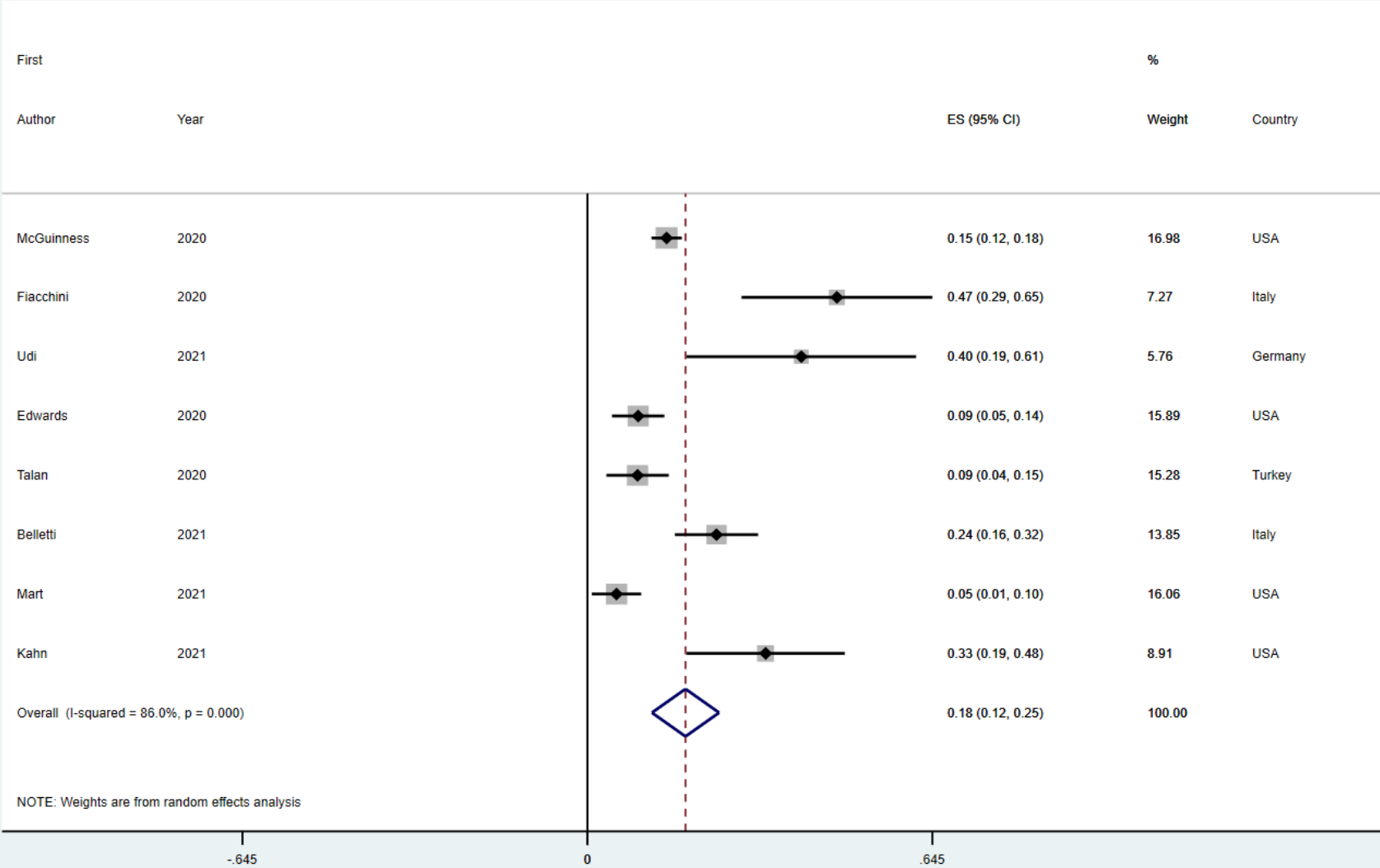
**Supplementary Figure 7.** Forest plot for mortality rate in COVID-19 ARDS patients without barotrauma



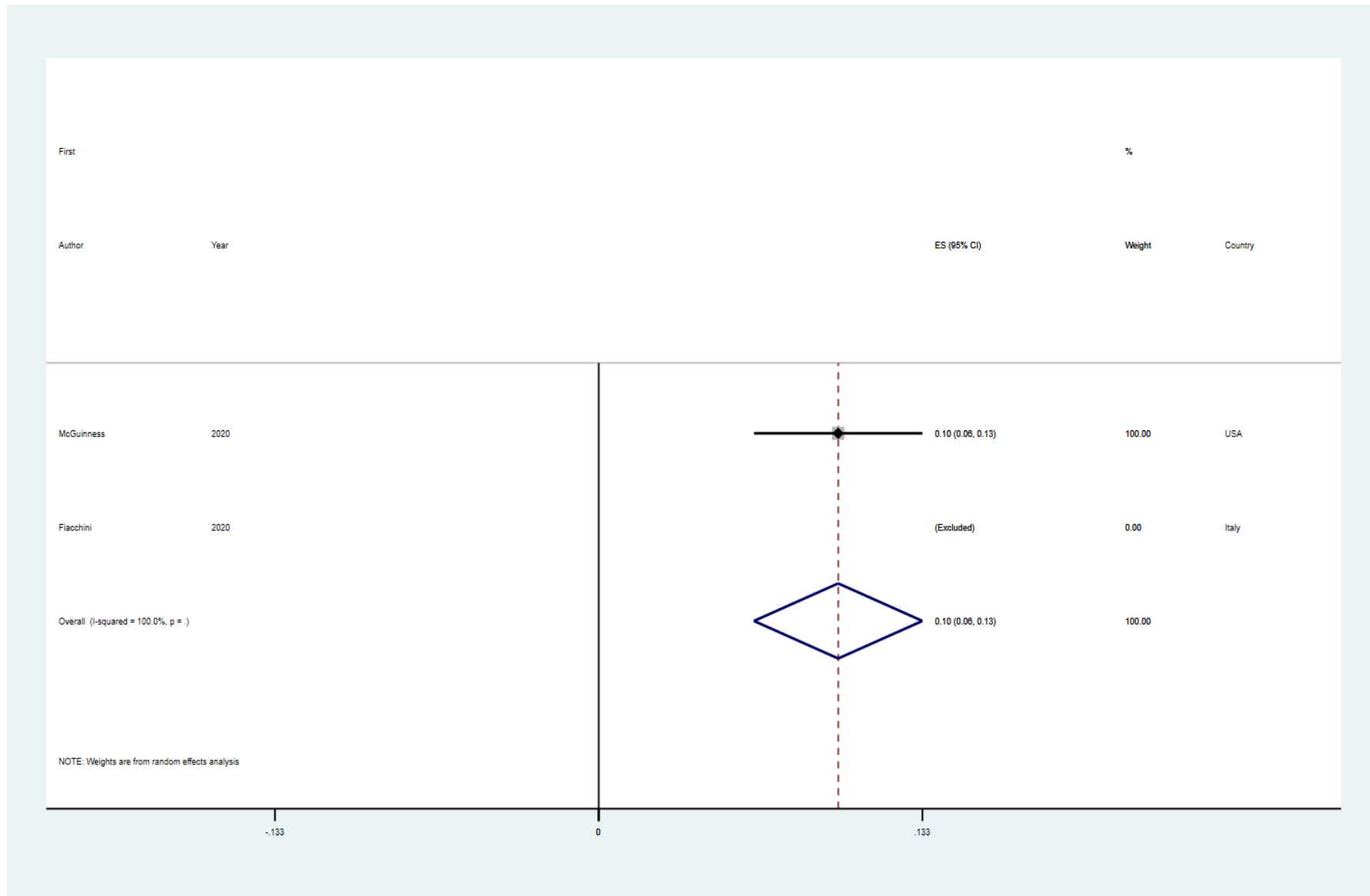
**Supplementary Figure 8.** Forest plot for mortality rate in COVID-19 ARDS patients with pneumothorax.



**Supplementary Figure 9.** Forest plot for barotrauma rate in COVID-19 ARDS patients, after excluding studies reporting only one type of barotrauma event



**Supplementary Figure 10.** Forest plot for barotrauma rate in non-COVID-19 ARDS patients, after excluding studies reporting only one type of barotrauma event



## Supplementary references

1. Ucpinar, B. A., Sahin, C., & Yanc, U. (2020). Spontaneous pneumothorax and subcutaneous emphysema in COVID-19 patient: Case report. *Journal of Infection and Public Health*, *13*(6), 887–889. <https://doi.org/10.1016/j.jiph.2020.05.012>
2. Sanivarapu, R. R., Farraj, K., Sayedy, N., & Anjum, F. (2020). Rapidly developing large pneumatocele and spontaneous pneumothorax in SARS-CoV-2 infection. *Respiratory Medicine Case Reports*, *31*, 101303. <https://doi.org/10.1016/j.rmcr.2020.101303>
3. Sun, R., Liu, H., & Wang, X. (2020). Mediastinal emphysema, giant bulla, and pneumothorax developed during the course of COVID-19 Pneumonia. *Korean Journal of Radiology*, *21*(5), 541–544. <https://doi.org/10.3348/kjr.2020.0180>
4. Wang, J., Su, X., Zhang, T., & Zheng, C. (2020). Spontaneous pneumomediastinum: A probable unusual complication of Coronavirus disease 2019 (COVID-19) pneumonia. *Korean Journal of Radiology*, *21*(5), 627–628. <https://doi.org/10.3348/kjr.2020.0281>
5. Campisi, A., Poletti, V., Ciarrocchi, A. P., Salvi, M., & Stella, F. (2020). Tension pneumomediastinum in patients with COVID-19. *Thorax*, *75*(12), 1130–1131. <https://doi.org/10.1136/thoraxjnl-2020-215012>
6. Wali, A., Rizzo, V., Bille, A., Routledge, T., & Chambers, A. J. (2020). Pneumomediastinum following intubation in COVID-19 patients: a case series. *Anaesthesia*, *75*(8), 1076–1081. <https://doi.org/10.1111/anae.15113>
7. Mimouni, H., Diyas, S., Ouachaou, J., Laaribi, I., Oujidi, Y., Merbouh, M., ... Housni, B. (2020). Spontaneous pneumomediastinum associated with covid-19 pneumonia. *Case Reports in Medicine*, *2020*, 17–19. <https://doi.org/10.1155/2020/4969486>
8. Goldman, N., Ketheeswaran, B., & Wilson, H. (2020). COVID-19-associated pneumomediastinum. *Clinical Medicine, Journal of the Royal College of Physicians of London*, *20*(4), 91–92. <https://doi.org/10.7861/CLINMED.2020-0247>
9. Mohan, V., & Tauseen, R. A. (2020). Spontaneous pneumomediastinum in COVID-19. *BMJ Case Reports*, *13*(5), 1–2. <https://doi.org/10.1136/bcr-2020-236519>
10. Menter, T., Haslbauer, J. D., Nienhold, R., Savic, S., Hopfer, H., Deigendes, N., ... Tzankov, A. (2020). Postmortem examination of COVID-19 patients reveals diffuse alveolar damage with severe capillary congestion and variegated findings in lungs and other organs suggesting vascular dysfunction. *Histopathology*, *77*(2), 198–209. <https://doi.org/10.1111/his.14134>
11. Berhane, S., Tabor, A., Sahu, A., & Singh, A. (2020). Development of bullous lung disease in a patient with severe COVID-19 pneumonitis. *BMJ Case Reports*, *13*(10), 2–5. <https://doi.org/10.1136/bcr-2020-237455>
12. Balasopoulou, A., Kokkinos, P., Pagoulatos, D., Plotas, P., Makri, O. E., Georgakopoulos, C. D., ... Loukovaara, S. (2017). Symposium Recent advances and challenges in the management of retinoblastoma Globe - saving Treatments. *BMC Ophthalmology*, *17*(1), 1. <https://doi.org/10.4103/ijo.IJO>
13. Lacroix, M., Graïess, F., Monnier-Cholley, L., & Arrivé, L. (2020). SARS-CoV-2 pulmonary infection revealed by subcutaneous emphysema and pneumomediastinum. *Intensive Care Medicine*, *46*(8), 1620–1621. <https://doi.org/10.1007/s00134-020-06078-3>
14. Marza, A. M., Petrica, A., Buleu, F. N., & Mederle, O. A. (2021). Case report: Massive spontaneous pneumothorax—a rare form of presentation for severe COVID-19 pneumonia. *Medicina (Lithuania)*, *57*(2), 1–6. <https://doi.org/10.3390/medicina57020082>
15. Romano, N., Fischetti, A., & Melani, E. F. (2020). Pneumomediastinum Related to Covid-19 Pneumonia. *Journal of Cleaner Production*, *360*(6), e19–e20. <https://doi.org/10.1016/j.amjms.2020.06.003>



16. Castiglioni, M., Pelosi, G., Meroni, A., Tagliabue, M., Uslenghi, E., Salaris, D., & Incarbone, M. (2021). Surgical Resections of Superinfected Pneumatoceles in a COVID-19 Patient. *Annals of Thoracic Surgery*, *111*(1), e23–e25. <https://doi.org/10.1016/j.athoracsur.2020.06.008>
17. Abou-Arab, O., Huette, P., Berna, P., & Mahjoub, Y. (2020). Tracheal trauma after difficult airway management in morbidly obese patients with COVID-19. *British Journal of Anaesthesia*, *125*(1), e168–e170. <https://doi.org/10.1016/j.bja.2020.04.004>
18. Janssen, J., Kamps, M. J. A., Joosten, T. M. B., & Barten, D. G. (2021). Spontaneous pneumomediastinum in a male adult with COVID-19 pneumonia. *American Journal of Emergency Medicine*, *40*, 228.e3–228.e5. <https://doi.org/10.1016/j.ajem.2020.07.066>
19. Manna, S., Maron, S. Z., Cedillo, M. A., Voutsinas, N., Toussie, D., Finkelstein, M., ... Jacobi, A. (2020). Spontaneous subcutaneous emphysema and pneumomediastinum in non-intubated patients with COVID-19. *Clinical Imaging*, *67*(June), 207–213. <https://doi.org/10.1016/j.clinimag.2020.08.013>
20. Zhou, C., Gao, C., Xie, Y., & Xu, M. (2020). COVID-19 with spontaneous pneumomediastinum. *The Lancet Infectious Diseases*, *20*(4), 510. [https://doi.org/10.1016/S1473-3099\(20\)30156-0](https://doi.org/10.1016/S1473-3099(20)30156-0)
21. Shan, S., Guangming, L., Wei, L., & Xuedong, Y. (2020). Spontaneous pneumomediastinum, pneumothorax and subcutaneous emphysema in COVID-19: Case report and literature review. *Revista Do Instituto de Medicina Tropical de Sao Paulo*, *62*, 1–5. <https://doi.org/10.1590/S1678-9946202062076>
22. Xiang, C., Wu, G., & Saranathan., M. (2020). SARS-CoV-2 pneumonia with subcutaneous emphysema, mediastinal emphysema, and pneumothorax: A case report. *Medicine (United States)*, *99*(20), 9–11. <https://doi.org/10.1097/MD.00000000000020208>
23. Wang, W., Gao, R., Zheng, Y., & Jiang, L. (2020). COVID-19 with spontaneous pneumothorax, pneumomediastinum and subcutaneous emphysema. *Journal of Travel Medicine*, *27*(5), 1–2. <https://doi.org/10.1093/jtm/taaa062>
24. Wong, K., Kim, D. H., Iakovou, A., Khanijo, S., Tsegaye, A., Hahn, S., ... Zaidi, G. (2020). Pneumothorax in COVID-19 Acute Respiratory Distress Syndrome: Case Series. *Cureus*, *12*(11), 3–9. <https://doi.org/10.7759/cureus.11749>
25. López Vega, J. M., Parra Gordo, M. L., Diez Tascón, A., & Ossaba Vélez, S. (2020). Pneumomediastinum and spontaneous pneumothorax as an extrapulmonary complication of COVID-19 disease. *Emergency Radiology*, *27*(6), 727–730. <https://doi.org/10.1007/s10140-020-01806-0>
26. Li, S., Chau, E., Ghasem, W., Sohn, J., & Yaghmour, B. (2020). Air Should Not be There: A Case of Pneumomediastinum and Pneumopericardium in COVID-19. *Cureus*, *12*(11). <https://doi.org/10.7759/cureus.11696>
27. Zayet, S., Klopfenstein, T., Mezher, C., Gendrin, V., Conrozier, T., & Ben Abdallah, Y. (2020). Coronavirus disease 2019 with spontaneous pneumothorax, pneumomediastinum and subcutaneous emphysema, France. *New Microbes and New Infections*, *38*, 100785. <https://doi.org/10.1016/j.nmni.2020.100785>
28. Mallick, T., Dinesh, A., Engdahl, R., & Sabado, M. (2020). COVID-19 Complicated by Spontaneous Pneumothorax. *Cureus*, *12*(7), 1–6. <https://doi.org/10.7759/cureus.9104>
29. Salah, O., Faisal, M., Alshahwani, I., & Elhiday, A. (2020). Bilateral Hemopneumothorax in COVID-19. *Cureus*, *12*(9), 1–10. <https://doi.org/10.7759/cureus.10314>
30. Aiolfi, A., Biraghi, T., Montisci, A., Bonitta, G., Micheletto, G., Donatelli, F., ... Bona, D. (2020). Management of Persistent Pneumothorax With Thoracoscopy and Bleb Resection in COVID-19 Patients. *Annals of Thoracic Surgery*, *110*(5), e413–e415. <https://doi.org/10.1016/j.athoracsur.2020.04.011>

31. Sethi, S. M., Sabeen Ahmed, A., Hanif, S., Aqeel, M., & Zubairi, A. B. S. (2021). Subcutaneous Emphysema and Pneumomediastinum in patients with CoVID-19 disease; Case series from a tertiary care hospital in Pakistan. *Epidemiology and Infection*, (June 2020). <https://doi.org/10.1017/S095026882100011X>
32. Borghesi, A., Aggiusti, C., Farina, D., Maroldi, R., & Muiesan, M. L. (2020). COVID-19 pneumonia: Three thoracic complications in the same patient. *Diagnostics*, *10*(7), 2–6. <https://doi.org/10.3390/diagnostics10070498>
33. Nunna, K., & Braun, A. B. (2021). Development of a large spontaneous pneumothorax after recovery from mild COVID-19 infection. *BMJ Case Reports*, *14*(1). <https://doi.org/10.1136/bcr-2020-238863>
34. Ramezani, R., Jafari, F., Fahami, Y., Pakniyat, A., & Rad, M. G. (2021). A case report of pneumomediastinum and subcutaneous emphysema associated with pandemic COVID-19 in a 43-year-old man. *Clinical Imaging*, *76*(January), 74–76. <https://doi.org/10.1016/j.clinimag.2021.01.009>
35. Kolani, S., Houari, N., Haloua, M., Alaoui Lamrani, Y., Boubbou, M., Serraj, M., ... Alami, B. (2020). Spontaneous pneumomediastinum occurring in the SARS-COV-2 infection. *IDCases*, *21*, 4–7. <https://doi.org/10.1016/j.idcr.2020.e00806>
36. Flower, L., Carter, J. P. L., Rosales Lopez, J., & Henry, A. M. (2020). Tension pneumothorax in a patient with COVID-19. *BMJ Case Reports*, *13*(5), 1–4. <https://doi.org/10.1136/bcr-2020-235861>
37. Eperjesiova, B., Hart, E., Shokr, M., Sinha, P., & Ferguson, G. T. (2020). Spontaneous Pneumomediastinum/Pneumothorax in Patients With COVID-19. *Cureus*, *12*(7), 10–13. <https://doi.org/10.7759/cureus.8996>
38. Ruggeri, P., & Girbino, G. (2014). Fatal pneumomediastinum associated with use of noninvasive mechanical ventilation. *Respirology Case Reports*, *2*(4), 126–128. <https://doi.org/10.1002/rcr2.73>
39. Gillespie, M., Dincher, N., Fazio, P., Okorji, O., Finkle, J., & Can, A. (2020). Coronavirus disease 2019 (COVID-19) complicated by Spontaneous Pneumomediastinum and Pneumothorax. *Respiratory Medicine Case Reports*, *31*, 101232. <https://doi.org/10.1016/j.rmcr.2020.101232>
40. Rohailla, S., Ahmed, N., & Gough, K. (2020). SARS-CoV-2 infection associated with spontaneous pneumothorax. *Cmaj*, *192*(19), E510. <https://doi.org/10.1503/cmaj.200609>
41. Kim, W., & Kim, W. (2020). *v o i s r n o l a v o i s n o l a v o i n*, *52*(4), 4–7.
42. Shirai, T., Mitsumura, T., Aoyagi, K., Okamoto, T., Kimura, M., Gemma, T., ... Miyazaki, Y. (2020). COVID-19 pneumonia complicated by bilateral pneumothorax: A case report. *Respiratory Medicine Case Reports*, *31*, 101230. <https://doi.org/10.1016/j.rmcr.2020.101230>
43. Hameed, M., Jamal, W., Yousaf, M., Thomas, M., Haq, I. U., Ahmed, S., ... Khatib, M. (2020). Pneumothorax In Covid-19 Pneumonia: A case series. *Respiratory Medicine Case Reports*, *31*(October), 101265. <https://doi.org/10.1016/j.rmcr.2020.101265>
44. Spiro, J. E., Sisovic, S., Ockert, B., Böcker, W., & Siebenbürger, G. (2020). Secondary tension pneumothorax in a COVID-19 pneumonia patient: a case report. *Infection*, *48*(6), 941–944. <https://doi.org/10.1007/s15010-020-01457-w>
45. Gurkan, O., Yilmaz, A., Cengel, F., Altunok, E. S., & Ekin, E. E. (2020). COVID-19 pulmonary infection with pneumothorax in a young patient. *Journal of the College of Physicians and Surgeons Pakistan*, *30*(1), S43–S45. <https://doi.org/10.29271/jcpsp.2020.Supp1.S43>
46. Kim, J. S. (2001). Case report : Case report. *Canadian Family Physician*, *47*(10), 788–789.

47. Amador Penco, F. de B., Villalonga, D., Hermoso Martínez, J. I., & Smith Vielma, L. G. (2020). Massive subcutaneous emphysema in patient SARS-CoV-2 positive. *Revista Espanola de Anestesiologia y Reanimacion*, 67(9), 532–533. <https://doi.org/10.1016/j.redar.2020.06.011>
48. Toquica Gahona, C. C., Raj, K., Bhandari, K., Nuguru, S., & Bukhari, A. (2020). Subcutaneous Emphysema in Patients With COVID-19 Infection: A Report of Three Cases. *Cureus*, 12(9), 10–14. <https://doi.org/10.7759/cureus.10559>
49. González-Pacheco, H., Gopar-Nieto, R., Jiménez-Rodríguez, G. M., Manzur-Sandoval, D., Sandoval, J., & Arias-Mendoza, A. (2021). Bilateral spontaneous pneumothorax in SARS-CoV-2 infection: A very rare, life-threatening complication. *American Journal of Emergency Medicine*, 39, 258.e1-258.e3. <https://doi.org/10.1016/j.ajem.2020.07.018>
50. Wegner, U., Jeffery, G., Abrajan, O., Sampablo, I., & Singh, C. (2020). Spontaneous Pneumomediastinum Associated With SARS-CoV-2: Infrequent Complication of the Novel Disease. *Cureus*, 12(7). <https://doi.org/10.7759/cureus.9189>
51. Tucker, L., Patel, S., Vatsis, C., Poma, A., Ammar, A., Nasser, W., ... Carlan, S. (2020). Pneumothorax and Pneumomediastinum Secondary to COVID-19 Disease Unrelated to Mechanical Ventilation. *Case Reports in Critical Care*, 2020, 1–5. <https://doi.org/10.1155/2020/6655428>
52. Perice, L., Roit, Z., Llovera, I., & Flanagan-Kundle, M. (2020). Spontaneous Pneumothorax as a Complication of COVID-19 Pneumonia: A Case Report. *Clinical Practice and Cases in Emergency Medicine*, 4(4), 521–523. <https://doi.org/10.5811/cpcem.2020.8.49139>
53. Sonia, F., & Kumar, M. (2020). A Complication of Pneumothorax and Pneumomediastinum in a Non-Intubated Patient With COVID-19: A Case Report. *Cureus*, 12(8), 10–13. <https://doi.org/10.7759/cureus.10044>
54. Hussain, A., Noorani, A., Deshpande, R., John, L., Baghai, M., Wendler, O., ... Khan, H. (2020). Management of pneumothorax in mechanically ventilated COVID-19 patients: Early experience. *Interactive Cardiovascular and Thoracic Surgery*, 31(4), 540–543. <https://doi.org/10.1093/icvts/ivaa129>
55. Yamaya, T., Baba, T., Hagiwara, E., Ikeda, S., Niwa, T., Kitayama, T., ... Ogura, T. (2020). Pneumothorax in a COVID-19 pneumonia patient without underlying risk factors. *Internal Medicine*, 59(22), 2921–2925. <https://doi.org/10.2169/internalmedicine.5731-20>
56. Muhammad, A. I., Boynton, E. J., & Naureen, S. (2020). COVID-19 with bilateral pneumothoraces- case report. *Respiratory Medicine Case Reports*, 31, 101254. <https://doi.org/10.1016/j.rmcr.2020.101254>
57. Chen, X., Zhang, G., Tang, Y., Peng, Z., & Pan, H. (2020). The coronavirus diseases 2019 (COVID-19) pneumonia with spontaneous pneumothorax: A case report. *BMC Infectious Diseases*, 20(1), 1–5. <https://doi.org/10.1186/s12879-020-05384-x>
58. Selvaraj, V., & Dapaah-Afriyie, K. (2020). Iatrogenic Pneumothorax and Pneumomediastinum in a Patient with COVID-19. *Rhode Island Medical Journal (2013)*, 103(10), 32–33. <https://doi.org/10.1016/S1473-3099>
59. Umar Shahzad, M., Han, J., Ramtoola, M. I., Lamprou, V., & Gupta, U. (2021). Spontaneous Tension Pneumothorax as a Complication of COVID-19. *Case Reports in Medicine*, 2021. <https://doi.org/10.1155/2021/4126861>
60. Liu, K., Zeng, Y., Xie, P., Ye, X., Xu, G., Liu, J., ... Qian, J. (2020). COVID-19 with cystic features on computed tomography. *Medicine*, 99(18), e20175. <https://doi.org/10.1097/md.00000000000020175>
61. Sardenberg, R. A. S., Sant'Ana, J. P. E., Vicente, A. O., Pereira, A. S., Bertozzi, P. V., & Mano, R. B. C. (2020). Recurrent pneumothorax in a COVID-19 patient: A case report. *Respiratory Medicine Case Reports*, 31. <https://doi.org/10.1016/j.rmcr.2020.101201>

62. Fan, Q., Pan, F., & Yang, L. (2020). Spontaneous pneumothorax and subpleural bullae in a patient with COVID-19: A 92-day observation. *European Journal of Cardio-Thoracic Surgery*, 58(4), 858–860. <https://doi.org/10.1093/ejcts/ezaa305>
63. Alhakeem, A., Khan, M. M., Soub, H. Al, & Yousaf, Z. (2020). Case Report: COVID-19–Associated Bilateral Spontaneous Pneumothorax—A Literature Review. *American Journal of Tropical Medicine and Hygiene*, 103(3), 1162–1165. <https://doi.org/10.4269/ajtmh.20-0680>
64. Oye, M., Ali, A., Kandah, F., & Chowdhury, N. (2020). Two cases of spontaneous pneumomediastinum with pneumothorax in patients with COVID-19 associated pneumonia. *Respiratory Medicine Case Reports*, 31, 101308. <https://doi.org/10.1016/j.rmcr.2020.101308>
65. Pooni, R., Pandey, G., & Akbar, S. (2020). Broadening the differential: pneumomediastinum and COVID-19 infection. *BMJ Case Reports*, 13(8), 1–4. <https://doi.org/10.1136/bcr-2020-237938>
66. Silva, C. A. (1974). Clinical cases. *Ars Curandi Em Odontologia*, 1(5), 46–48.
67. Bellini, D., Lichtner, M., Vicini, S., Rengo, M., Ambrogi, C., & Carbone, I. (2020). Spontaneous pneumomediastinum as the only CT finding in an asymptomatic adolescent positive for COVID-19. *BJR/case Reports*, 6(3), 20200051. <https://doi.org/10.1259/bjrcr.20200051>
68. Janssen, M. L., van Manen, M. J. G., Cretier, S. E., & Braunstahl, G. J. (2020). Pneumothorax in patients with prior or current COVID-19 pneumonia. *Respiratory Medicine Case Reports*, 31, 101187. <https://doi.org/10.1016/j.rmcr.2020.101187>
69. Xu, Y., Li, S., & Liu, H. (2021). Clinical outcomes of pleural drainage on pneumothorax and hydrothorax in critically ill patients with COVID-19: A case series with literature review. *Heart and Lung*, 50(2), 213–219. <https://doi.org/10.1016/j.hrtlng.2020.12.007>
70. Polistina, G. E., Simioli, F., Imitazione, P., Lanza, M., Annunziata, A., & Fiorentino, G. (2020). Different presentation of pulmonary parenchymal disruption in COVID-19 pneumonia. Case series of Sub-Intensive Care Unit in Naples, Italy. *Monaldi Archives for Chest Disease*, 90(4), 572–576. <https://doi.org/10.4081/MONALDI.2020.1482>
71. Singh, A., Bass, J., & Lindner, D. H. (2020). Rare Complication of Pneumomediastinum and Pneumopericardium in a Patient with COVID-19 Pneumonia. *Case Reports in Pulmonology*, 2020. <https://doi.org/10.1155/2020/8845256>
72. Bassi, M., Anile, M., Pecoraro, Y., Ruberto, F., Martelli, S., Piazzolla, M., ... De Giacomo, T. (2020). Bedside Transcervical-Transtracheal Postintubation Injury Repair in a COVID-19 Patient. *Annals of Thoracic Surgery*, 110(5), e417–e419. <https://doi.org/10.1016/j.athoracsur.2020.04.009>
73. Akdogan, R. E., Mohammed, T., Syeda, A., Jiwa, N., Ibrahim, O., & Mutneja, R. (2021). Pneumothorax in Mechanically Ventilated Patients with COVID-19 Infection. *Case Reports in Critical Care*, 2021. <https://doi.org/10.1155/2021/6657533>
74. Deliwala, S. S., Ponnappalli, A., Seedahmed, E., Berrou, M., Bachuwa, G., & Chandran, A. (2020). A 29-year-old male with a fatal case of covid-19 acute respiratory distress syndrome (Cards) and ventilator-induced lung injury (vili). *American Journal of Case Reports*, 21, 1–6. <https://doi.org/10.12659/AJCR.926136>
75. Urigo, C., Soin, S., & Sahu, A. (2020). Spontaneous pneumomediastinum as a complication of a COVID-19 related pneumonia: case report and review of literature. *Radiology Case Reports*, 15(12), 2577–2581. <https://doi.org/10.1016/j.radcr.2020.09.052>
76. Khurram, R., Johnson, F. T. F., Naran, R., & Hare, S. (2020). Spontaneous tension pneumothorax and acute pulmonary emboli in a patient with COVID-19 infection. *BMJ Case Reports*, 13(8), 11–14. <https://doi.org/10.1136/bcr-2020-237475>

77. Aiolfi, A., Bruni, B., Biraghi, T., Montisci, A., Miceli, A., Baronio, B., ... Bona, D. (2020). Late histological findings in symptomatic COVID-19 patients: A case report. *Medicine*, 99(28), e21046. <https://doi.org/10.1097/MD.00000000000021046>
78. Horii, T., Fujioka, T., Takahashi, M., Mori, M., Tsuchiya, J., Yamaga, E., ... Tateishi, U. (2020). Late-onset pneumothorax in a COVID-19 patient treated with ventilation and ECMO: A case report and literature review. *Radiology Case Reports*, 15(12), 2560–2564. <https://doi.org/10.1016/j.radcr.2020.09.036>
79. Yasukawa, K., Vamadevan, A., & Rollins, R. (2020). Images in clinical tropical medicine bulla formation and tension pneumothorax in a patient with COVID-19. *American Journal of Tropical Medicine and Hygiene*, 103(3), 943–944. <https://doi.org/10.4269/ajtmh.20-0736>
80. Brogna, B., Bignardi, E., Salvatore, P., Alberigo, M., Brogna, C., Megliola, A., ... Musto, L. (2020). Unusual presentations of COVID-19 pneumonia on CT scans with spontaneous pneumomediastinum and loculated pneumothorax: A report of two cases and a review of the literature. *Heart and Lung*, 49(6), 864–868. <https://doi.org/10.1016/j.hrtlng.2020.06.005>
81. Rehman, T., Josephson, G., Sunbuli, M., & Chadaga, A. R. (2020). Spontaneous pneumothorax in an elderly patient with coronavirus disease (COVID-19) pneumonia. *Ochsner Journal*, 20(3), 343–345. <https://doi.org/10.31486/toj.20.0072>
82. Ezeagu, R., Olanipekun, T., Santoshi, R., Seneviratne, C., & Kupfer, Y. (2021). Pulmonary barotrauma resulting from mechanical ventilation in 2 patients with a diagnosis of covid-19 pneumonia. *American Journal of Case Reports*, 22(1), 1–7. <https://doi.org/10.12659/AJCR.927954>
83. Sardenberg, R. A. S., Sant'Ana, J. P. E., Vicente, A. O., Pereira, A. S., Bertozzi, P. V., & Mano, R. B. C. (2020). Recurrent pneumothorax in a COVID-19 patient: A case report. *Respiratory Medicine Case Reports*, 31. <https://doi.org/10.1016/j.rmcr.2020.101201>
84. Liu, Y., Wang, M., Luo, G., Qian, X., Wu, C., Zhang, Y., ... Tang, Y. (2020). Experience of N-acetylcysteine airway management in the successful treatment of one case of critical condition with COVID-19: A case report. *Medicine*, 99(42), e22577. <https://doi.org/10.1097/MD.00000000000022577>
85. Elder, C., Bawa, S., Anderson, D., Atkinson, S., Etzel, J., & Moritz, T. (2020). Expectant management of pneumothorax in intubated COVID-19 positive patients: A case series. *Journal of Cardiothoracic Surgery*, 15(1), 1–5. <https://doi.org/10.1186/s13019-020-01297-7>
86. Caviezel, C., Weiss, L., Haessig, G., Alfaré, C., Haberecker, M., Varga, Z., ... Opitz, I. (2020). Case report of sequential bilateral spontaneous pneumothorax in a never-ventilated, lung-healthy COVID-19-patient. *International Journal of Surgery Case Reports*, 75, 441–445. <https://doi.org/10.1016/j.ijscr.2020.09.148>
87. Abushahin, A., Degliuomini, J., Aronow, W. S., & Newman, T. G. (2020). A case of spontaneous pneumothorax 21 days after diagnosis of coronavirus disease 2019 (COVID-19) pneumonia. *American Journal of Case Reports*, 21, 1–4. <https://doi.org/10.12659/AJCR.925787>
88. Fleming, A. M., Zambetti, B. R., & Valaulikar, G. S. (2021). Bedside Mediastinotomy for Tension Pneumomediastinum with Tamponade in COVID-19. *The Annals of Thoracic Surgery*. <https://doi.org/10.1016/j.athoracsur.2021.01.032>
89. Lehmann-horn, K., Sagan, S. A., Bernard, C. C. A., Sobel, A., Zamvil, S. S., Wanna, A. G. B., ... Dawant, B. M. (2014). This article has been accepted for publication and undergone full peer review but has not been through the copyediting, typesetting, pagination and proofreading process which may lead to differences between this version and the Version of Record. Please c. *The Laryngoscope*, (August), 2–31.

90. Harper, S., Robinson, M., Manning, G., Jones, A., Hobson, J., & Shelton, C. L. (2020). Management of tracheostomy-related tracheomegaly in a patient with COVID-19 pneumonitis. *Anaesthesia Reports*, 8(2), 159–162. <https://doi.org/10.1002/anr3.12076>
91. Rafiee, M. J., Babaki Fard, F., Samimi, K., Rasti, H., & Pressacco, J. (2021). Spontaneous pneumothorax and pneumomediastinum as a rare complication of COVID-19 pneumonia: Report of 6 cases. *Radiology Case Reports*, 16(3), 687–692. <https://doi.org/10.1016/j.radcr.2021.01.011>
92. Vahidirad, A., Jangjoo, A., Ghelichli, M., Arian Nia, A., & Zandbaf, T. (2021). Tension pneumothorax in patient with COVID-19 infection. *Radiology Case Reports*, 16(2), 358–360. <https://doi.org/10.1016/j.radcr.2020.11.044>
93. Reddy, A., Engelhardt, K., & Jain, D. (2020). Air leak syndrome in two very preterm infants born to mothers with coronavirus disease 2019: An association or a coincidence? *AJP Reports*, 10(3), E266–E269. <https://doi.org/10.1055/s-0040-1715180>
94. Dennison, J., Carlson, S., Faehling, S., Lieb, M., & Mubarik, A. (2020). Case report: Spontaneous pneumothorax in resolved, uncomplicated COVID-19 Pneumonia-A literature review. *Respiratory Medicine Case Reports*, 31, 101291. <https://doi.org/10.1016/j.rmcr.2020.101291>
95. Sanchez-Nadales, A., Treminio-Quezada, M., Abad, H., Navarro-Motta, J., Contreras-Chavez, P., Kachru, A., & Chu, C. (2020). Critical Care Management for Novel 2019 SARS-CoV-2 and HCoV-NL63 Coinfection in a Young Immunocompromised Patient: A Chicago Experience. *Case Reports in Critical Care*, 2020(December 2019), 1–8. <https://doi.org/10.1155/2020/8877641>
96. Afrazi, A., Garcia-Rodriguez, S., Maloney, J. D., & Morgan, C. T. (2021). Cavitory lung lesions and pneumothorax in a healthy patient with active Coronavirus-19 (COVID-19) viral pneumonia. *Interactive Cardiovascular and Thoracic Surgery*, 32(1), 150–152. <https://doi.org/10.1093/icvts/ivaa238>
97. Amoah, K., Gunasekaran, K., Rahi, M. S., & Buscher, M. G. (2020). A case of secondary tension pneumothorax in COVID-19 pneumonia in a patient with no prior history of lung disease. *SAGE Open Medical Case Reports*, 8, 2050313X2096750. <https://doi.org/10.1177/2050313x20967504>
98. Fahad, A. M., Mohammad, A. A., Al-Khalidi, H. A., & Alshewered, A. S. (2020). Spontaneous pneumothorax as a complication in COVID-19 male patient: A case report. *Clinical Case Reports*, 8(12), 3116–3119. <https://doi.org/10.1002/ccr3.3378>
99. Capleton, P., Ricketts, W., Lau, K., Ellis, S., Sheaff, M., Giaslakitotis, K., ... Tchrakian, N. (2021). Pneumothorax and Pneumatocoele Formation in a Patient with COVID-19: a Case Report. *SN Comprehensive Clinical Medicine*, 3(1), 269–272. <https://doi.org/10.1007/s42399-020-00689-z>
100. Nakatsutsumi, K., Sekiya, K., Urushibata, N., Hosoi, M., Arai, H., Nagaoka, E., ... Otomo, Y. (2020). A successful case of extracorporeal membrane oxygenation treatment for intractable pneumothorax in a patient with COVID-19. *Acute Medicine & Surgery*, 7(1), 2–5. <https://doi.org/10.1002/ams2.612>
101. Placik, D. A., Taylor, W. L., & Wnuk, N. M. (2020). Bronchopleural fistula development in the setting of novel therapies for acute respiratory distress syndrome in SARS-CoV-2 pneumonia. *Radiology Case Reports*, 15(11), 2378–2381. <https://doi.org/10.1016/j.radcr.2020.09.026>
102. Gupta, V. K., Alkandari, B. M., Mohammed, W., Tobar, A. M., & Abdelmohsen, M. A. (2021). Ventilator associated lung injury in severe COVID-19 pneumonia patients – Case

- Reports: Ventilator associated lung injury in COVID-19. *European Journal of Radiology Open*, 8, 100310. <https://doi.org/10.1016/j.ejro.2020.100310>
103. Kaisy, M. A. Al. (2020). Chest drain insertion following pneumothorax due to CPR in a COVID – 19 patient. *Visual Journal of Emergency Medicine*, 21(June), 100862. <https://doi.org/10.1016/j.visj.2020.100862>
104. Vidrio Duarte, R., Vidrio Duarte, E., Gutierrez Ochoa, J., Gaviria Leiva, M. C., & Pimentel-Hayashi, J. A. (2021). Pneumoperitoneum in a COVID-19 Patient Due to the Macklin Effect. *Cureus*, 13(2), 8–11. <https://doi.org/10.7759/cureus.13200>
105. Vaikunth, S. S., Bykhovsky, M. R., Romfh, A. W., Haeffele, C. L., Rogers, I. S., Dong, E., ... Lui, G. K. (2021). A 40-Year-Old Man With Tricuspid Atresia, Status Post-Fontan, With Severe COVID-19 Pneumonia and Pneumothorax. *JACC: Case Reports*, 3(2), 187–191. <https://doi.org/10.1016/j.jaccas.2020.10.032>
106. Kasturi, S., Muthirevula, A., Chinthareddy, R. R., & Lingaraju, V. C. (2021). Delayed recurrent spontaneous pneumothorax post-recovery from COVID-19 infection. *Indian Journal of Thoracic and Cardiovascular Surgery*, 1–3. <https://doi.org/10.1007/s12055-021-01145-w>
107. Xu, W., Luo, X., Wang, H., Shen, C., Song, Y., Sun, T., & Chen, M. (2021). Pulmonary emphysema, bullae and pneumothorax in COVID-19 pneumonia. *Radiology Case Reports*, 0–9. <https://doi.org/10.1016/j.radcr.2021.01.055>