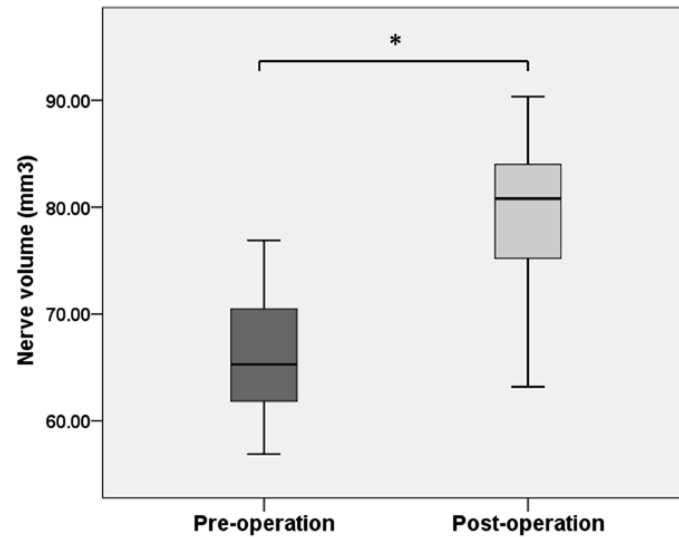


Supplemental material



The figure displayed ipsilateral TGN volume comparison between pre- and post-operation (1 year after MVD surgery) in 15 primary TN patients. The volume of ipsilateral TGN increased statistically after operation compared to that at the time point of pre-operation in the patient group.

*: Mann-Whitney U test, $p < 0.01$