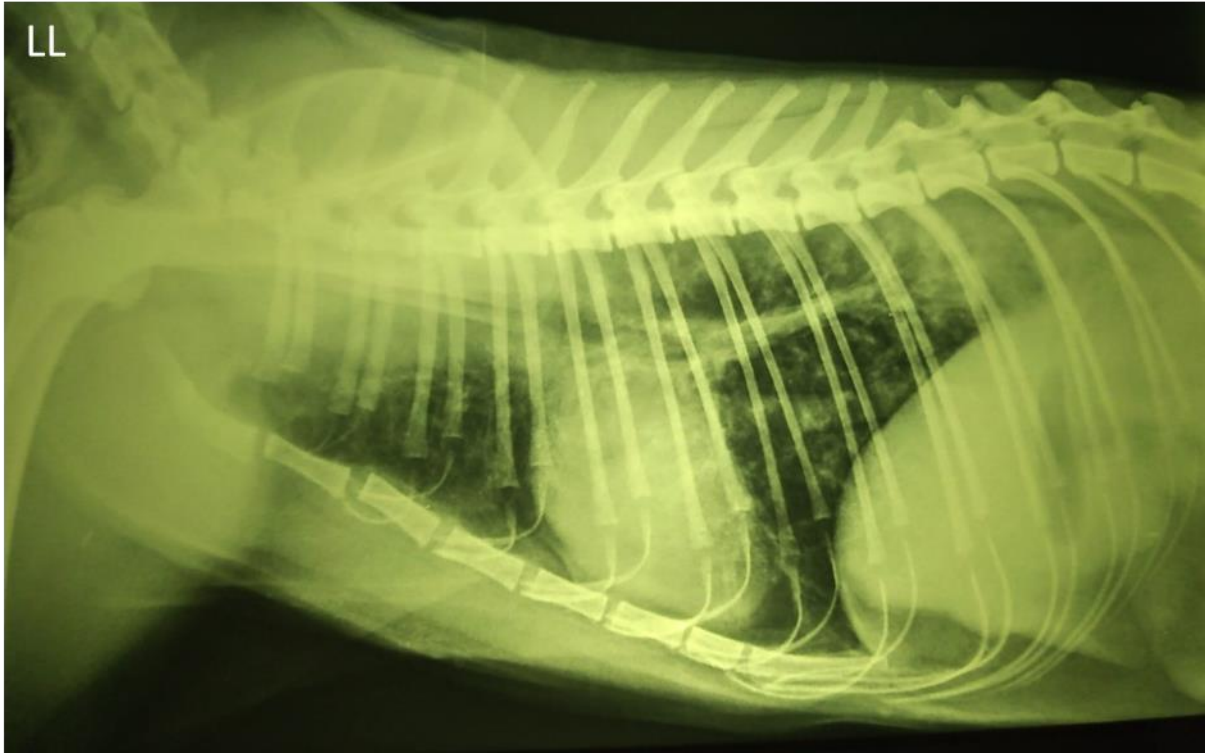
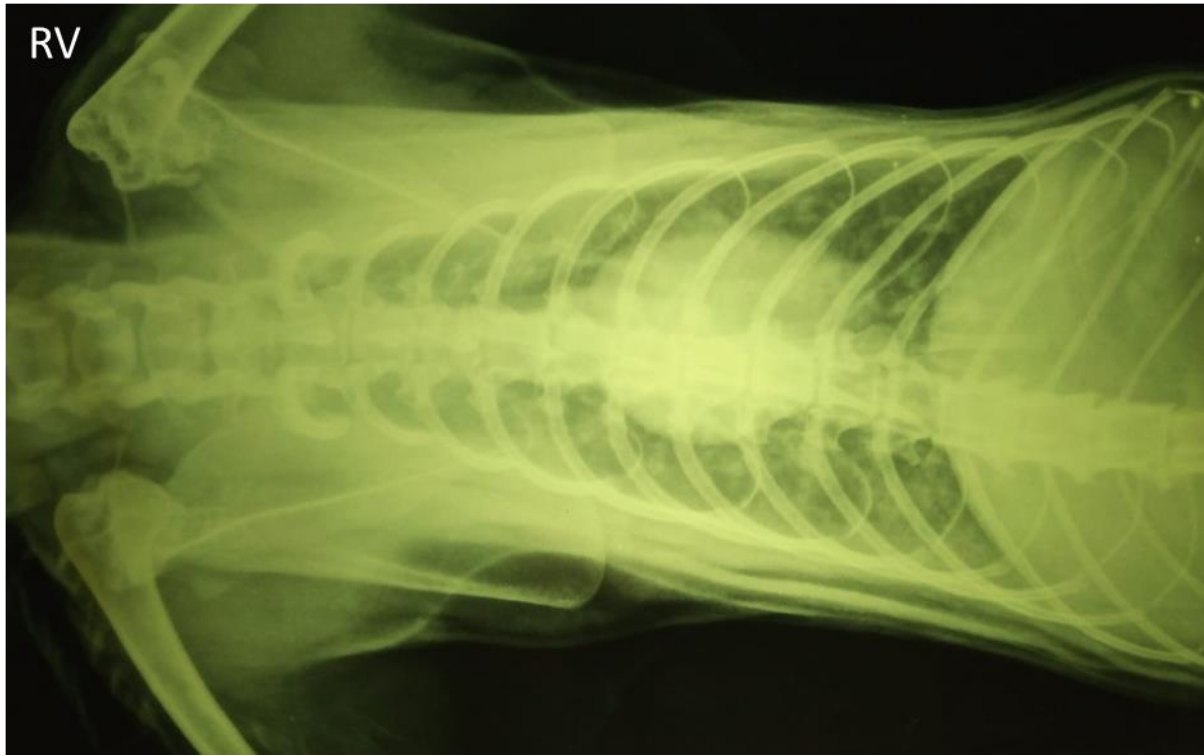


## *Supplementary Material*

### 1.1 Supplementary Figures





**Supplementary Figure 1.** Latero-Lateral (LL) and Ventrodorsal (RV) radiographic views of Cat N°3.