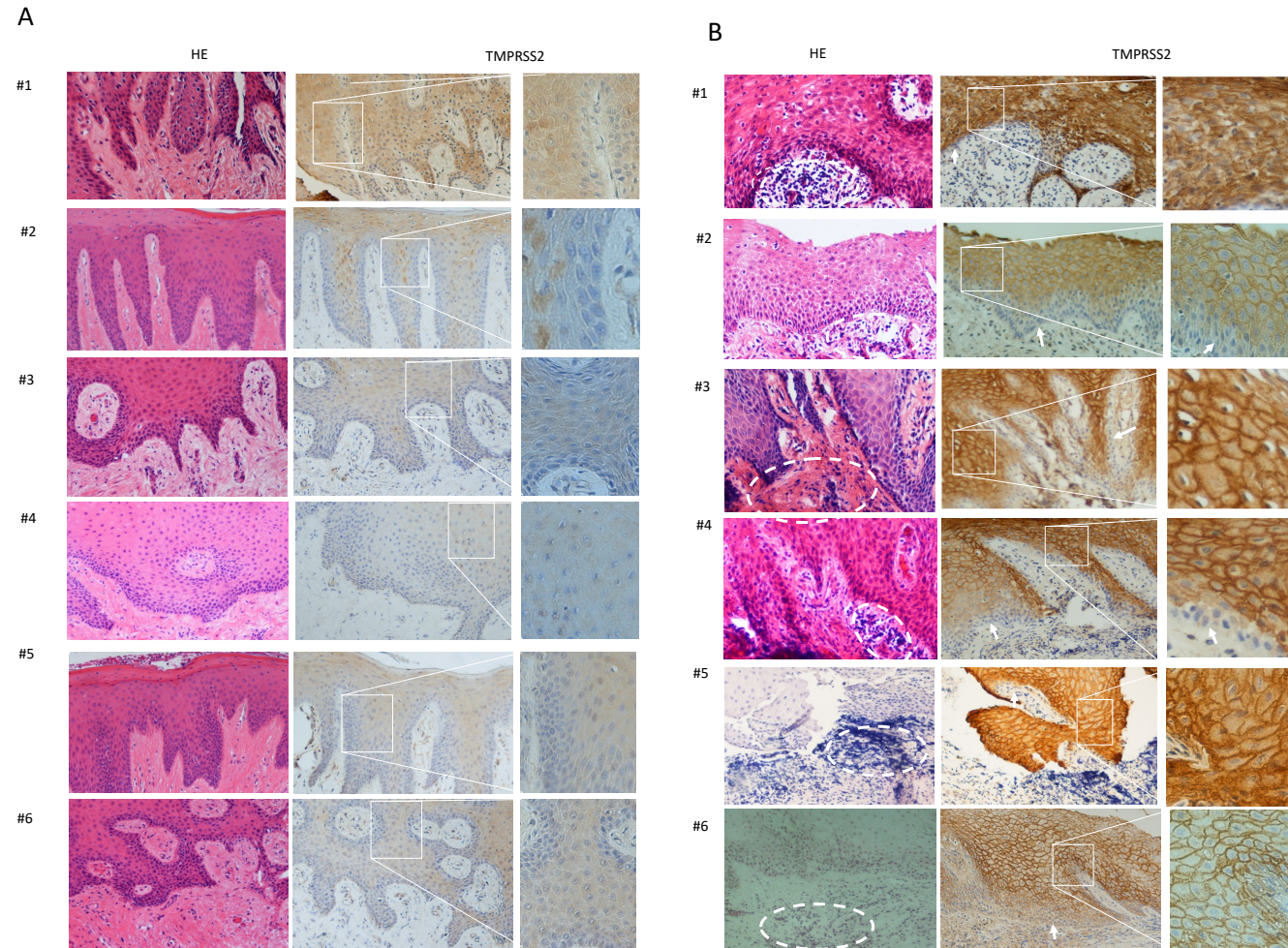


Supplemental Figure S1



Supplemental Figure S1. Immunohistochemical analysis of TMPRSS2 in gingival tissues derived from individual patients with periodontitis. Six healthy gingival tissues (A #1-6) and six gingival tissues with periodontitis (B #1-6) were immunohistochemically analyzed. Hematoxylin-eosin (HE) staining (left panels) and immunohistochemical staining with anti-TMPRSS2 antibody (TMPRSS2; center and right panels) using DAB. The dotted circles indicate the areas of inflammatory cell infiltration. The arrows indicate the basal layer of the gingival epithelium. Magnification: x100 (left and center panels) and x200 (right panels).