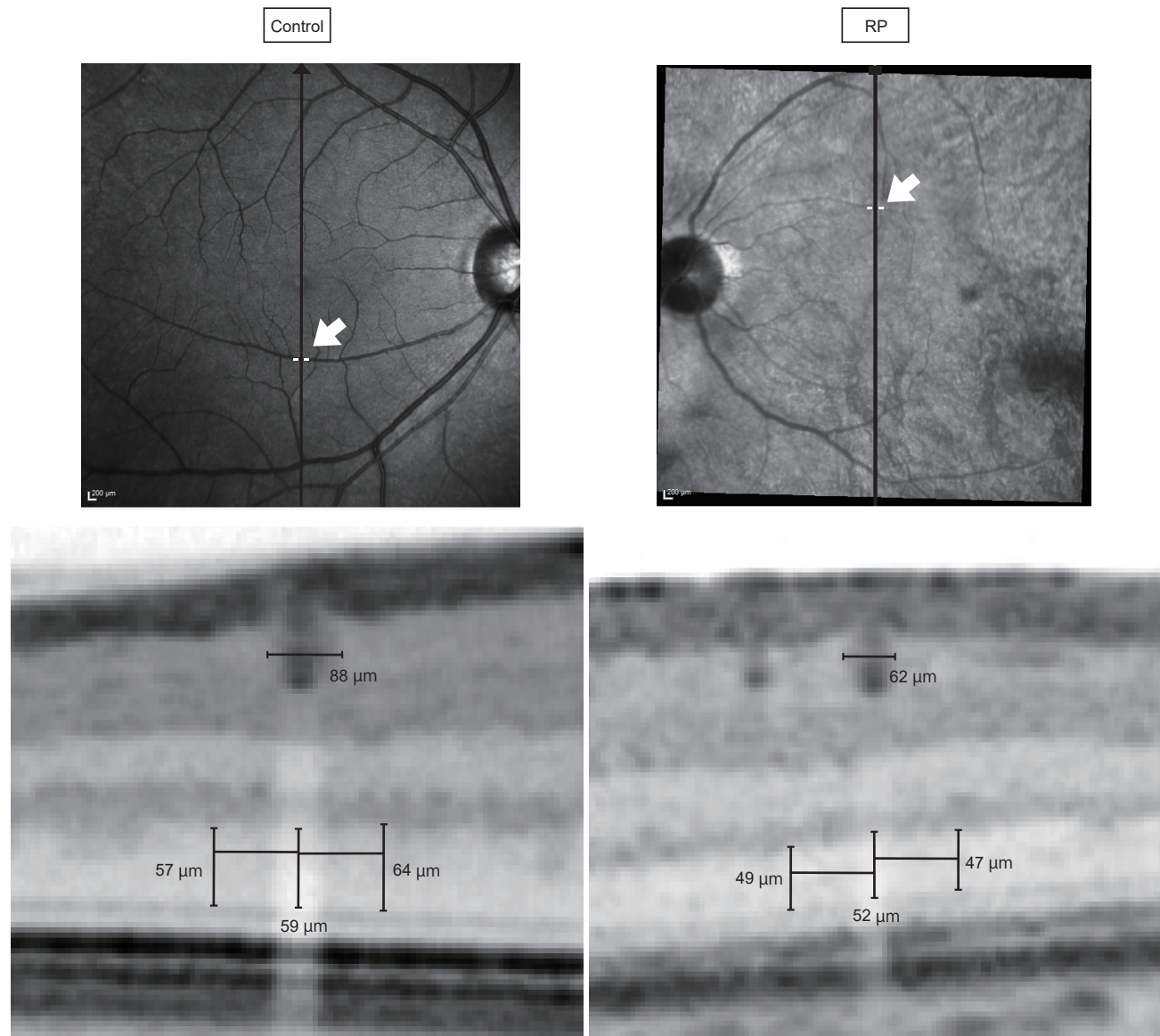


Supplemental Figure.S1



Supplemental Figure S1. Representative SD-OCT images of healthy control and patient with RP. Representative images of outer nuclear layer (ONL) measurements in healthy control and a patient with retinitis pigmentosa (RP). The retinal vessel diameter and each ONL thickness were larger in healthy control than RP. However, ONL preservation ratio was large in RP compared to healthy subject. (0.98 and 1.08, respectively)