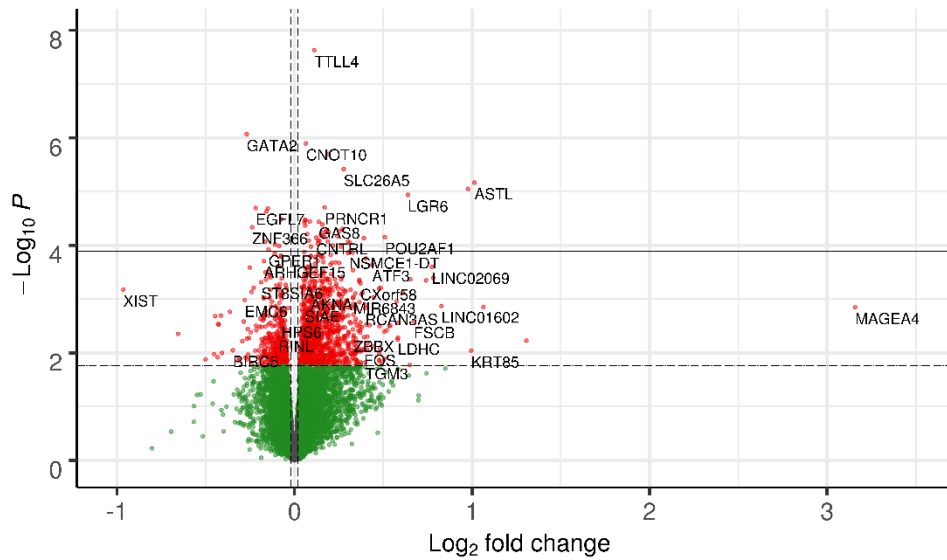
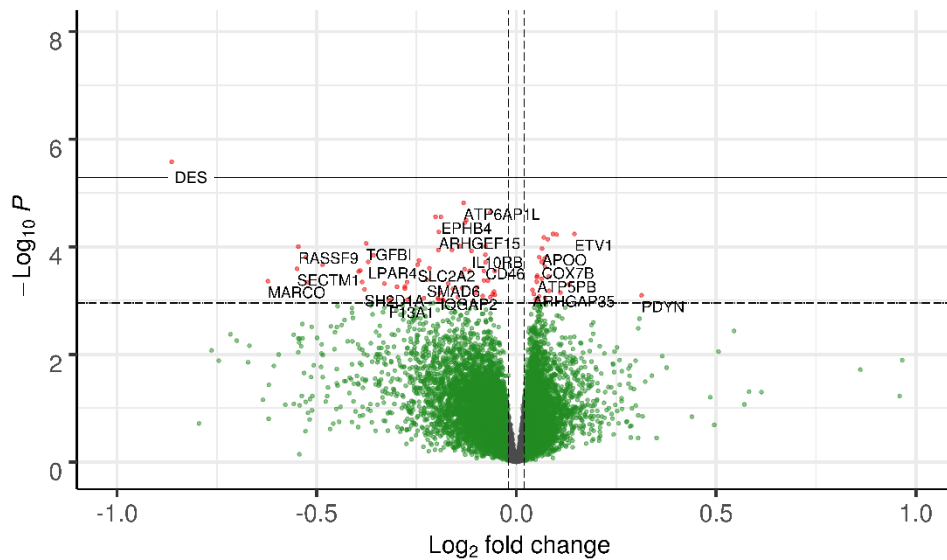


A) Caudate Nucleus



B) Putamen



C) Ventral Striatum

