

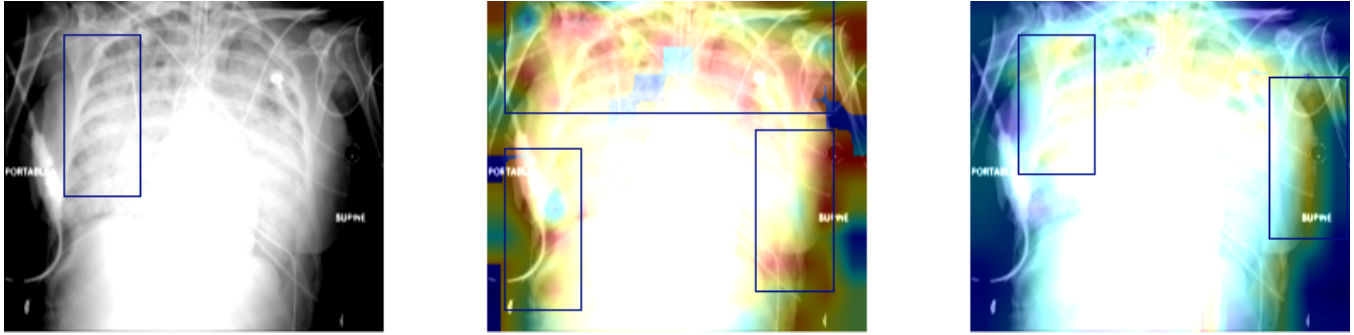Fig. 4. Visualization of Attention Maps. The left figure is the original **Pneumonia** chest X-ray with a bounding box, and the middle figure and right figure are the attention maps of the final attention layer ResNetAtt and ResNetAttRadi, respectively.

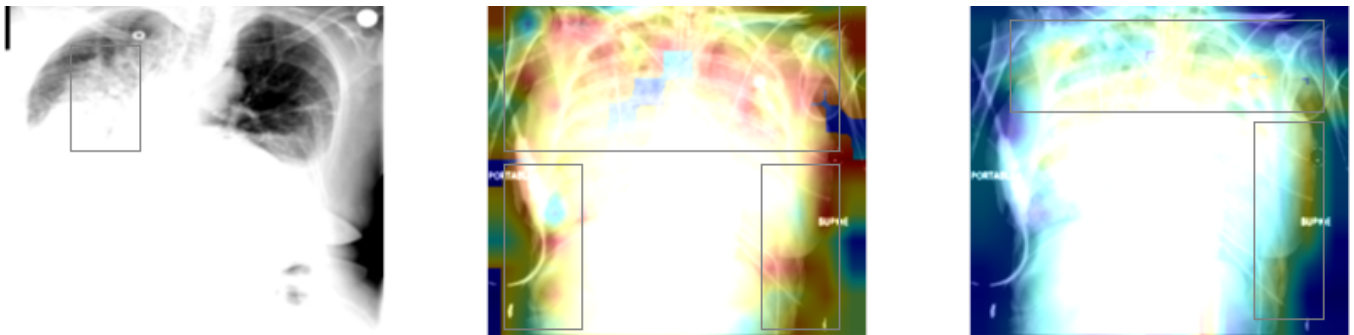


Fig. 5. Visualization of Attention Maps. The left figure is the original **Pneumonia** chest X-ray with a bounding box, and the middle figure and right figure are the attention maps of the final attention layer ResNetAtt and ResNetAttRadi, respectively.

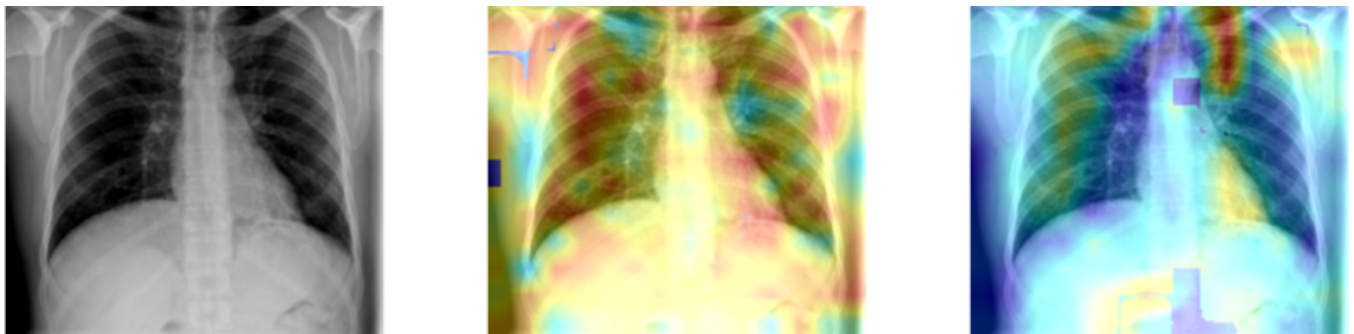


Fig. 6. Visualization of Attention Maps. The left figure is the original **Normal** chest X-ray, and the middle figure and right figure are the attention maps of the final attention layer ResNetAtt and ResNetAttRadi, respectively.

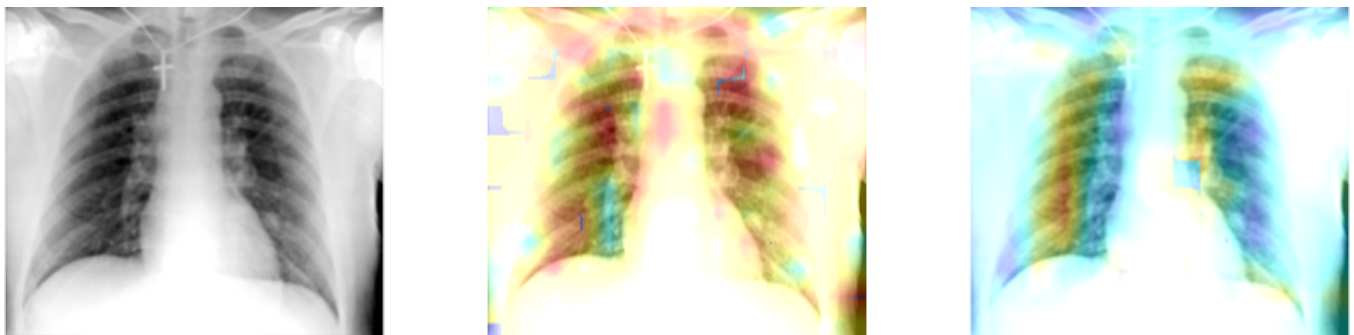


Fig. 7. Visualization of Attention Maps. The left figure is the original **Normal** chest X-ray, and the middle figure and right figure are the attention maps of the final attention layer ResNetAtt and ResNetAttRadi, respectively.