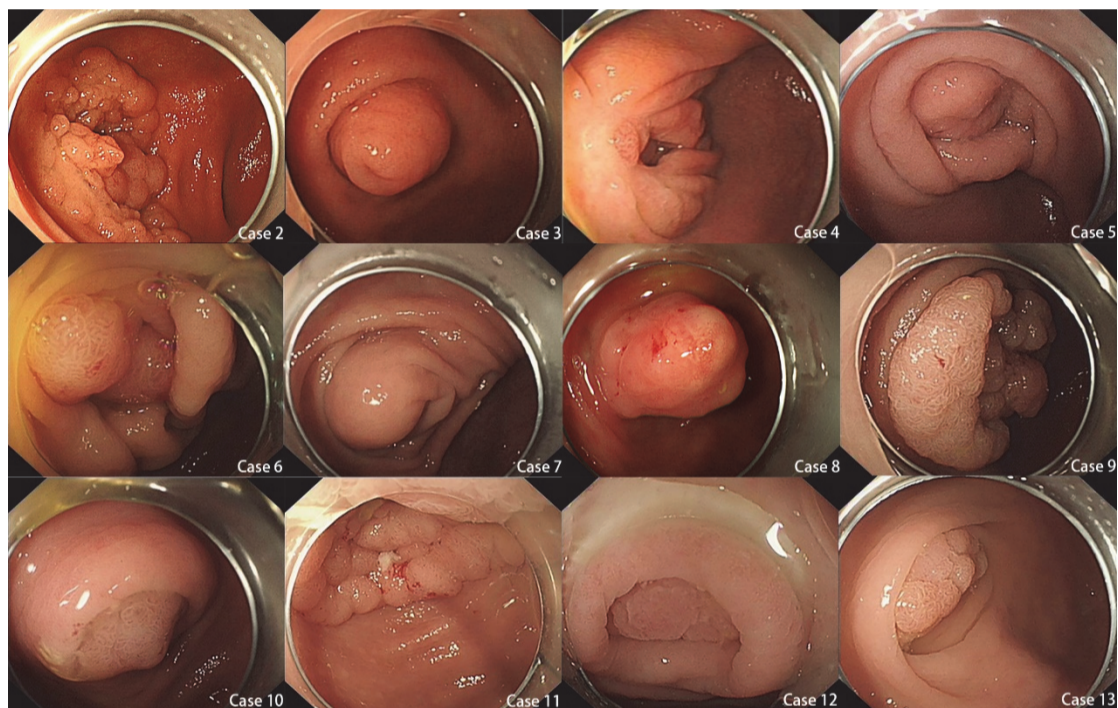


## Supplementary material

**Endoscopic transcecal appendectomy: a new endotherapy for appendiceal orifice lesions**

Guo L et al.

**Fig. 1s** Endoscopic images of the 12 patients with lesions involving the appendiceal orifice (the image of case 1 was published previously [1], and thus was not shown here).

**Reference**

1. Yuan XL, Cheung O, Du J et al. Endoscopic transcecal appendectomy. *Endoscopy* 2019; 51: 994–995