

Supplementary material for

Conventional finite element models estimate the strength of metastatic human vertebrae despite alterations of the bone's tissue and structure

Marc A. Stadelmann ^a, Denis E. Schenk ^a, Ghislain Maquer ^a, Christopher Lenherr ^a, Florian M. Buck ^b, Dieter D. Bosshardt ^c, Sven Hoppe ^d, Nicolas Theumann ^e, Ron N. Alkalay ^f, Philippe K. Zysset ^{a,*}

a ARTORG Center for Biomedical Engineering Research, University of Bern, Bern, Switzerland

b University of Zurich & MRI Schulthess Clinic, Zurich, Switzerland

c Robert K. Schenk Laboratory of Oral Histology, School of Dental Medicine, University of Bern, Switzerland

d Department of Orthopedic Surgery, Inselspital, Bern University Hospital, Switzerland

e Clinique Bois-Cerf, Radiology Department, Lausanne, Switzerland

f Center for Advanced Orthopedic Studies, Beth Israel Deaconess Medical Center and Harvard Medical School, Boston, USA

* Email address: philippe.zysset@artorg.unibe.ch

URL: www.artorg.unibe.ch

Description:

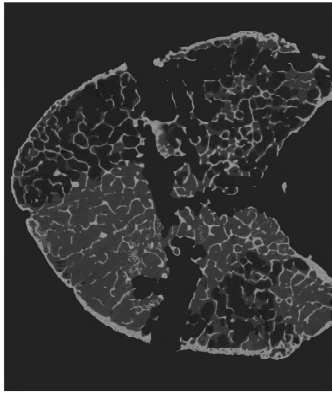
- Eleven cadaver spines (3 female, 8 male, age 49 to 71, mean 54) were obtained through the Anatomy Gifts Registry from donors with known history of solid primary tumors (3 breast, 3 lung, 2 prostate, 2 kidney, 1 esophageal).
- All soft tissues were removed. Each vertebra was separated by cutting through the discs and the posterior elements were cut at the pedicles. Both endplates were cut under water irrigation, resulting in plano-parallel vertebral body sections.
- Each vertebral section was scanned via μ CT at 24.5 μ m. High-frequency noise was reduced with a Gauss filter and a custom script was used to generate a mask separating the bone from its background.
- This document presents :
 - a photograph of each vertebral section (if available).
 - midplane slices taken from the corresponding μ CT in 3 orthogonal planes.
 - pseudo-Xray images generated by projecting the μ CT on 3 orthogonal planes.

Notes:

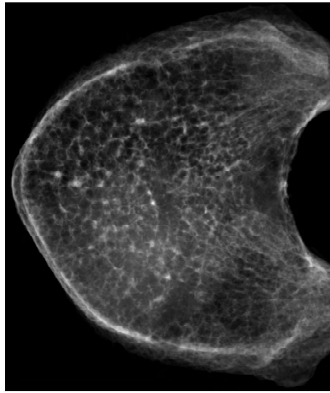
- Sample X 123: the letter refers to the spine, the digits to the vertebral section.
- Please find the demographics and primary tumor of the donors in the **Table 1 of the publication**.
- Please find the spinal level, lesion type, bone volume ratio, experimental strength (F_{exp}), μ FE stiffness ($K_{\mu FE}$), bone mineral content (BMC), and hFE strength (F_{hFE}) in the **Table 4 of the publication**.

Sample D 164

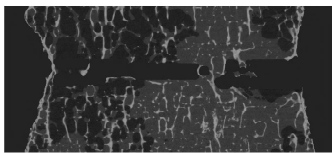
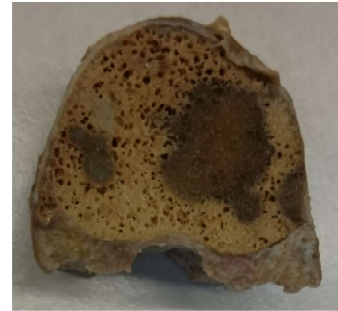
Lesion type:



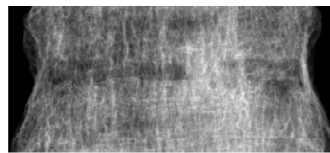
Midplane direction 1



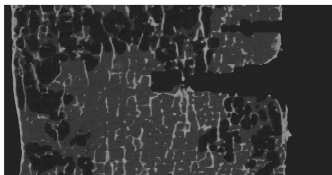
X-ray direction 1



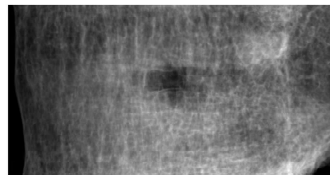
Midplane direction 2



X-ray direction 2



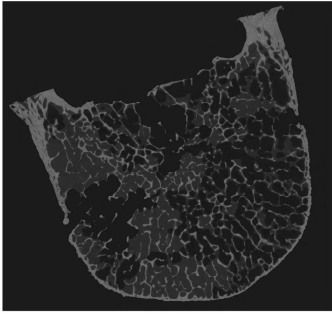
Midplane direction 3



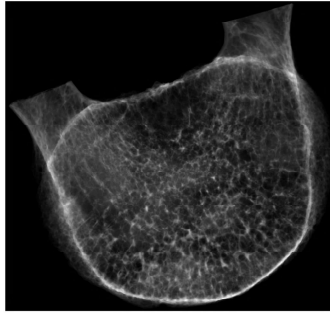
X-ray direction 3

Sample D 168

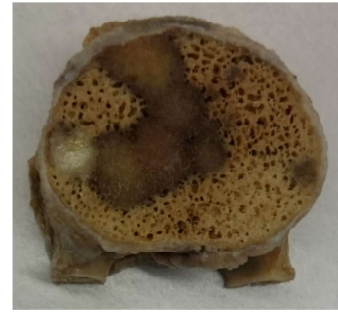
Lesion type:



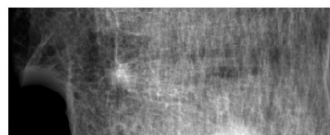
Midplane direction 1




X-ray direction 1



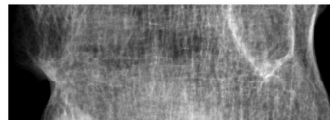
Midplane direction 2



X-ray direction 2



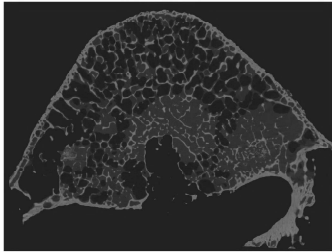
Midplane direction 3



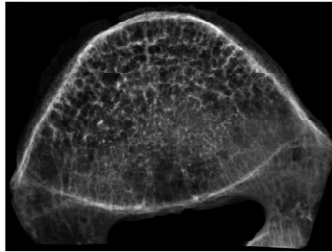
X-ray direction 3

Sample D 171

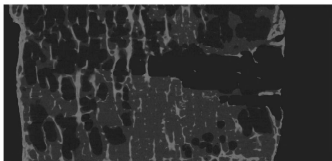
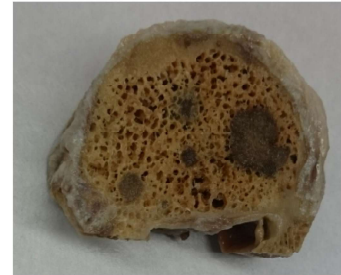Lesion type:



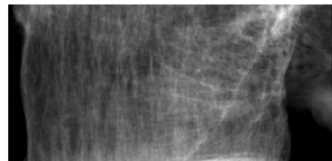
Midplane direction 1



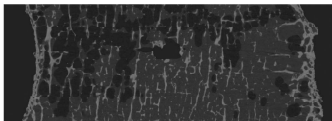
X-ray direction 1



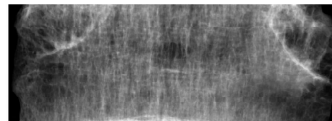
Midplane direction 2



X-ray direction 2



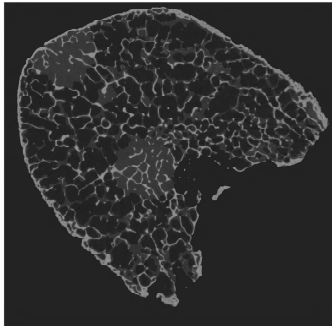
Midplane direction 3



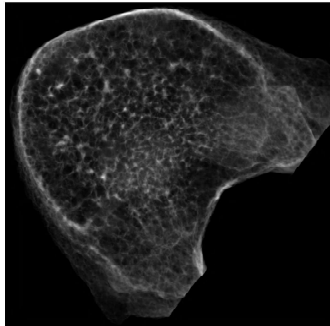
X-ray direction 3

Sample D 172

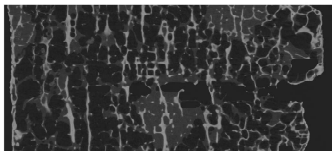
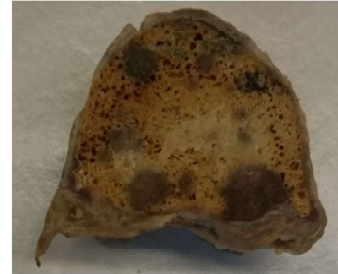Lesion type:



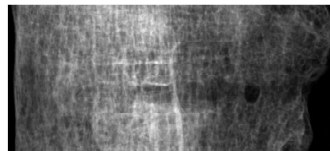Midplane direction 1



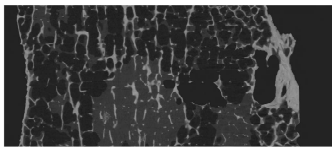
X-ray direction 1



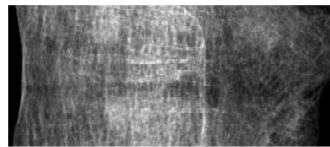
Midplane direction 2



X-ray direction 2



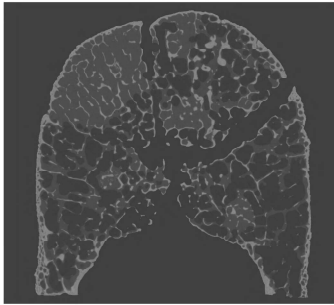
Midplane direction 3



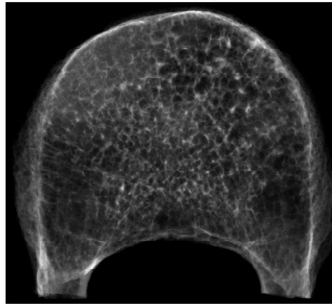
X-ray direction 3

Sample D 175

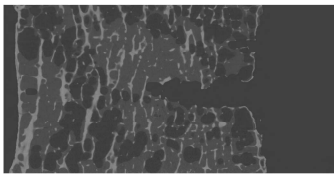
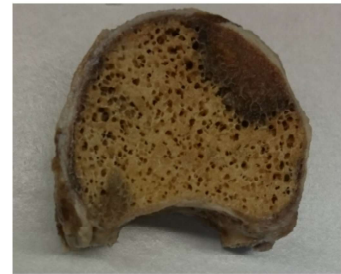Lesion type:



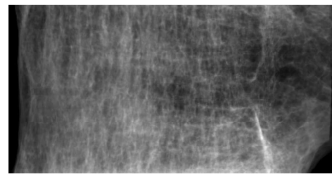
Midplane direction 1



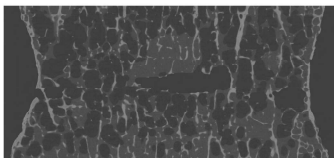
X-ray direction 1



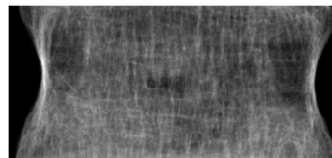
Midplane direction 2



X-ray direction 2



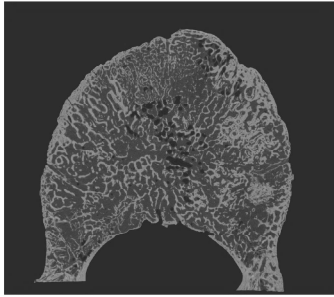
Midplane direction 3



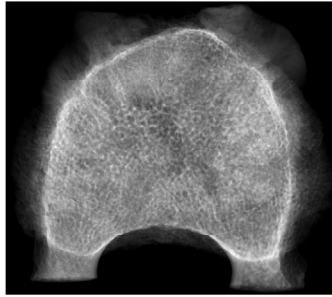
X-ray direction 3

Sample A 180


Lesion type:



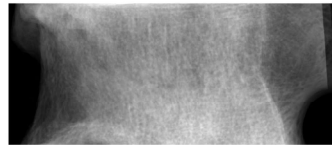
Midplane direction 1



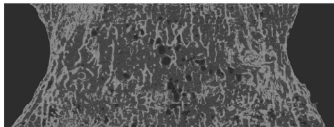
X-ray direction 1



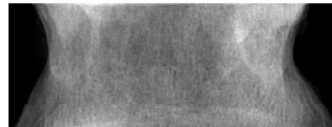
Midplane direction 2



X-ray direction 2



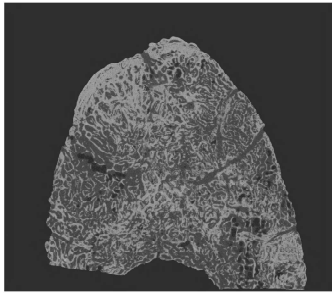
Midplane direction 3



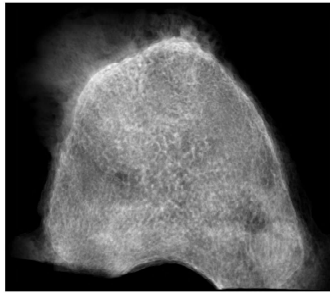
X-ray direction 3

Sample A 181

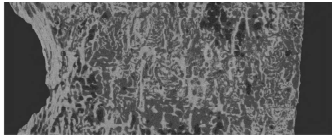
Lesion type:




Midplane direction 1



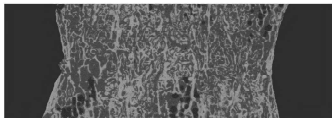
X-ray direction 1




Midplane direction 2



X-ray direction 2



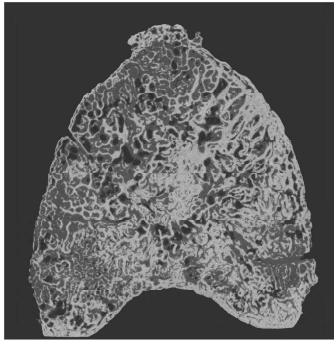
Midplane direction 3



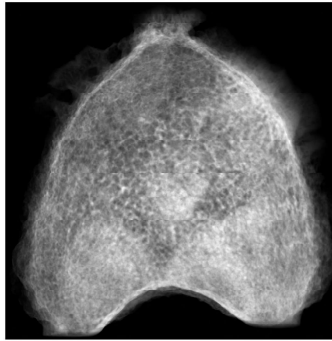
X-ray direction 3

Sample A 183

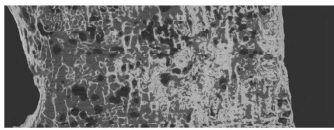
Lesion type:



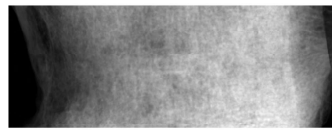
Midplane direction 1



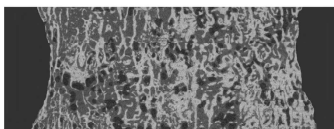
X-ray direction 1



Midplane direction 2



X-ray direction 2



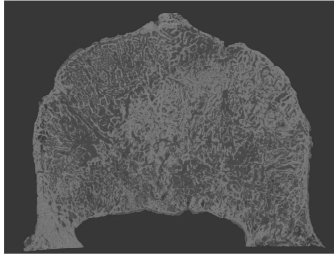
Midplane direction 3



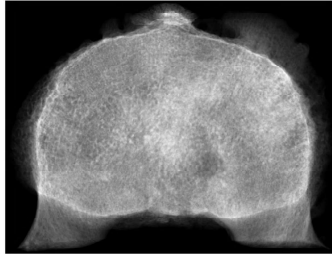
X-ray direction 3

Sample A 185

Lesion type:



Midplane direction 1




X-ray direction 1



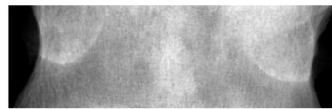
Midplane direction 2



X-ray direction 2



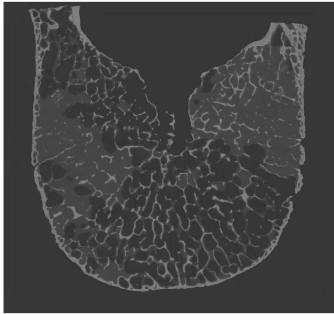
Midplane direction 3



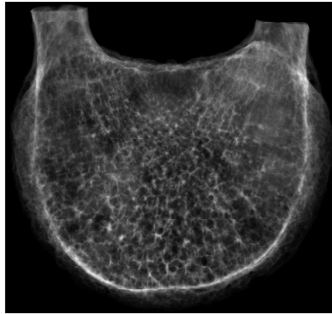
X-ray direction 3

Sample D 191

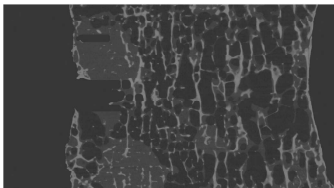
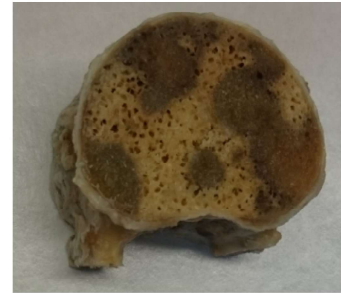Lesion type:



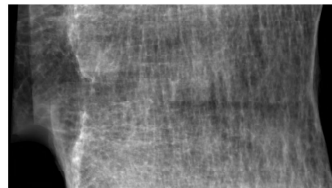
Midplane direction 1




X-ray direction 1



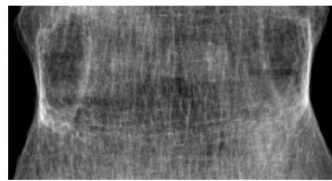
Midplane direction 2



X-ray direction 2



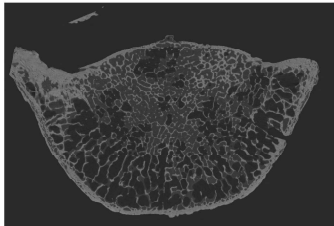
Midplane direction 3



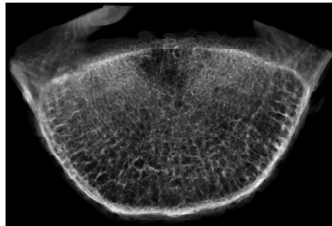
X-ray direction 3

Sample G 194

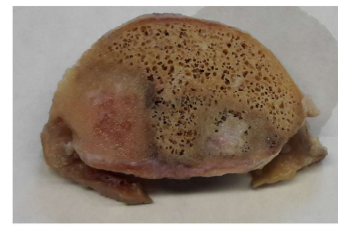
Lesion type:



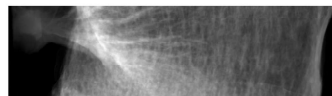
Midplane direction 1




X-ray direction 1



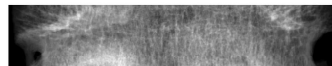
Midplane direction 2



X-ray direction 2



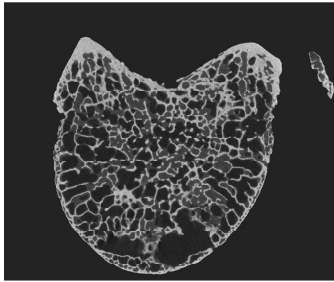
Midplane direction 3



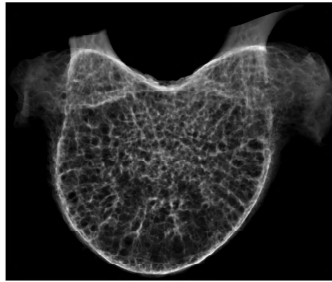
X-ray direction 3

Sample G 195

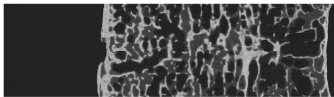
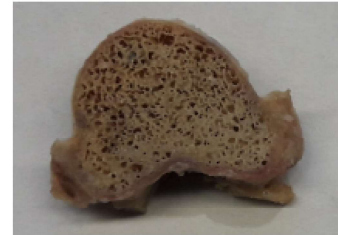Lesion type:



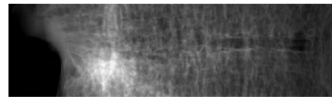
Midplane direction 1



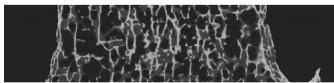
X-ray direction 1



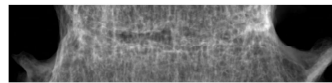
Midplane direction 2



X-ray direction 2



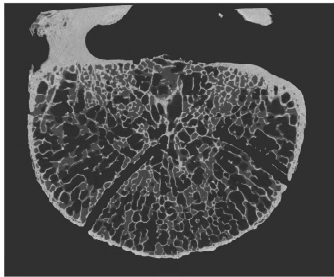
Midplane direction 3



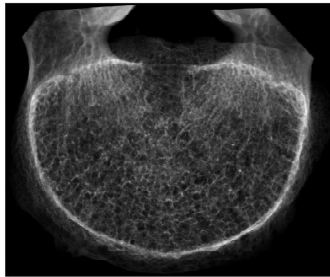
X-ray direction 3

Sample G 197

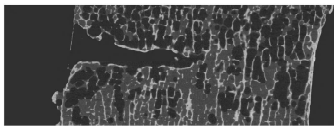
Lesion type:



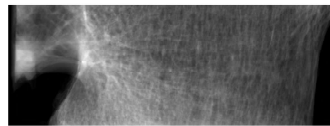
Midplane direction 1




X-ray direction 1



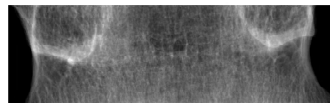
Midplane direction 2



X-ray direction 2



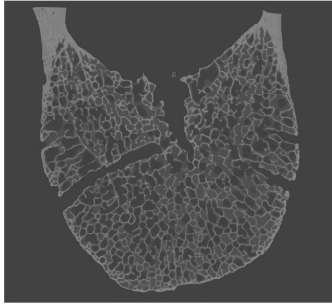
Midplane direction 3



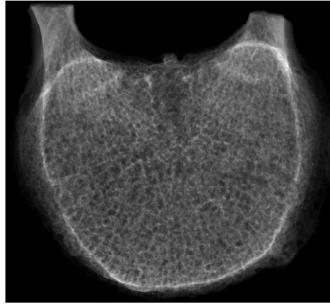
X-ray direction 3

Sample C 201

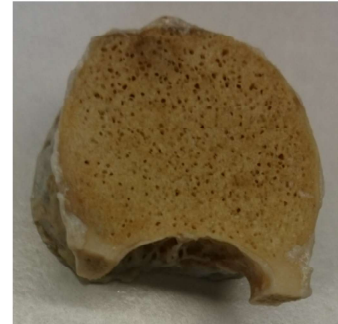
Lesion type:



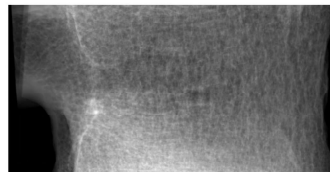
Midplane direction 1



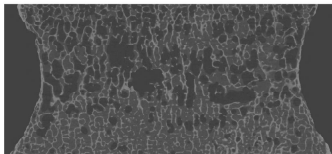
X-ray direction 1



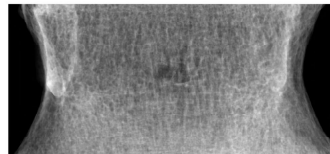
Midplane direction 2



X-ray direction 2



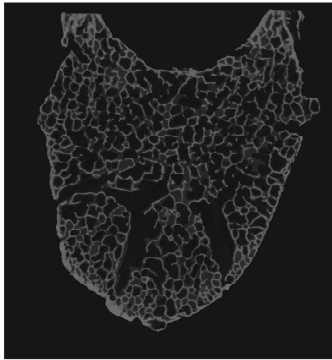
Midplane direction 3



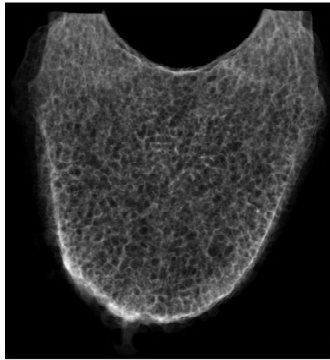
X-ray direction 3

Sample C 202

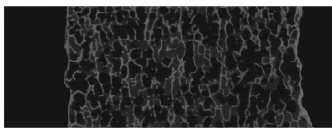
Lesion type:




Midplane direction 1




X-ray direction 1



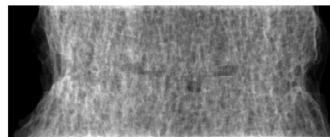
Midplane direction 2



X-ray direction 2



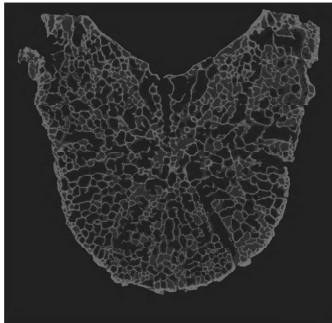
Midplane direction 3



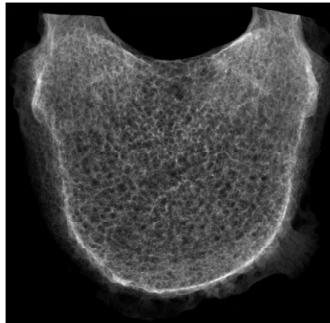
X-ray direction 3

Sample C 203

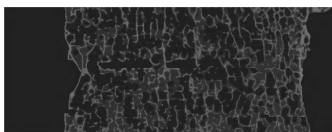
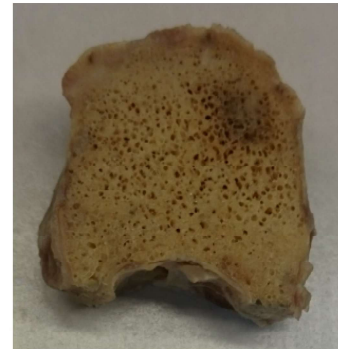Lesion type:




Midplane direction 1




X-ray direction 1



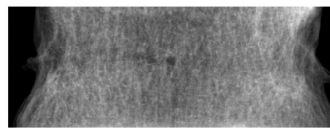
Midplane direction 2



X-ray direction 2



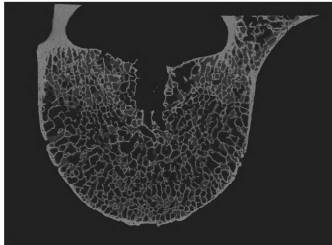
Midplane direction 3



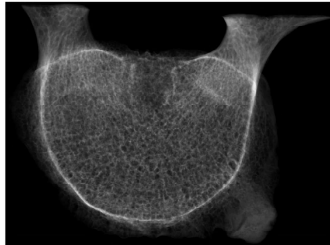X-ray direction 3

Sample C 207

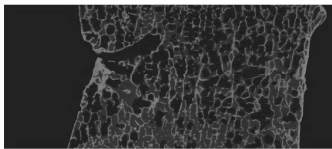
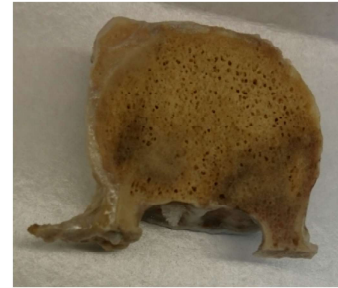
Lesion type:



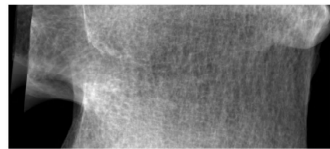
Midplane direction 1



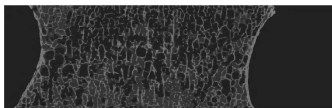
X-ray direction 1



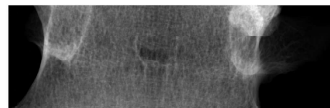
Midplane direction 2



X-ray direction 2



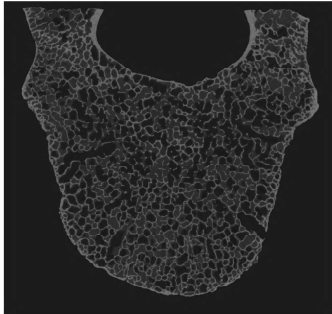
Midplane direction 3



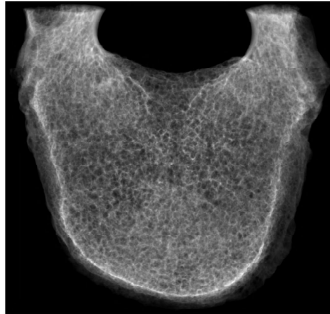
X-ray direction 3

Sample C 208

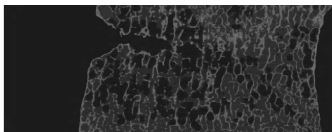
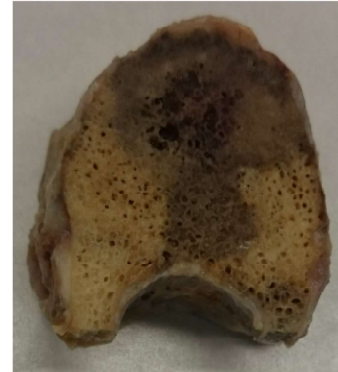
Lesion type:



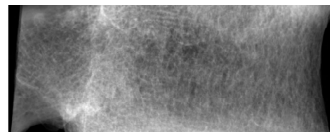
Midplane direction 1




X-ray direction 1




Midplane direction 2



X-ray direction 2



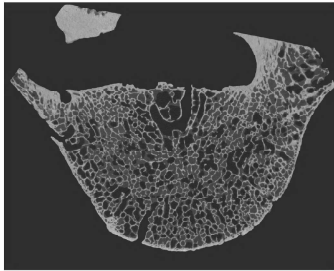
Midplane direction 3



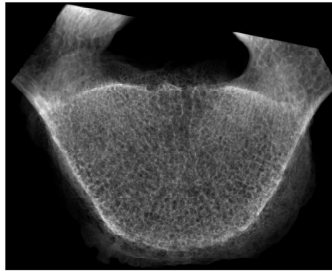
X-ray direction 3

Sample C 212

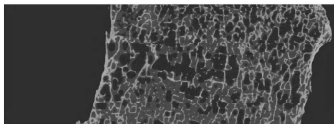
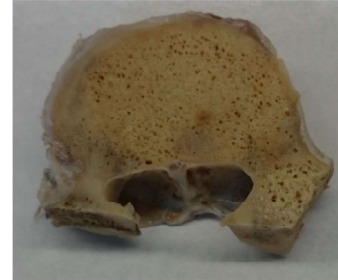Lesion type:



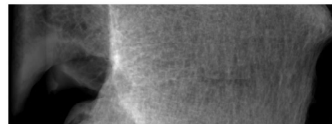
Midplane direction 1



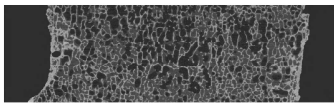
X-ray direction 1



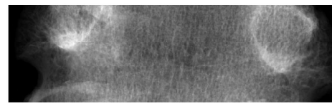
Midplane direction 2



X-ray direction 2



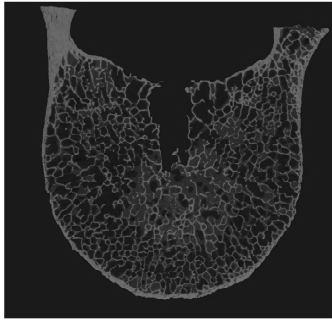
Midplane direction 3



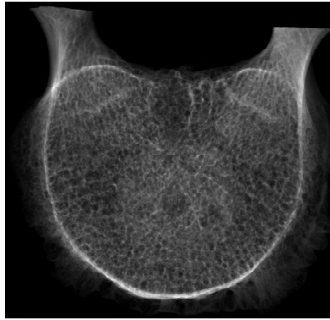
X-ray direction 3

Sample C 213


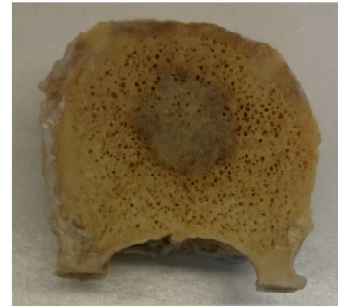
Lesion type:



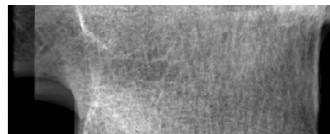
Midplane direction 1



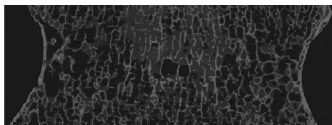
X-ray direction 1



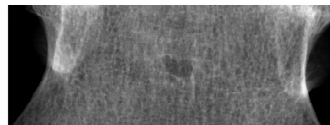
Midplane direction 2



X-ray direction 2



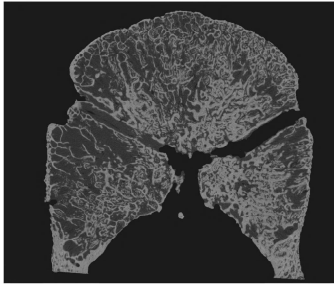
Midplane direction 3



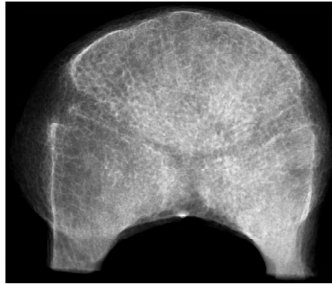
X-ray direction 3

Sample H 217

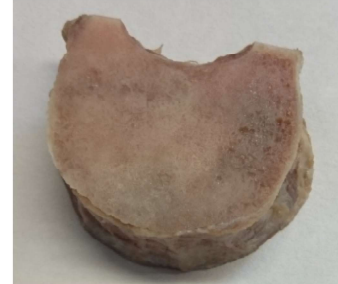
Lesion type:



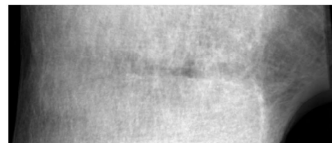
Midplane direction 1




X-ray direction 1



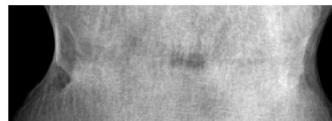
Midplane direction 2



X-ray direction 2



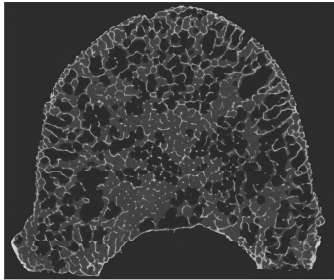
Midplane direction 3



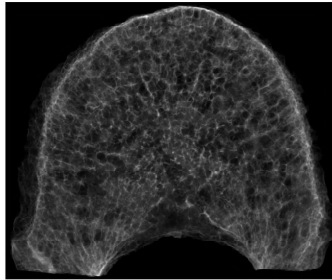
X-ray direction 3

Sample I 225

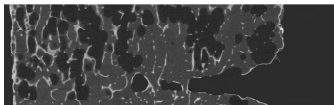
Lesion type:



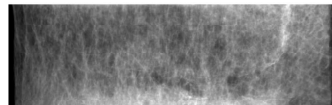
Midplane direction 1




X-ray direction 1



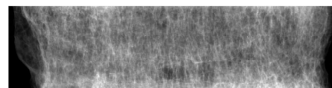
Midplane direction 2



X-ray direction 2



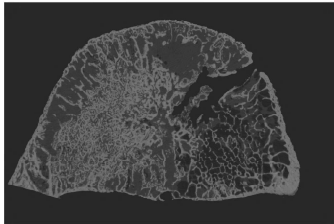
Midplane direction 3



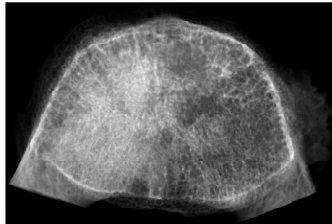
X-ray direction 3

Sample H 229


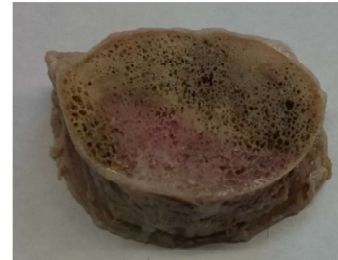
Lesion type:



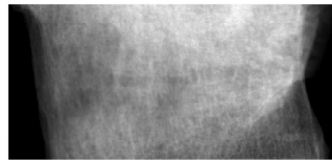
Midplane direction 1




X-ray direction 1



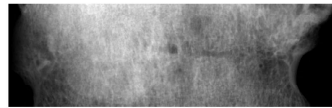
Midplane direction 2



X-ray direction 2



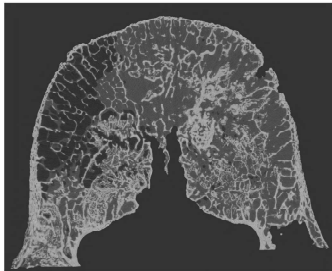
Midplane direction 3



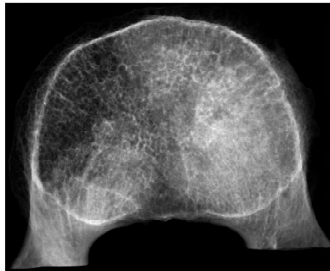
X-ray direction 3

Sample H 233

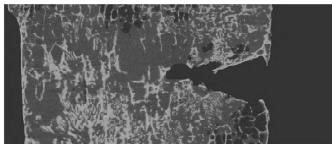
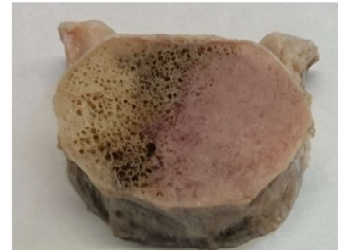Lesion type:



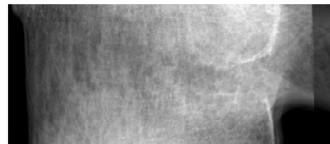
Midplane direction 1




X-ray direction 1



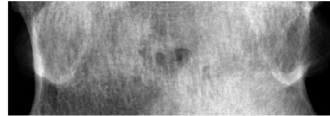
Midplane direction 2



X-ray direction 2



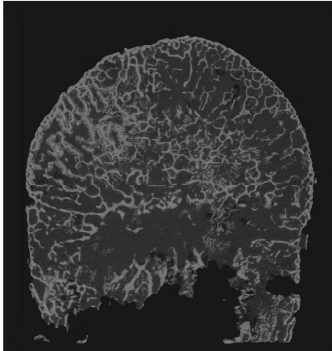
Midplane direction 3



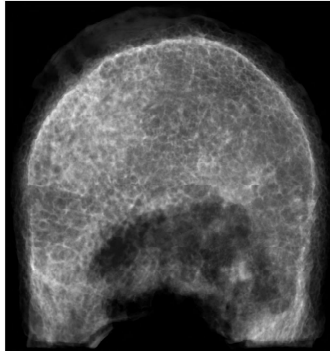
X-ray direction 3

Sample H 234

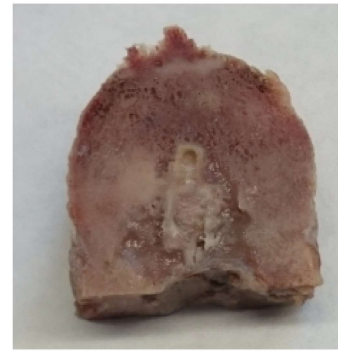
Lesion type:



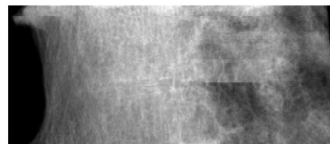
Midplane direction 1



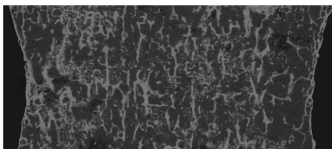
X-ray direction 1



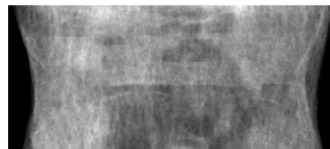
Midplane direction 2



X-ray direction 2



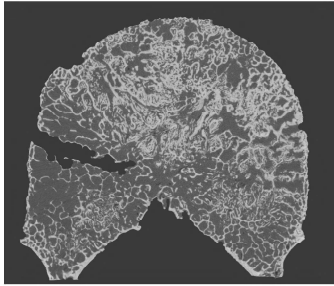
Midplane direction 3



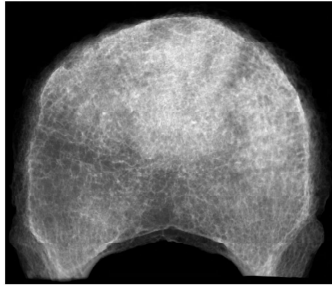
X-ray direction 3

Sample H 237

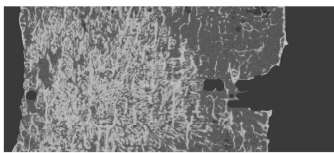
Lesion type:



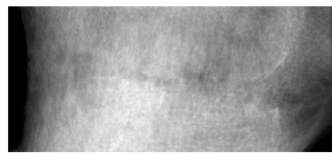
Midplane direction 1



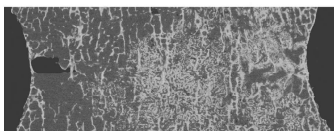
X-ray direction 1



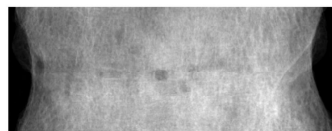Midplane direction 2



X-ray direction 2



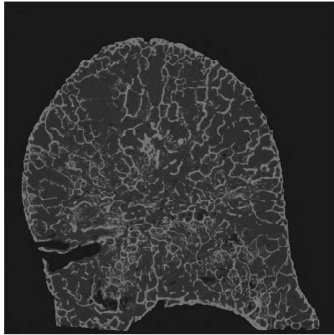
Midplane direction 3



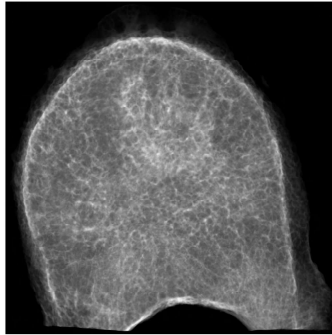
X-ray direction 3

Sample H 238

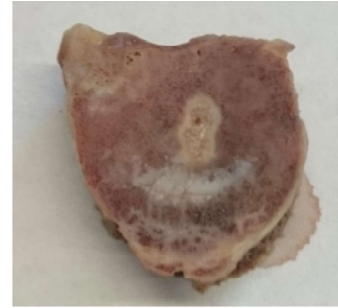
Lesion type:



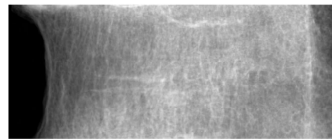
Midplane direction 1



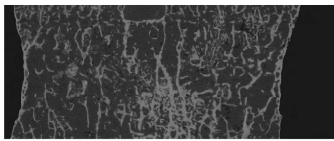
X-ray direction 1



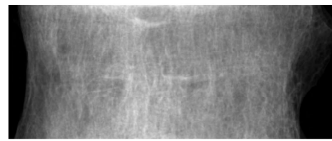
Midplane direction 2



X-ray direction 2



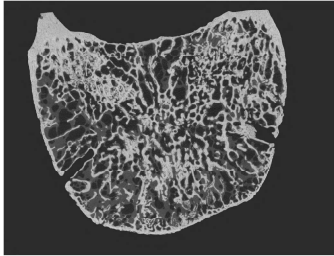
Midplane direction 3



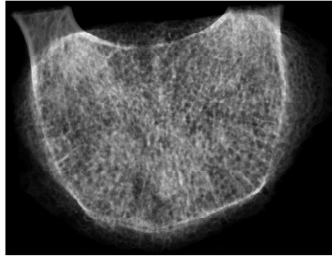
X-ray direction 3

Sample K 241


Lesion type:



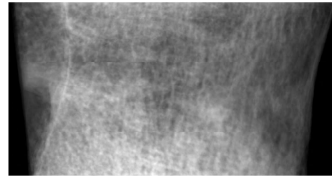
Midplane direction 1



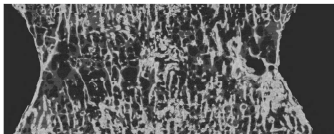
X-ray direction 1



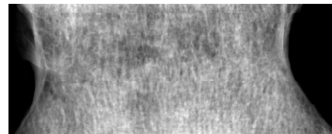
Midplane direction 2



X-ray direction 2



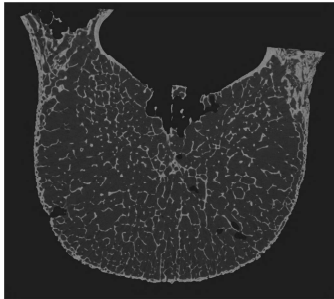
Midplane direction 3



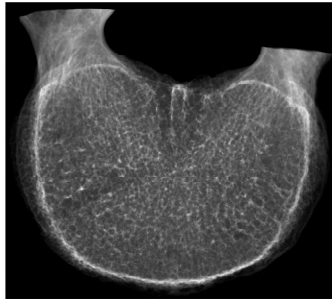X-ray direction 3

Sample F 245

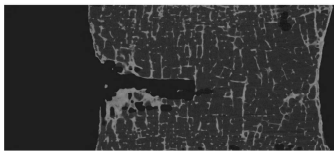
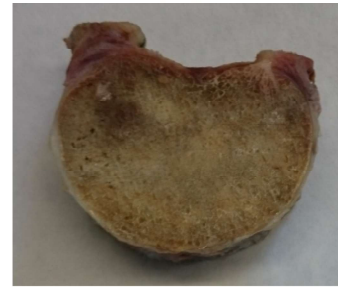Lesion type:



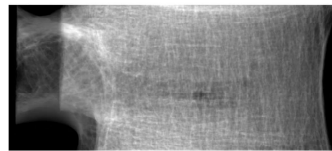
Midplane direction 1




X-ray direction 1



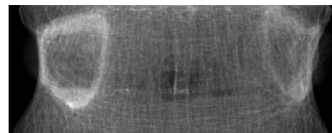
Midplane direction 2



X-ray direction 2



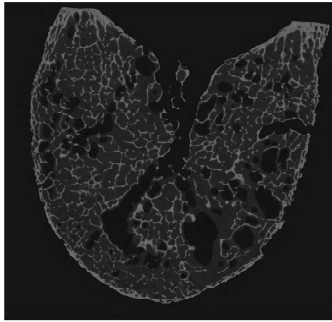
Midplane direction 3



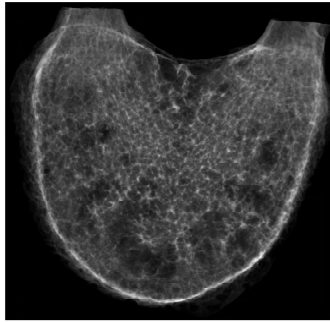
X-ray direction 3

Sample F 246

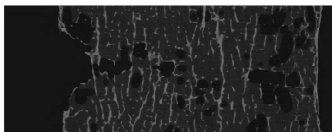
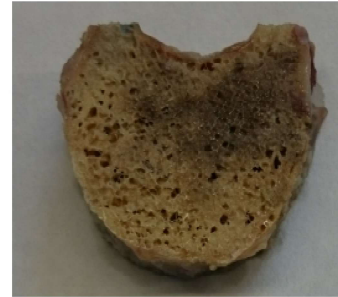Lesion type:



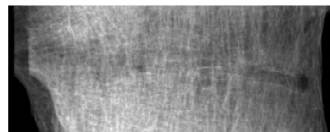
Midplane direction 1




X-ray direction 1



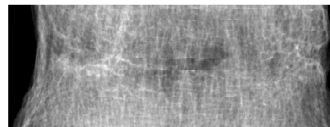
Midplane direction 2



X-ray direction 2



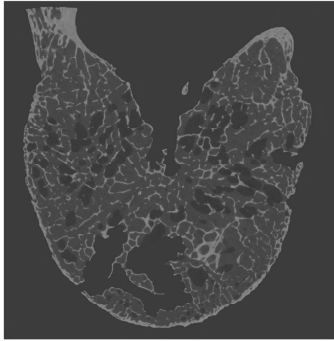
Midplane direction 3



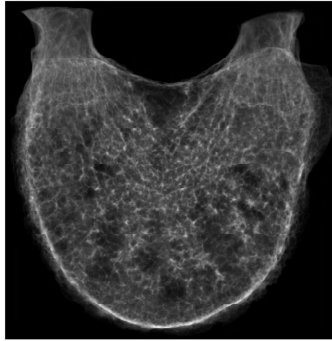
X-ray direction 3

Sample F 250

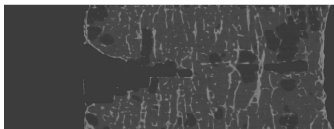
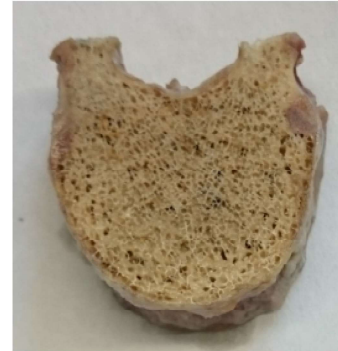Lesion type:



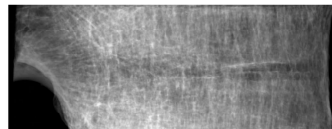
Midplane direction 1




X-ray direction 1



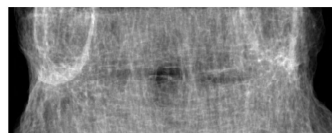
Midplane direction 2



X-ray direction 2



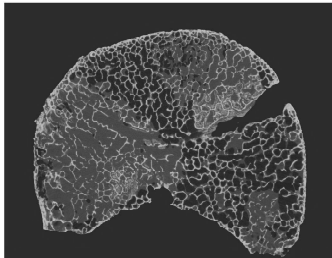
Midplane direction 3



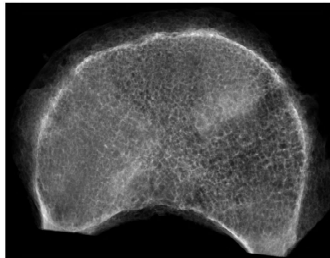
X-ray direction 3

Sample E 265


Lesion type:



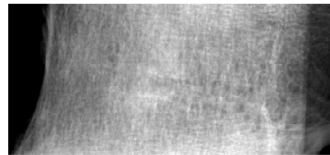
Midplane direction 1




X-ray direction 1



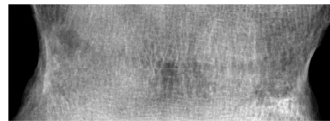
Midplane direction 2



X-ray direction 2



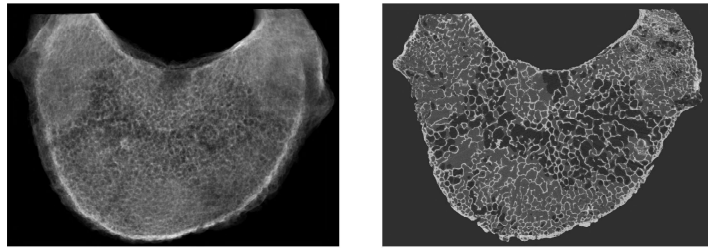
Midplane direction 3



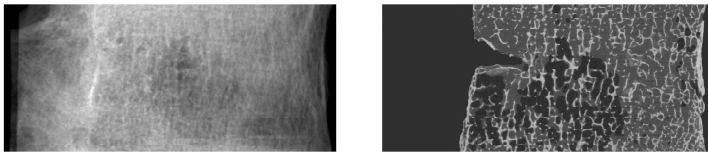
X-ray direction 3

Sample E 266

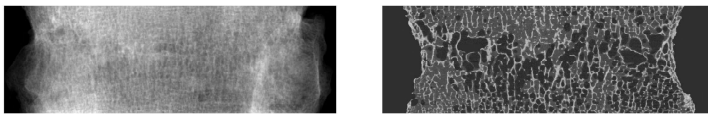
Lesion type:



Midplane direction 1



Midplane direction 2



Midplane direction 3

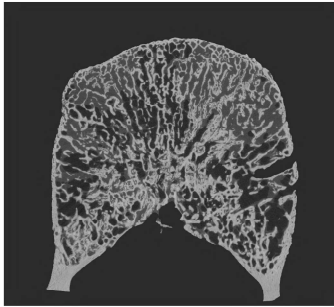
X-ray direction 3

X-ray direction 2

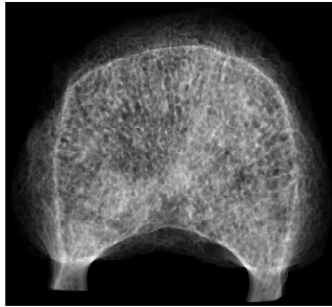
X-ray direction 1

Sample K 269


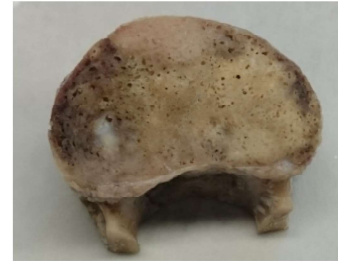
Lesion type:



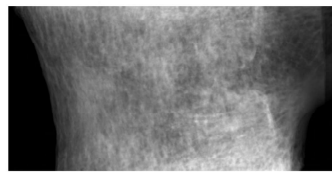
Midplane direction 1



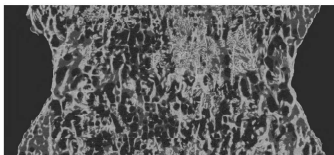
X-ray direction 1



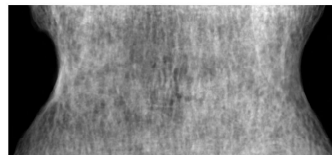
Midplane direction 2



X-ray direction 2



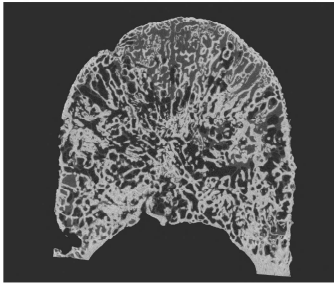
Midplane direction 3



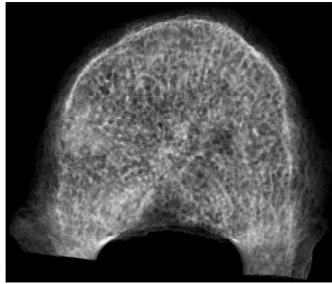
X-ray direction 3

Sample K 270

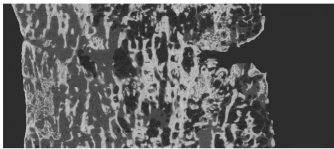
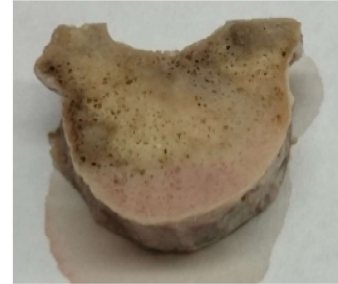Lesion type:



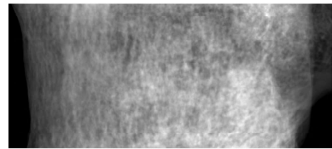
Midplane direction 1



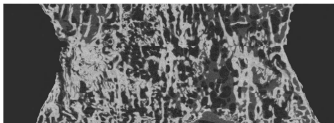
X-ray direction 1



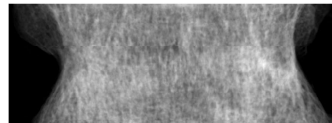
Midplane direction 2



X-ray direction 2



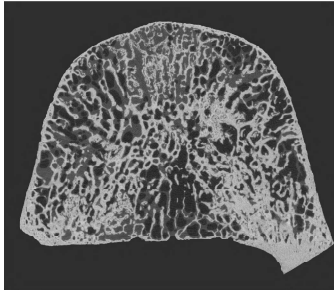
Midplane direction 3



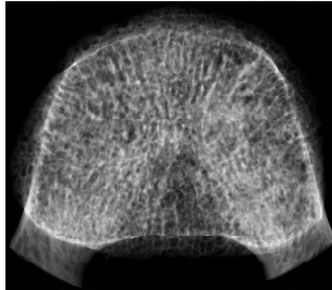
X-ray direction 3

Sample K 273


Lesion type:




Midplane direction 1



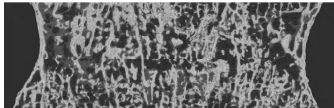
X-ray direction 1



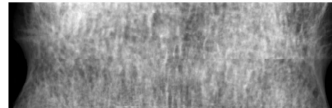
Midplane direction 2



X-ray direction 2



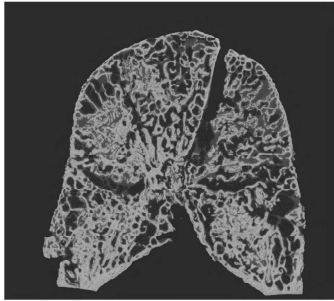
Midplane direction 3



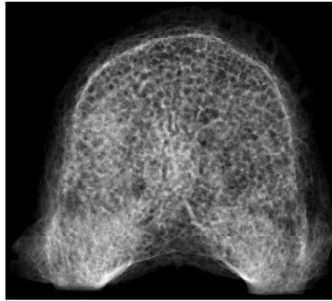
X-ray direction 3

Sample K 274

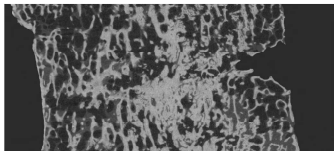
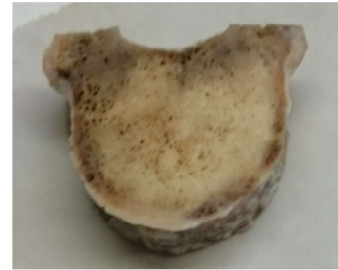Lesion type:



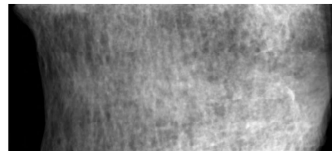
Midplane direction 1




X-ray direction 1



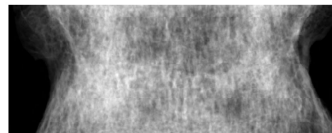
Midplane direction 2



X-ray direction 2



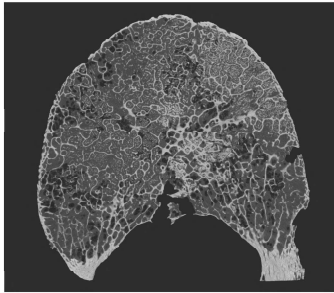
Midplane direction 3



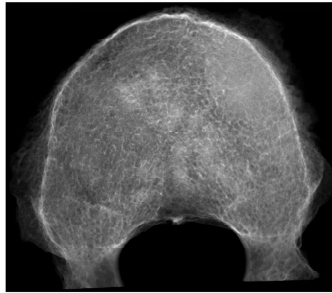
X-ray direction 3

Sample B 280


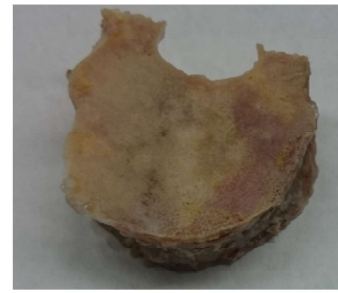
Lesion type:



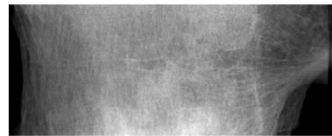
Midplane direction 1



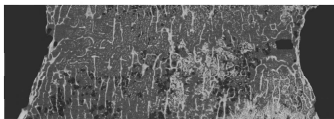
X-ray direction 1



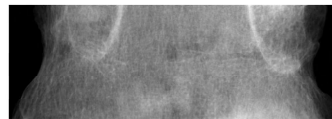
Midplane direction 2



X-ray direction 2



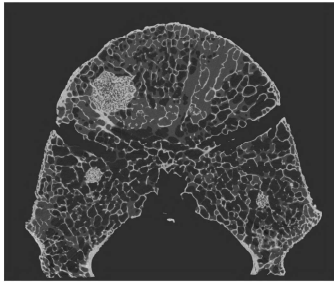
Midplane direction 3



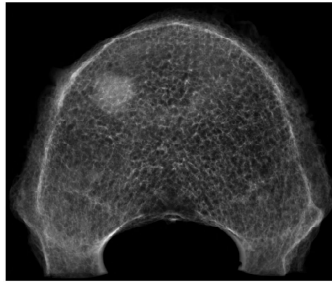
X-ray direction 3

Sample B 283

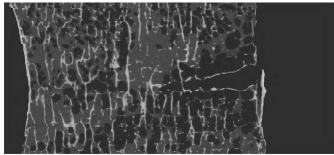
Lesion type:



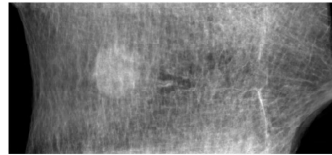
Midplane direction 1



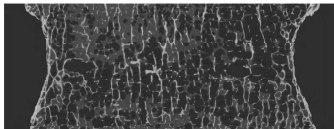
X-ray direction 1



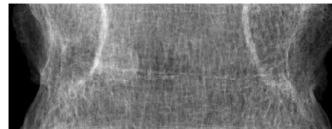
Midplane direction 2



X-ray direction 2



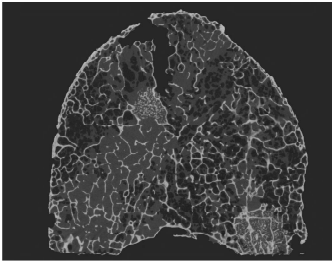
Midplane direction 3



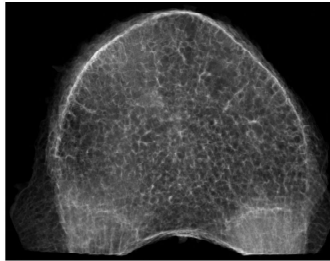
X-ray direction 3

Sample B 284

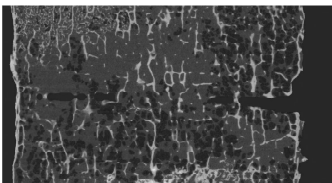
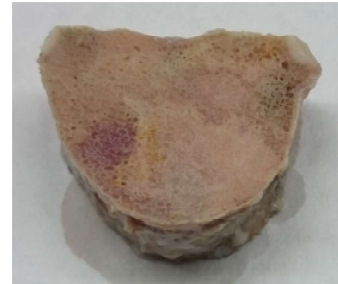Lesion type:



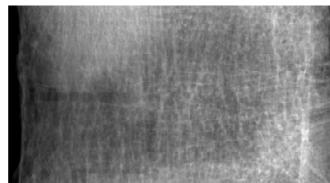
Midplane direction 1




X-ray direction 1



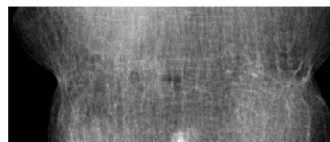
Midplane direction 2



X-ray direction 2



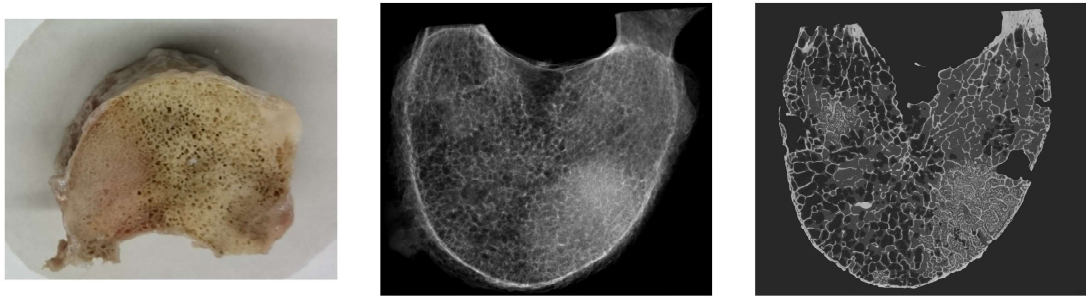
Midplane direction 3



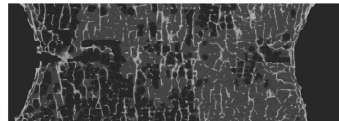
X-ray direction 3

Sample B 286

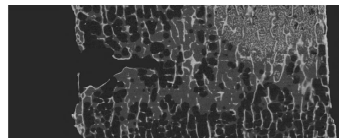
Lesion type:



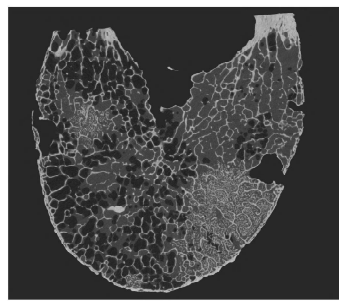
Midplane direction 3



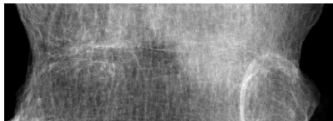
Midplane direction 2



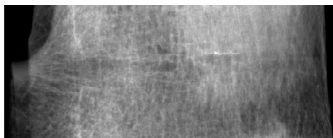
Midplane direction 1



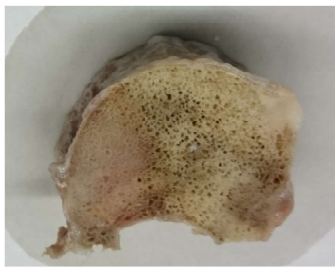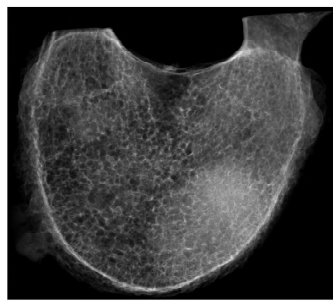
X-ray direction 3



X-ray direction 2

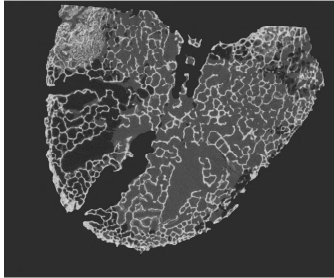


X-ray direction 1

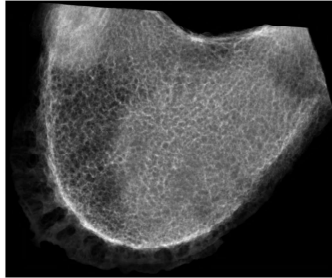


Sample E 290

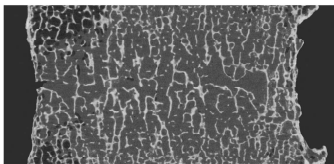

Lesion type:



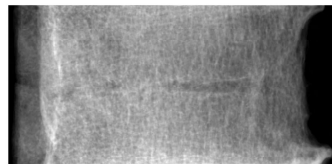
Midplane direction 1



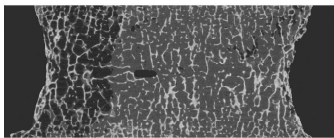
X-ray direction 1



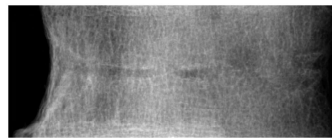
Midplane direction 2



X-ray direction 2



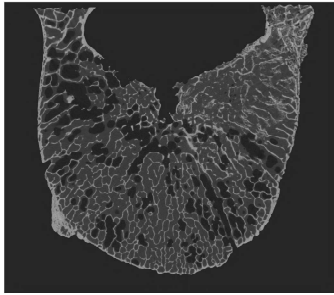
Midplane direction 3



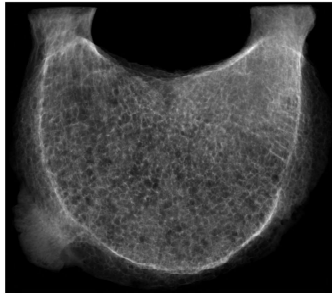
X-ray direction 3

Sample J 293


Lesion type:



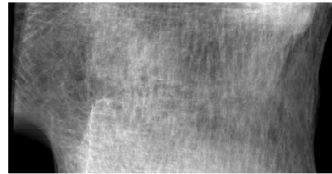
Midplane direction 1



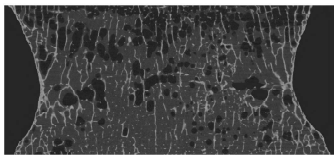
X-ray direction 1



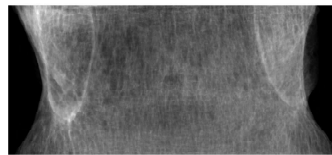
Midplane direction 2



X-ray direction 2



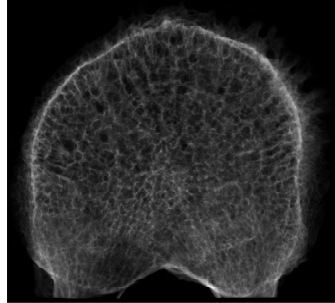
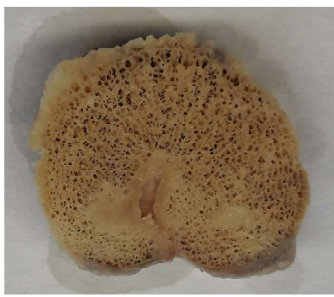Midplane direction 3



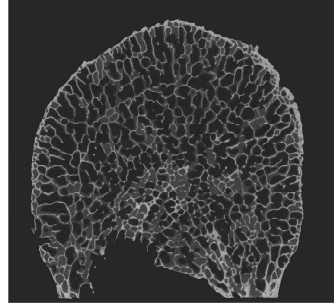
X-ray direction 3

Sample J 294

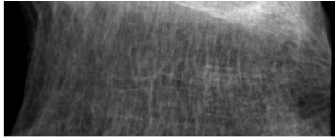
Lesion type:



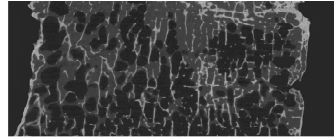
X-ray direction 1



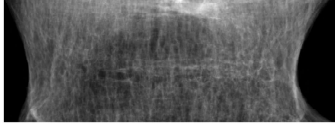
Midplane direction 1



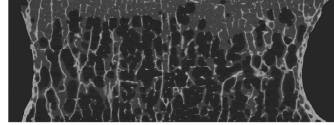
X-ray direction 2



Midplane direction 2



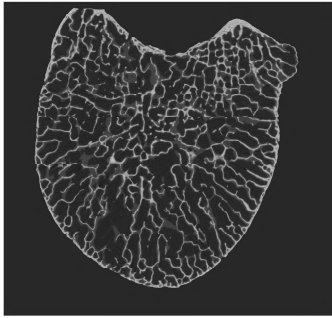
X-ray direction 3



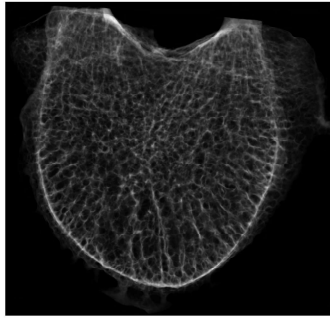
Midplane direction 3

Sample J 302

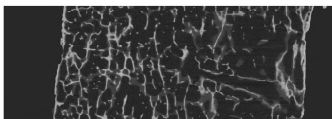
Lesion type:



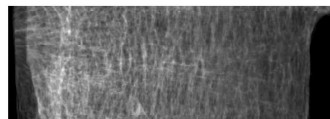
Midplane direction 1



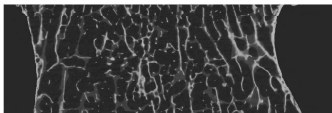
X-ray direction 1



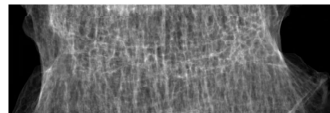
Midplane direction 2



X-ray direction 2



Midplane direction 3



X-ray direction 3