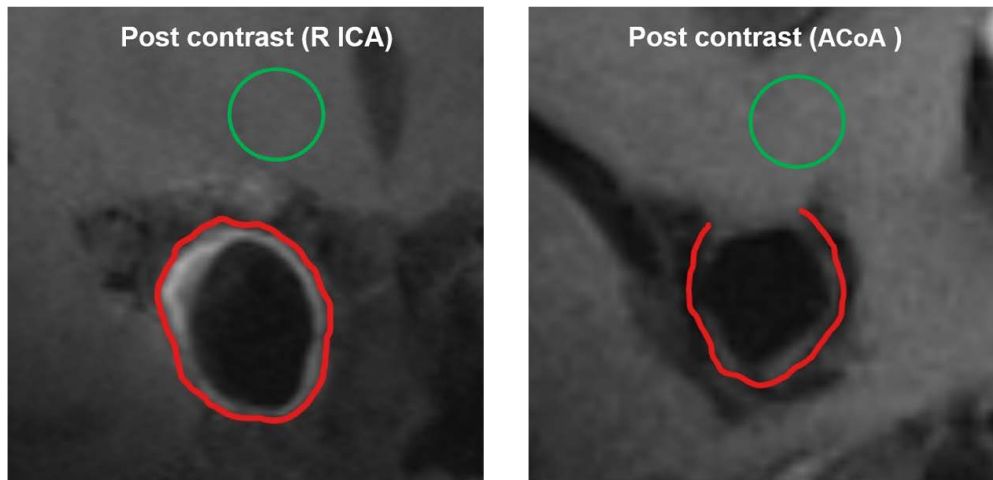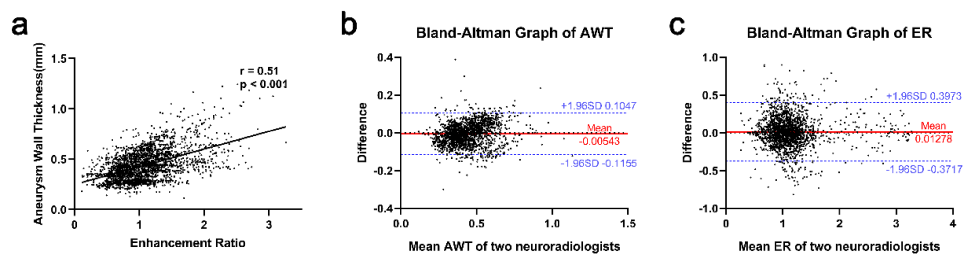


Supplementary Figure 1. Example of location and region of interest drawn on the white matter. Left, an internal carotid artery aneurysm. Right, an anterior communicating artery aneurysm. Green circle, the location and region on white matter to calculate SIbrain; Red contour, manually drawn aneurysm out-contour.



Supplementary Figure 2. (a) Correlation analysis of AWT and AWE. (b) Bland–Altman graph of AWT from two neuroradiologists. (c) Bland–Altman graph of ER from two neuroradiologists.