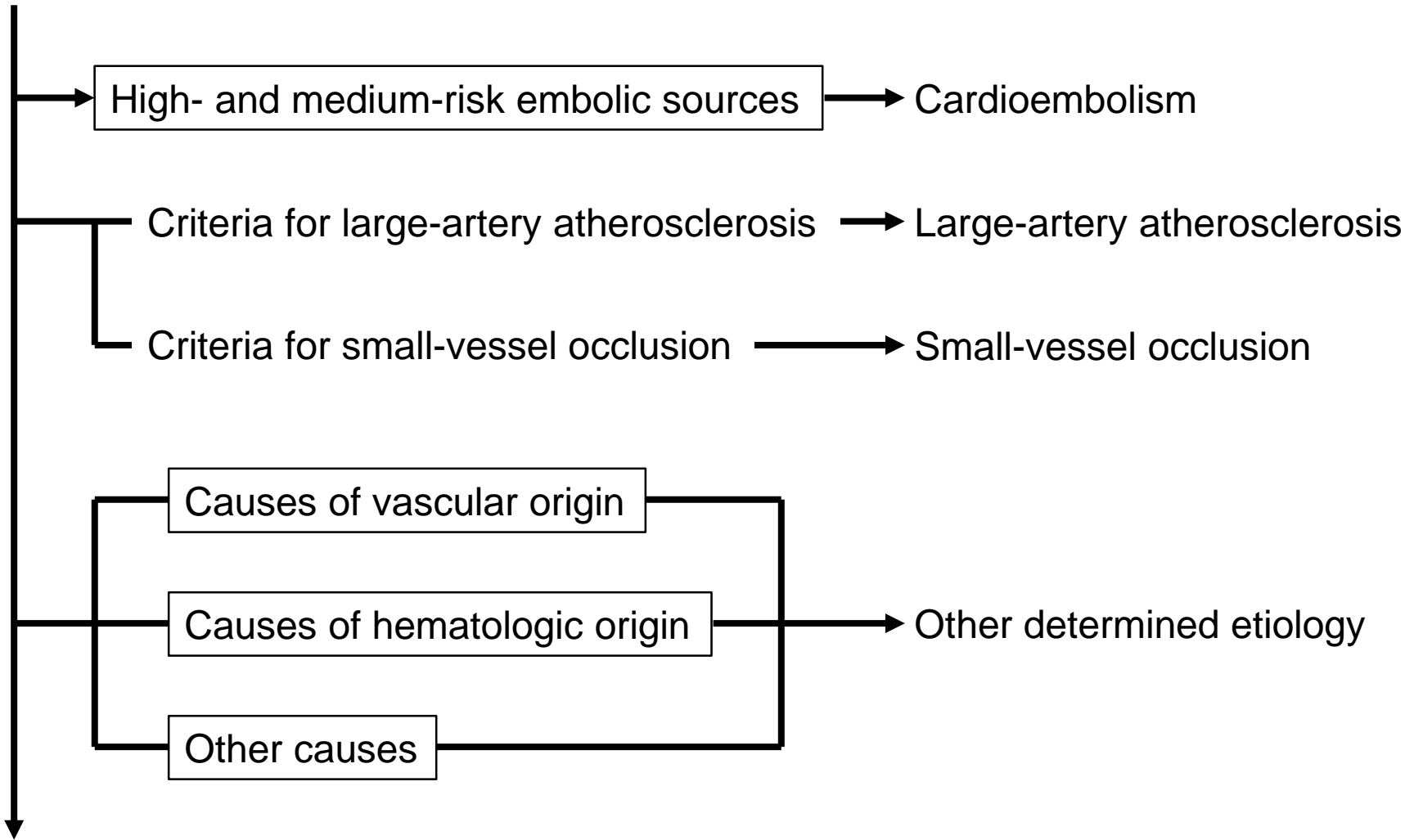


Acute ischemic stroke



Undetermined etiology