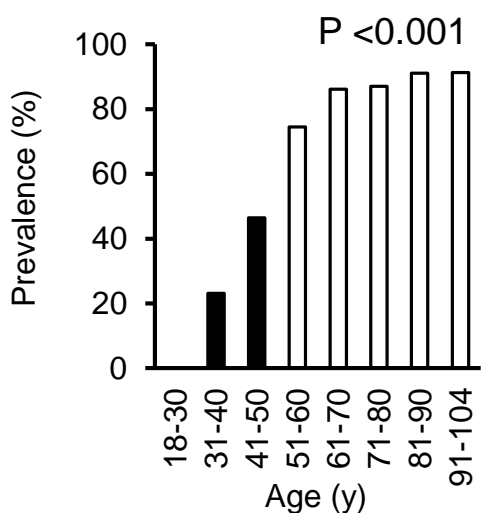
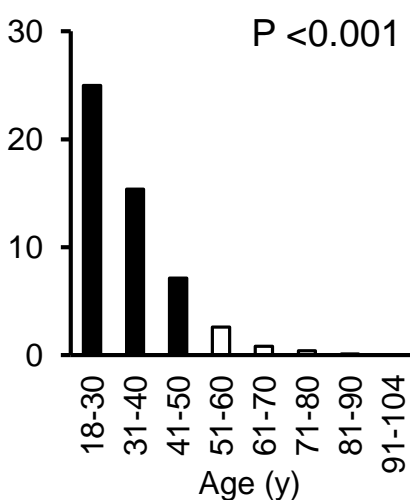


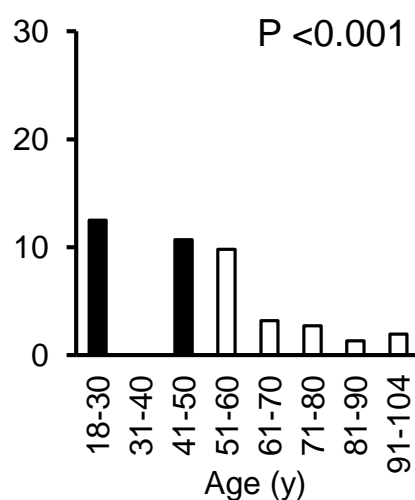
Atrial fibrillation



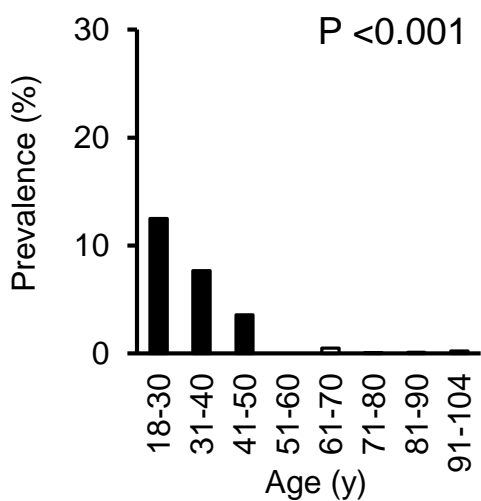
Dilated cardiomyopathy



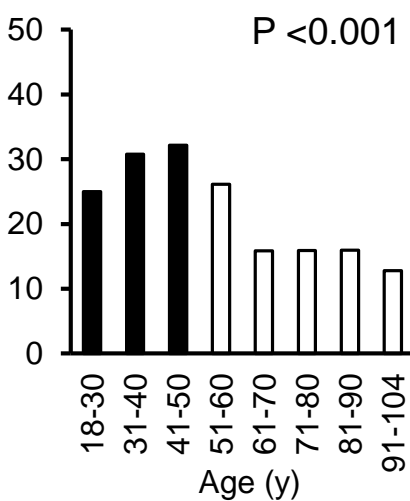
Intra-cardiac thrombus



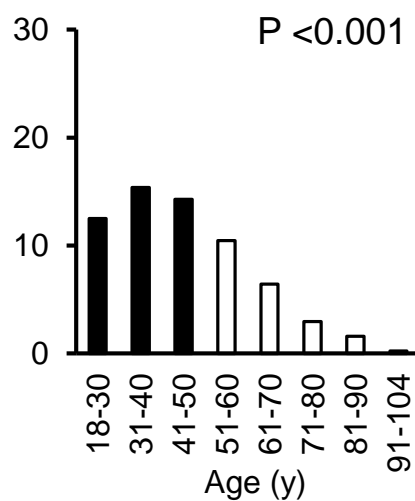
Atrial myxoma



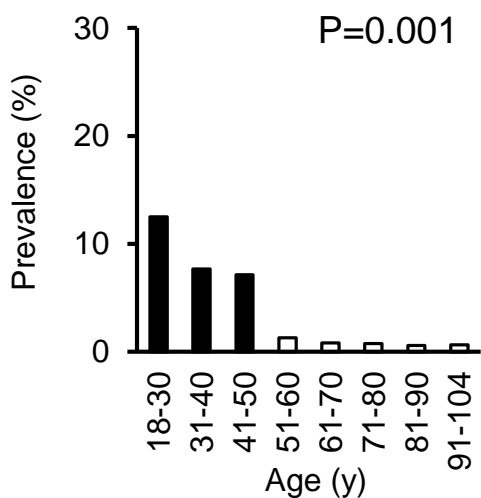
Left ventricular hypokinesis



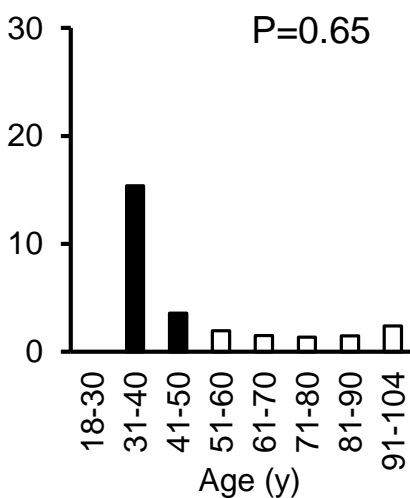
Patent foramen ovale



Nonbacterial thrombotic endocarditis



Congestive heart failure



Atrial septal defect

