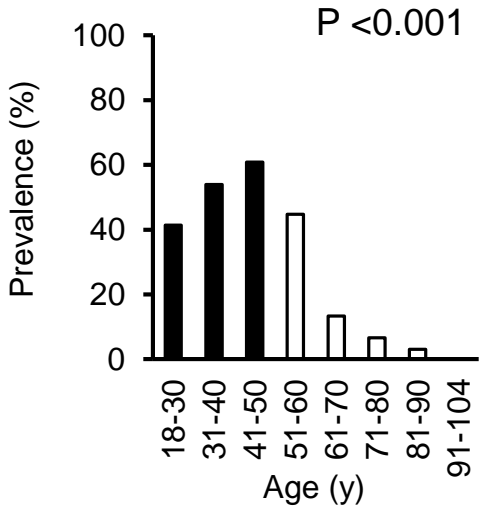
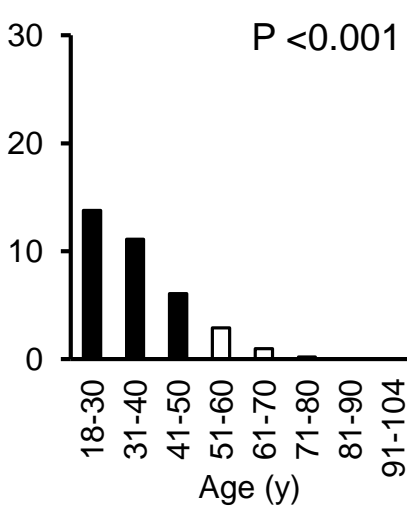


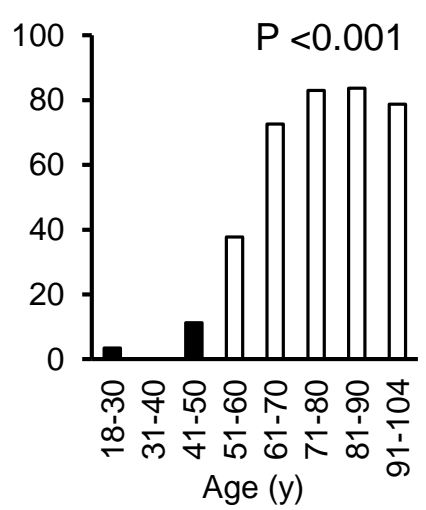
Arterial dissection



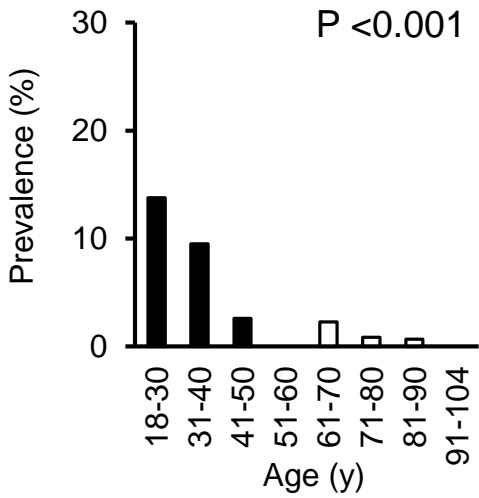
Moyamoya disease



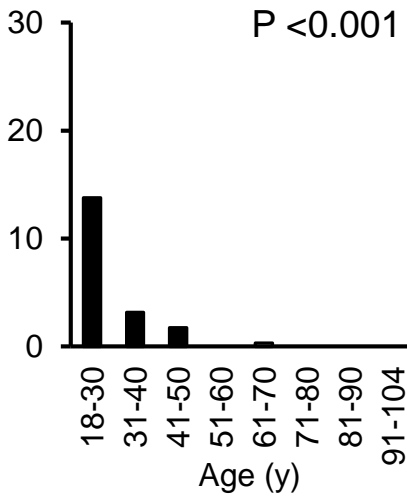
Aortic arch atherosclerotic plaques



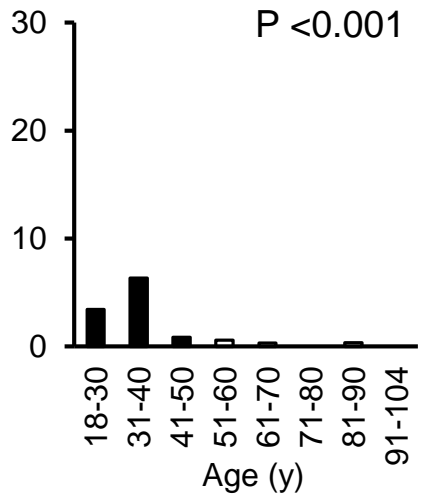
Cerebral venous thrombosis



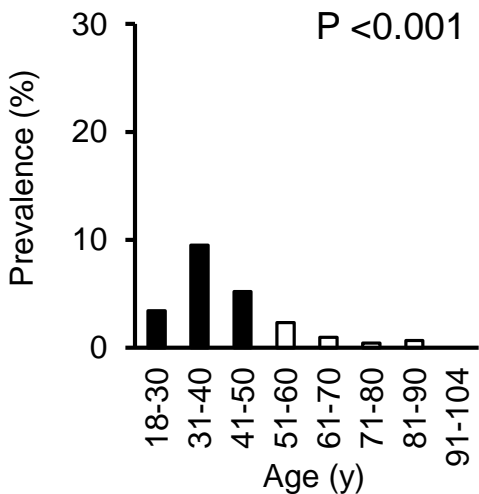
Reversible cerebral vasoconstriction syndrome



Other vascular causes



Antiphospholipid syndrome



Protein S deficiency

