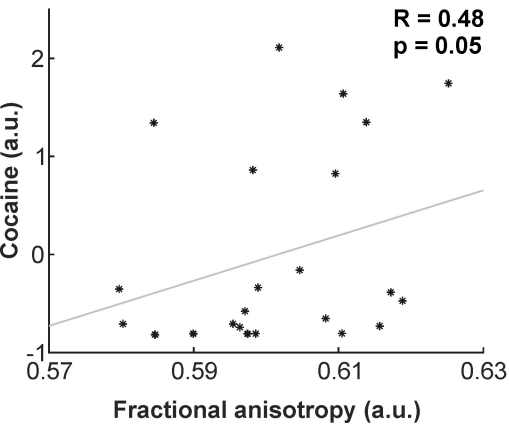
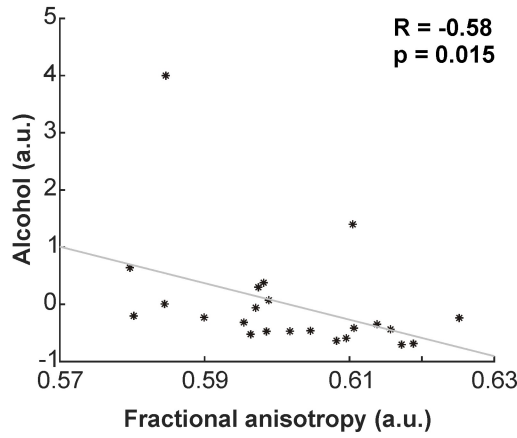


$p < 0.001$

Right posterior limb  
of internal capsule

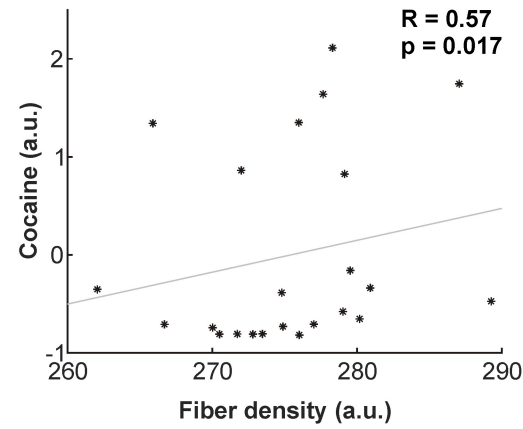


Right posterior limb  
of internal capsule

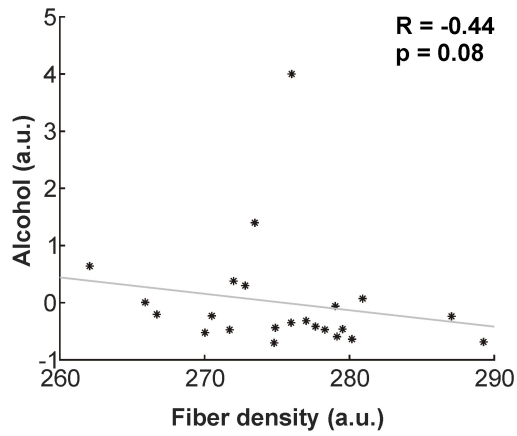


$p < 0.001$

Right posterior limb  
of internal capsule

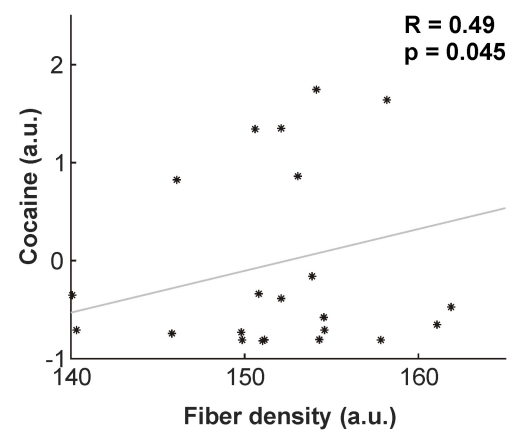


Right posterior limb  
of internal capsule

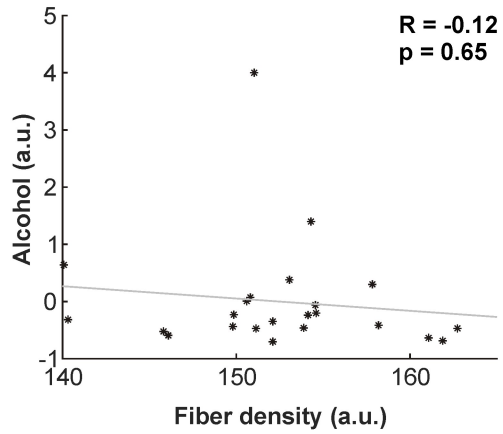


$p = 0.037$

Right cingulate gyrus

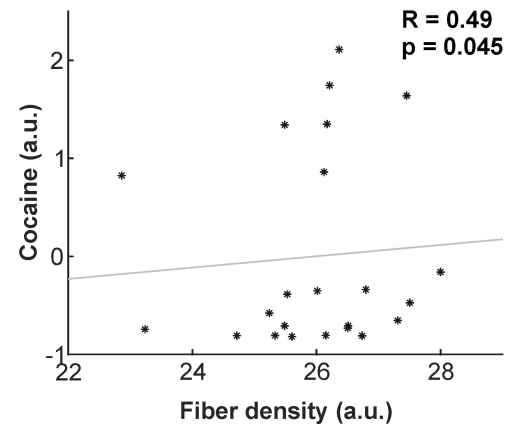


Right cingulate gyrus



$p = 0.048$

Left superior  
fronto-occipital fasciculus



Left superior  
fronto-occipital fasciculus

