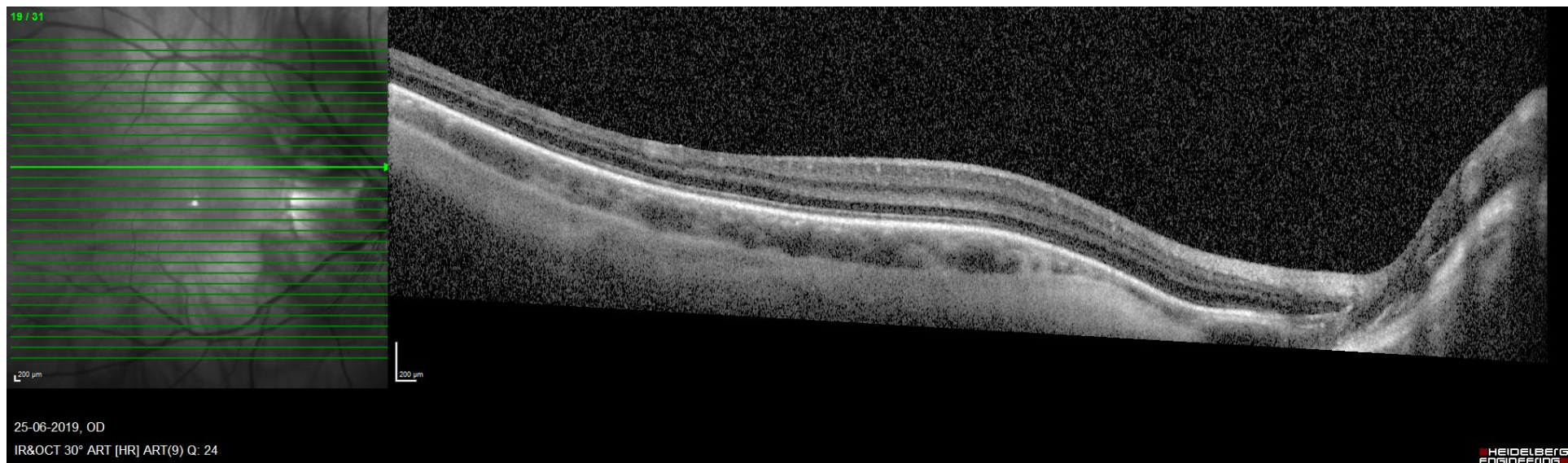


Supplementary figures



Supplemental Figure 1: OCT image of staphyloma of the proband of Family III.

