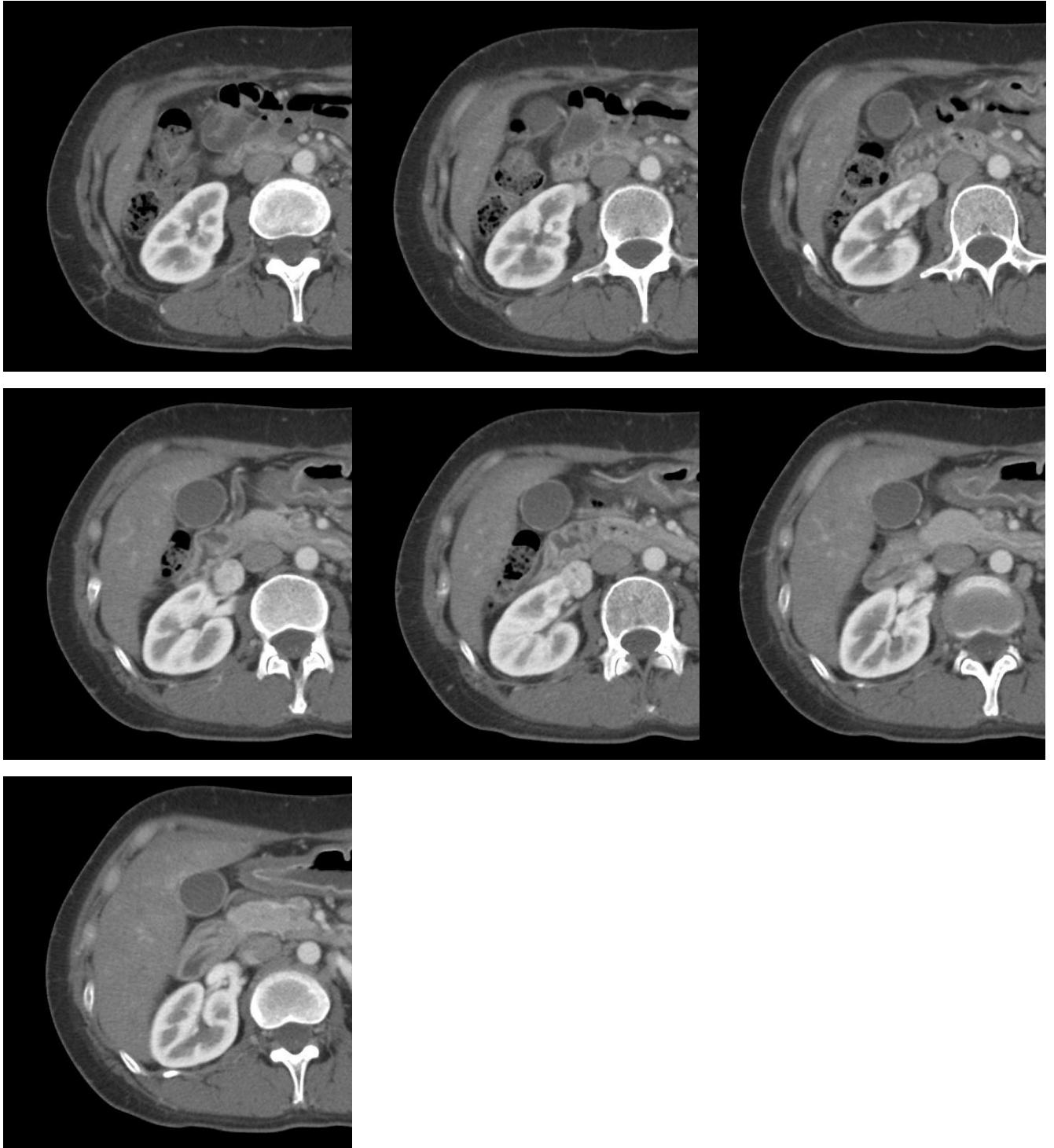


Supplementary Fig. 1 Representative images of AML showing the absence of CV on CECT



CVs could not be detected in AML.

AML, angiomyolipoma; CV, collateral vessel; CECT, contrast-enhanced computed tomography