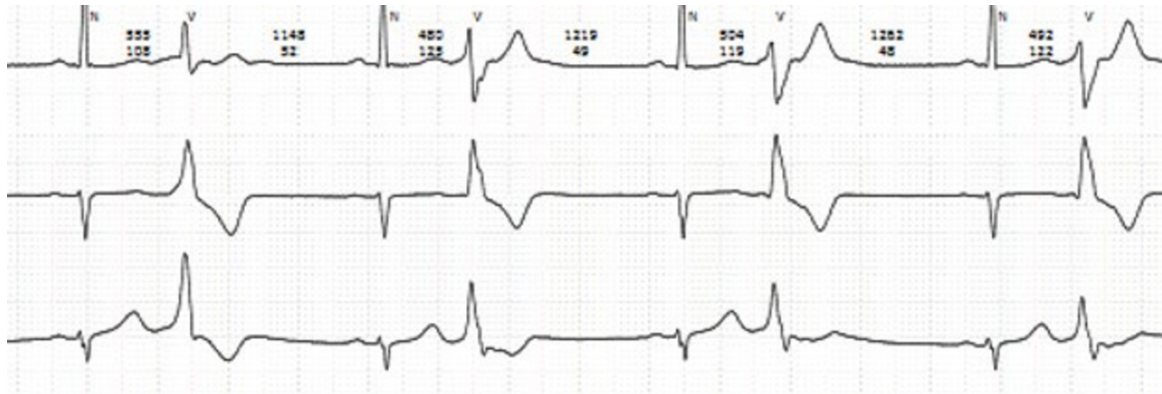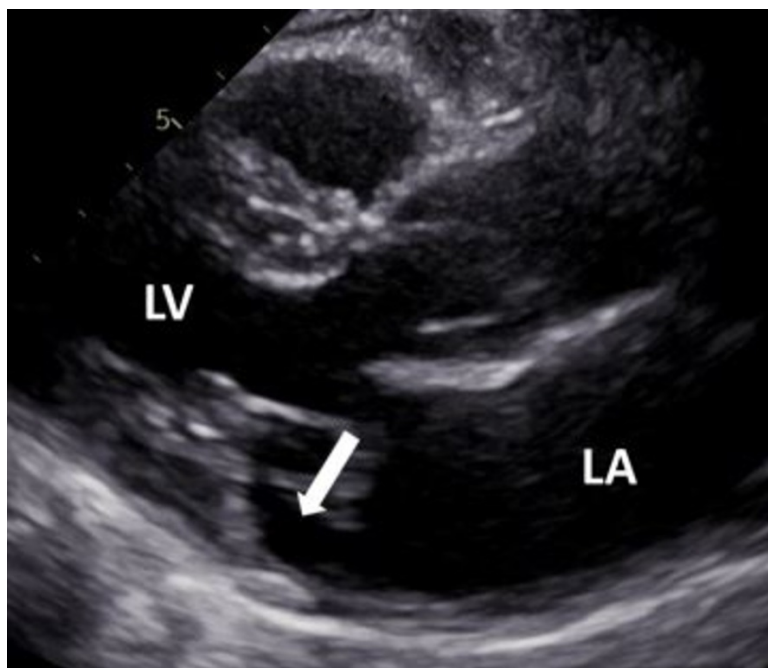


Supplemental Material

Supplementary Figure 1: Rhythm Holter with PVC Including Bigeminy.



Supplementary Figure 2: Parasternal Long Axis View Echocardiogram Displaying MAD in Systole.



Supplementary Figure 3: Zoomed Parasternal Long Axis View Echocardiogram Displaying MAD in Systole (Blue Line).

