

Figure S6

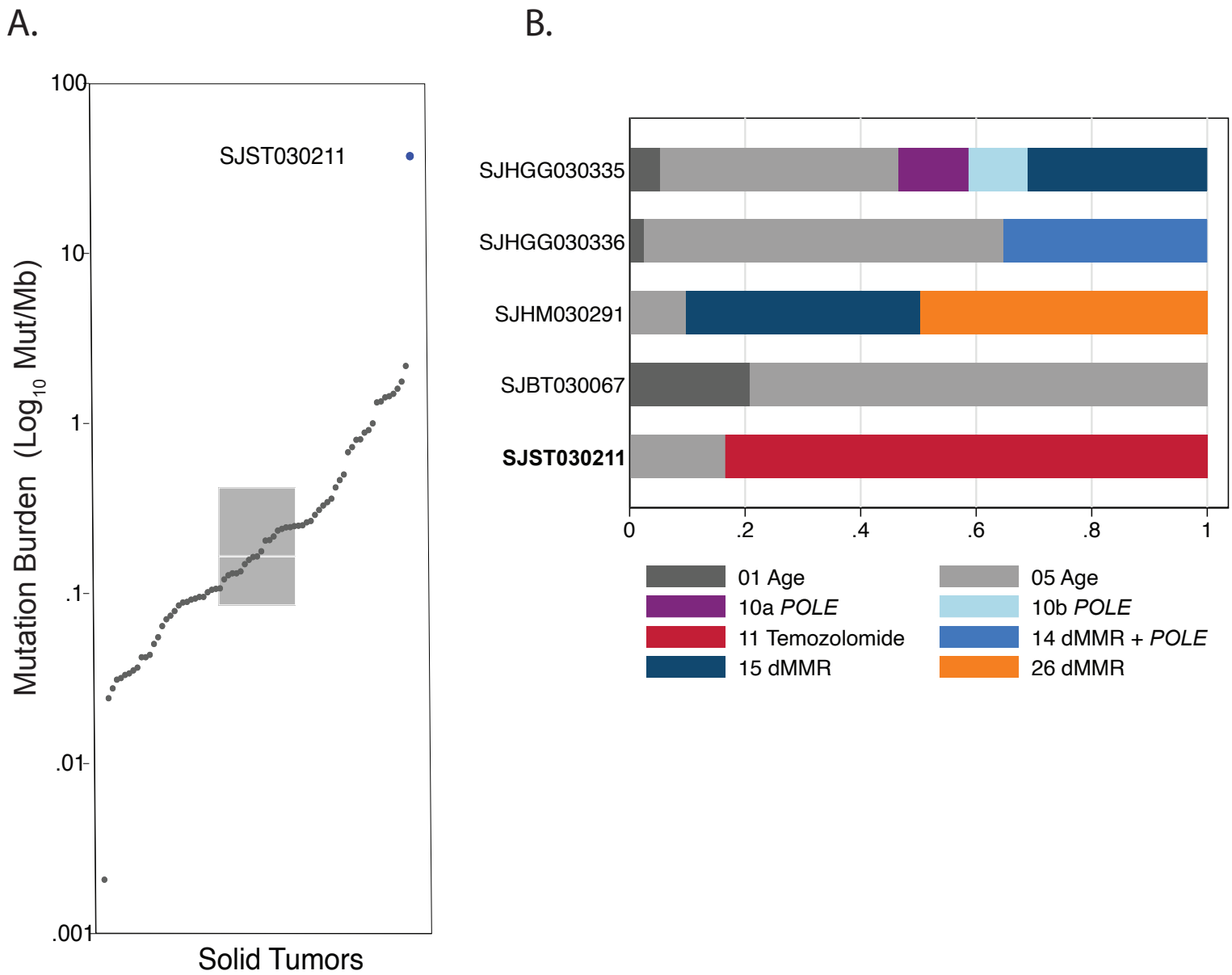


Figure S6. Hypermutation in a cutaneous squamous cell carcinoma. **A.** Plot of TMB of the solid tumors in the G4K cohort. Highest among them was the cutaneous squamous cell carcinoma in patient SJST030211. **B.** Mutation signatures of the hypermutated tumors in the G4K cohort. The DNA mutation signature of SJST030211 reveals a preponderance of mutations matching Signature 11, caused by prior treatment with Temozolomide.