

Online Supplementary material

1. Title

Pulmonary Alveolar Microlithiasis: review of the 1 022 cases reported worldwide.

2. Authors

Giuseppe Castellana, Giorgio Castellana, Mattia Gentile, Roberto Castellana, Onofrio Resta.

3. The content list:

- Figure E1: Distribution by age at diagnosis and sex of 904 cases of PAM for which both data were reported.
- Table E1: Relationships in familial cases belonging to 163 families (with references).
- Table E2: Cases of PAM with a slow clinical evolution and longest follow-up (with references).
- References for each paragraph other than the ones already listed in the manuscript

Figure E1: Distribution by age at diagnosis and sex of 904 cases of PAM for which both data were reported.

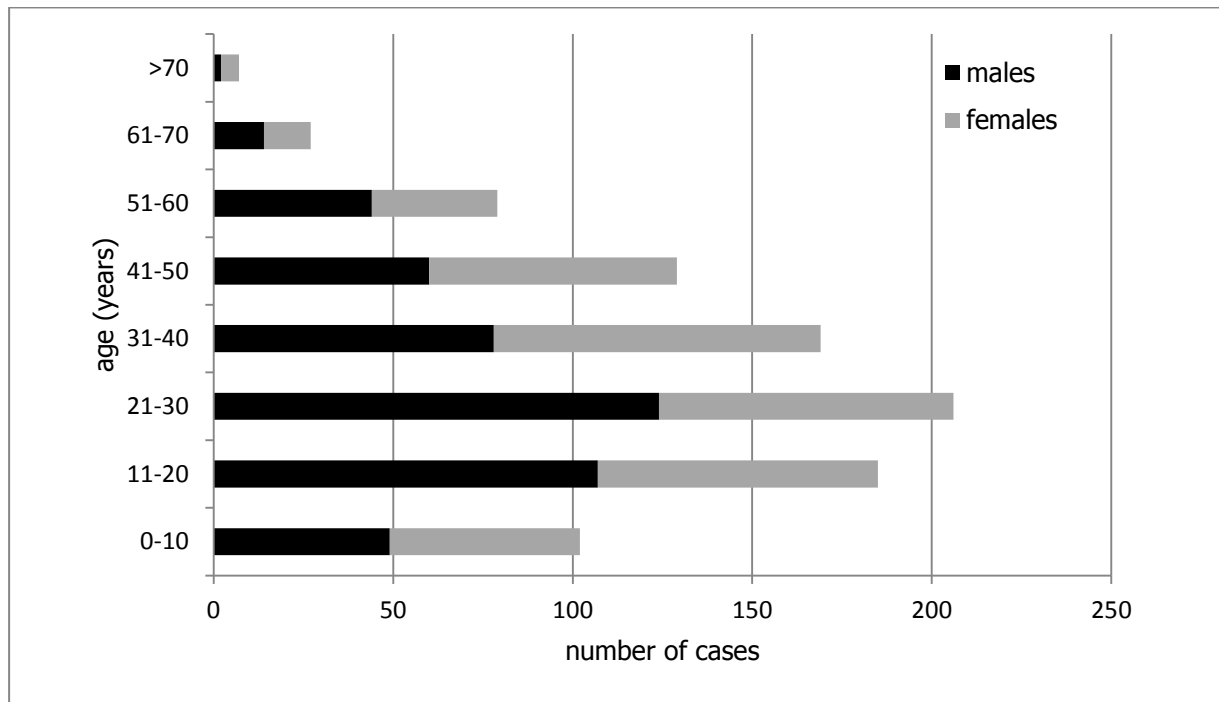


Table E1: relationships in familial cases belonging to 163 families (with references).

Familial relationship	Reporting frequency	Reference
2 brothers	24	FA1-23
2 sisters	14	FA7,24-36
Brother and sister	44	FA7,28,37-77
2 siblings	11	FA78,79
3 siblings	4	FA1,78,80
4 siblings	1	FA78
2 brothers and 1 sister	9	FA28,45,74,81-86
Brother and 2 sisters	7	FA1,26,51,87-90
3 brothers	3	FA91-93
3 sisters	3	FA94-96
3 brothers and sister	1	FA97
3 sisters and brother	1	FA98
4 sisters	2	FA1,99
Brother and 4 sisters	1	FA100
5 sisters	1	FA101
2 sister and mother	1	FA102
Sister, brother and his daughter	1	FA103
2 Cousins (M,F)	1	FA104
Niece and her uncle	1	FA105
Boy, the maternal aunt, and 1 son of the brother of the maternal grandmother	1	FA106
Brother, 2 sisters and the daughter of one of them	1	FA107

Group of 6 persons: 2 sisters, 3 sons (2Fe 1M) of one of them and 1 st nephew of the husband of the same sister	1	FA101,108
Group of 6 persons: 2 brothers and 3 brothers (first cousins) and their uncle	1	FA109
Not specified (58 patients)	29 groups	FA110

References:

- FA1. Sosman MC, Dodd GD, Jones WD, Pillmore GU. The familial occurrence of pulmonary alveolar microlithiasis. *Am J Roentgenol* 1957;77:947-1012.
- FA2. Abdel-Akim M, El Mallah S, Hashem M Abdel-Hakim S. Pulmonary alveolar microlithiasis. *Thorax* 1959;14:263-266.
- FA3. Tatti V, Riniker P. Diffuse a familial pulmonary alveolar microlithiasis. *Helv Med Acta* 1962;29:611-613.
- FA4. Doehnert HR, Gómez López L. Microlitiasis alveolar pulmonar. *Revista de Tisiologia y Neumonologia* 1963;5:63.
- FA5. Caffrey PR, Altman RS. Pulmonary alveolar microlithiasis occurring in premature twins. *J Pediatr* 1965;66:758-763.
- FA6. Burguet W, Reginster A. L'hérédité de la microlithiase alvéolaire pulmonaire. A propos d'une nouvelle observation familiale. *Annales de Génétique* 1967; 10:75-81.
- FA7. Okuno K, Chihaya M, Kumakoto S, Fujii S, Hayakawa T. Two familial cases of microlithiasis alveolaris pulmonum. *Runsho Hoshu* 1967;2:44-50.
- FA8. Balikian JP, Fuleihan CN, Nucho CN. Pulmonary alveolar microlithiasis. Report of five cases with special reference to roentgen manifestations. *Am J Roentgenol Radium Ther Nucl Med* 1968;103:509-518. (2 groups)
- FA9. Morandi D. Microlithiasis alveolaris pulmonum. *Respiration* 1968;25:184-199.

- FA10. Rao CS, Rao YM, Reddy DB, Sarada D. Pulmonary alveolar microlithiasis. *J Indian Med Assoc* 1968;50:427-428.
- FA11. Al Damluji SF, al-Omari MM, al-Fakhri S. Pulmonary Alveolar Microlithiasis in two siblings from Iraq. *Br J Dis Chest* 1973;67:246-252.
- FA12. Aliperta A, Mauro G, Saviano S, Bellissimo U, Perna A, Martufi S. Proteinosi alveolare, pneumopatia a corpi amilacei e microlitiasi polmonare: contributo istopatologico. *Arch Mon Mal Tor* 1976;31:87-118.
- FA13. Garty I, Giladi N, Flatau E. Bone scintigraphy in two siblings with pulmonary alveolar microlithiasis. *Br J Radiol* 1985;58:763-766.
- FA14. Radosavljevic G, Rebic P, Mandaric D. Microlithiase Alvéolaire poulmonaire chez 2 frères. *Rev Pneumol Clin* 1988;44:201-204.
- FA15. Schmidt H, Lorcher U, Kitz R, Zielen S, Ahrens P, König R. Pulmonary alveolar microlithiasis in children. *Pediatr Radiol* 1996;26:33-36.
- FA16. Da Silva Figueiredo S, Vilela Ribeiro LH, da Nóbrega BB, Santos Teixeira KIS, Brasil Leite MS, Oliveira AA. Microlitíase alveolar pulmonar em gêmeos univitelinos - relato de dois casos. *Radiol Bras* 2002;35:239-242.
- FA17. Kirova G, Sergieva S, Palaveev K, Vlassov V, Veleva I. Pulmonary alveolar microlithiasis associated with hypertrophic osteoarthropathy - CT and scintigraphic presentations in two siblings. *European Journal of Radiology Extra* 2004;51:31-35.
- FA18. Emektar A, Basekim CC, Silit E, Mutlu H, Kizilkaya E. Pulmonary alveolar microlithiasis in two brothers. *JBR-BTR* 2005;88:130-131.
- FA19. Okutan O, Kartaloğlu Z, İlvan A, Bozkanat E, Demirer E, Şilit E, Yildirim Ş, Narin Y. Yeni Tani Konulmuş Ailesel Alveoler Mikrolitiazis (İki Erkek Kardeş Olgu Sonumu). *Toraks Dergisi* 2007;8:127-129.

- FA20. Yetkin O. Pulmonary alveolar microlithiasis: a rare cause of severe pulmonary hypertension. *International Journal of Cardiology* 2007;118:133-134.
- FA21. Saleem A, Chaudhary A, Iqbal ZH. Pulmonary Alveolar Microlithiasis. *J College Physicians Surgeons Pakistan* 2009;19:391-392.
- FA22. Qiu H, Wei G, Zhang Q, Yu X, Meng F. Pulmonary alveolar microlithiasis: presentation of three cases. *Chin J Clinicians* 2011;5:3391-3394.
- FA23. Al-Sardar H, Al-Habbo DJ, Al-Hayali RM. Pulmonary alveolar microlithiasis: report of two brothers with the same illness and review of literature. *BMJ Case Rep* 2014. doi:10.1136/bcr-2013-201300.
- FA24. Waters HM. Microlithiasis alveolaris pulmonum. *Tubercle* 1960;41:276-278.
- FA25. Sanz Martín F, Culebras A, Antón T, Oliva H, Romeo Orbezogo JM. Microlithiasis alveolar pulmonar: revision de la literatura a proposito de dos nuevos casos. *Rev Clín Esp* 1964;5:277-284.
- FA26. López-Areal L, Zumárraga R, Gil-Turner C, Martín Granizo IF, Vara Cuadrado F, Duque Fraile J. Microlitiasis alveolar pulmonar familiar e infantil. *Rev Clin Esp* 1965;97:389-395.
- FA27. Vidinel I, Estürk Z, Tellioglu E, Önal A. Pulmoner alveolar mikrolithyazis. *Ege Tip Fak Der* 1967;6:399-403.
- FA28. Ravines HT. Pulmonary alveolar microlithiasis. Report of nine cases with familial incidence in seven of the nine cases among three families. *Am J Clin Pathol* 1969;52:767.
- FA29. Kino T, Kohara Y, Tsuji S. Pulmonary Alveolar Microlithiasis. *Am Rev Resp Dis* 1972;105:105-110.
- FA30. Sadaba-Garay F, Miguel De La Villa F, Franco Vicario R, Ibarria Lahuerta J, Bustamante Murga V. Pulmonary alveolar microlithiasis. *Rev Clin Esp* 1980;157:309-311.
- FA31. Wijnands JB, Bakker PM, Zoethout HE. Pulmonary alveolar microlithiasis in 2 Moroccan sisters. *Tijdschr Kindergeneesk* 1983;51:229-232.
- FA32. Rakusic N, Radosevic Z. Microlitiasis alveolar pulmonar. Presentación familiar en dos hermanas. *An Med Intern* 1991;8:445-447.

- FA33. Azim S, Azim W, Hayat F, Shafi H. Treatment of pulmonary alveolar microlithiasis with allendronate sodium. *Biomedica* 2004;20:32-35.
- FA34. Zarza BE, Herrán ED, López AS, Évez IZ, Martínez JA, Murga II. Microlithiasis alveolar pulmonar. Una enfermedad familiar con afectacion de dos hermanas. 7° Congreso Virtual Hispanoamericano de Anatomía Patológica Octubre 2005.
- FA35. Huqun, Izumi S, Miyazawa H, Ishii K, Uchiyama B, Ishida T, Tanaka S, Tazawa R, Fukuyama S, Tanaka T, Nagai Y, Yokote A, Takahashi H, Fukushima T, Kobayashi K, Chiba H, Nagata M, Sakamoto S, Nakata K, Takebayashi Y, Shimizu Y, Kaneko K, Shimizu M, Kanazawa M, Abe S, Inoue Y, Takenoshita S, Yoshimura K, Kudo K, Tachibana T, Nukiwa T, Hagiwara K. Mutations in the SCL34A2 gene are associated with pulmonary alveolar microlithiasis. *Am J Respir Crit Care Med* 2007;175:263-268.
- FA36. Yserbyt J, Alamé T, Doms C, Ninane V. Pulmonary alveolar microlithiasis and probe-based confocal laser endomicroscopy. *J Bronchology Interv Pulmonol* 2013;20:159-163.
- FA37. Semelaigne G, Hurez A, Le Braz A. Images micronodulaire pulmonaires familiales microlithiase alveolaire diffuse tres probable. *Arch Franç Ped* 1958;15:670.
- FA38. Freour P, Laumonier P, Verger P, Germouty R, Cardinaud JP. Les microlithiases pulmonaires alvéolaires. *J Méd Bordeaux* 1959;4:459-466.
- FA39. Viswanathan R. Pulmonary alveolar microlithiasis. *Thorax* 1962;17:251-256.
- FA40. Drinkovic I, Strohal K, Sabljica B. Mikrolithiasis alveolaris pulmonum. *Röfo* 1962;97:-180-185.
- FA41. Yang SP, Lin CC. Pulmonary Alveolar Microlithiasis. *Diseases of the Chest* 1963;44:163-167.
- FA42. Cetrángolo R, Guman N, Bordo HH, Costa AB, Jurado M. Microlithiasis alveolar pulmonar. *Rev Asoc Méd Argent* 1966;80:306-312.
- FA43. Burguet W, Reginster A. L'hérédité de la microlithiase alvéolaire pulmonaire. A propos d'une nouvelle observation familiale. *Annales de Génétique* 1967; 10:75-81.
- FA44. Martines F, Ascenti E, Benness G, Ruggeri A. La microlitiasi endoalveolare del polmone. *Rev Bras Biol* 1967;26:1465-1476.

- FA45. Passariello R. La microlitiasi alveolare del polmone. Revisione della letteratura e presentazione di 6 nuovi casi. Riv Radiol 1968;8:3-75.
- FA46. Sclafani G, Piga C. La microlitiasi endoalveolare del polmone: descrizione di due casi in fratelli. Riv Clin Pediat 1968;81:1338-1340.
- FA47. Gori E, Pica V. Microlitiasi endoalveolare nell'infanzia. Vita Osped 1969;1:67.
- FA48. Gonzáles de Vega N, Gómez-Moreno C, Rodríguez Agular M. Microlithiasis alveolar pulmonar. Rev Clin Esp 1970;118:467-472.
- FA49. Strumeliev S. Zum Familiencharakter der Pulmolithiasis endoalveolaris diffusa. Z Erkr Atmungsorgane 1970;132:31-38.
- FA50. Bhatia JT, Thind GS. Pulmonary alveolar microlithiasis. Indian J Tuberculosis 1976;33:110.
- FA51. Enacar N, Karabiyikoglu G, Ekim N. Alveolar mikrolityazis. In: XIII Turk Tuberkuloz Kongresi-Istanbul: Ogun Kardesler 1977; 552.
- FA52. Pérez-Villacastin B, García Robledo A. Microlithiasis alveolar pulmonar. Revisión de la literatura y presentación de 3 nuevos casos. Rev Clin Esp 1978;149:155-158.
- FA53. Thind GS, Bhatia JL. Pulmonary alveolar microlithiasis. Br J Dis Chest 1978;72:151-154.
- FA54. Moreno-Camacho A, Miro JM, Coca-Payeras A, Camacho L, Mensa Pueyo J, Sasal M, Marin A, Segura F, Soriano E. Microlithiasis alveolar pulmonary. Dos nuevos casos en hermanos. Rev Clin Esp 1981;160:275-277.
- FA55. Miro JM, Moreno A, Coca A, Segura F, Soriano E. Pulmonary alveolar microlithiasis with an unusual radiological pattern. Br J Dis Chest 1982;76:91-96.
- FA56. Kocyigit E, Gazioglu K, Cavdar T, Erben T. Ilginç özellikleri olan 3 alveolar mikrolitiazis vakasi. Solunum 1983;8:276-283.
- FA57. Yenel F, Küçükusta AR. Bir akciğer microlithiasis olgusu. Cerrahpaşa Tıp Fak Der 1984;15:133-137.
- FA58. Winzelberg GG, Boller M, Sachs M, Weinberg J. CT evaluation of pulmonary alveolar microlithiasis. J Comput Assist Tomogr 1984;8:1029-1031.

- FA59. Keskiäho I, Tukiainen P, Rapola J, Kaitila I. Alveolar Microlithiasis roentgen findings. *Duodecim* 1985;101:1789-1793.
- FA60. Muto R, Bozzi V, Muto M, Muto M, Muto P. Ruolo primario dell'esame standard del torace nella diagnosi di microlitiasi polmonare in fase iniziale. *Radiol Med* 1988;76:97-99.
- FA61. Liebetrau G, Aßmann H, Reiß-Zimmermann GU, Aerisch F, Pielesch W. Microlithiasis alveolaris pulmonum. *Pneumologie* 1989;43:464-468.
- FA62. Yüksel M, Öztekin I, Yılmaz G, Balkan E. Bir Pulmoner Alveoler Mikrolitiazis Olgusu. *Türk Patoloji Dergisi* 1990;6:45-49.
- FA63. Babu MK, Thomas JA. Pulmonary alveolar microlithiasis. *Indian J Pathol Microbiol* 1992;35:149-152.
- FA64. Argüelles M, Quiñónez MG, Cicero R, Giacinti P. Microlithiasis alveolar pulmonar en dos hermanos. *Rev Invest Clin* 1993;45:593-596.
- FA65. González A, Jahn E, Lanz A, Rodríguez S. Microlitiasis alveolar pulmonar: Presentación de 5 casos. *Gac Med Caracas* 1993;101:58-62.
- FA66. Mariotta S, Guidi L, Mattia P, Torrelli L, Pallone G, Pedicelli G, Bisetti A. Pulmonary microlithiasis: Report of two cases. *Respiration* 1997;64:165-169.
- FA67. Al-Kubaisi W, Al-Alwan N, Al-Nu'aimi K. Pulmonary alveolar microlithiasis: an overlooked disease in Iraq. *East Mediterr Health J* 2000;6:1130-1134.
- FA68. Erelel M, Kiyani E, Çuhadaroğlu Ç, Yılmazbayhan D, Kiliçaslan Z. Pulmonary Alveolar Microlithiasis in Two Siblings. *Respiration* 2001;68:327-330.
- FA69. Barbolini G, Rossi G, Bisetti A. Pulmonary Alveolar Microlithiasis. *N Engl J Med* 2002;347:69-70.
- FA70. Shaw MS, Nanavati KI, Airon N, Shah RR, Joshi BD. Pulmonary alveolar microlithiasis - case report. *Chest* 2003;123:277-279.
- FA71. Tunç M, Çalışır HC, Sazak H, Ulus F, Şipit T, Şavkilioğlu E. Respiratory Failure Due to Pulmonary Alveolar Microlithiasis: A Case Report. *Turkish Respiratory Journal* 2005;6:105-108.

- FA72. Takahashi H, Chiba H, Shiratori M, Tachibana T, Abe S. Elevated serum surfactant protein A and D in pulmonary alveolar microlithiasis. *Respirology* 2006;11:330-333.
- FA73. Ito K, Kubota K, Yukihiro M, Izumi S, Miyano S, Kudo K, Sasao Y. FDG-PET/CT finding of high uptake in pulmonary alveolar microlithiasis. *Ann Nucl Med* 2007;21:415-418.
- FA74. Thapa R, Ganguly D, Ghosh A. Pulmonary alveolar microlithiasis in siblings. *Indian J Pediatr* 2008;45:154-156.
- FA75. Zhong YQ, Hu CP, Cai XD, Nie HP. A novel mutation of the *SCL34A2* gene in a Chinese pedigree with pulmonary alveolar microlithiasis. *Zhonghua Yi Xue Yi Chuan Xue Za Zhi* 2009;26:365-368.
- FA76. Siddiqui NA, Fuhrman CR. Best cases from the AFID. Pulmonary alveolar Microlithiasis. *RadioGraphics* 2011;31:585-590.
- FA77. Mansouri F, Kavianpour MA. Two cases of Pulmonary Alveolar microlithiasis in a family. *J Medicine* 2013;14:80-82.
- FA78. Hagiwara K, Johkob T, Tachibana T. Pulmonary Alveolar Microlithiasis. In McCormack FX, Trapnell BC, Panos RJ. *Molecular Basis of Pulmonary Disease: insights from rare lung disorders.*, *Respiratory Medicine, Springer Science+Business Media*,2010:325-338. (10 groups)
- FA79. Chapelle P. A propos de deux cas de microlithiase alvéolaire pulmonaire familiale. Thèse Méd Bordeaux 1958;179.
- FA80. Sroczynska F. Familial occurrence of calcinosis of the pulmonary alveolar. *Grazlica* 1970;38:92.
- FA81. Hazar A, Erbagci A, Caglar T, Yilmaz N, Erem AR. Mikrolithiazis tanisinda sintigrafinin degeri. In: XIX Tüberküloz ve Göğüs Hastaliklari Kongresi. Sivas; Dilek,1991:304.
- FA82. Ortaköylü G, Ketenci A, Ayşe B, Emel C, Nur U. Pulmonary Alveolar Microlithiasis. *Turkish Respiratory Journal* 2006;7:34-37.

- FA83. Dogan OT, Ozsahin SL, Gul E, Arslan S, Koksall B, Berk S, Ozdemir O, Akkurt I. A Frame-Shift Mutation in the *SLC34A2* Gene in Three Patients with Pulmonary Alveolar Microlithiasis in an Inbred Family. *Inter Med* 2010;49:45-49.
- FA84. Abba AA. Asymptomatic full term pregnant patient with a grossly abnormal chest radiograph. *Saudi Med J* 2003;24:677-679.
- FA85. Shigeno C, Fukunaga M, Morita R, Maeda H, Hino M, Torizuka K. Bone scintigraphy in Pulmonary alveolar microlithiasis: A Comparative Study of Radioactivity and Density Distribution. *Clinical Nuclear Medicine* 1982;7:103-107.
- FA86. Jakob SM, Kraft R, Im Hof V. 3 Geschwister mit identischer, seltener Pneumopathie. *Schweiz Med Wochenschr* 1997;127:1528-1530.
- FA87. Nitsheff W, Stereff S. Familiäres Auftreten der pulmolithiasis endoalveolaris diffusa. *Rad Diagn Berlin* 1966;7:159-166.
- FA88. Bilalis D, Pournaras N, Papadimitriou D, Daïkos G. Microlithiase alvéolaire pulmonaire. Observation sur un cas familial. *La nouvelle press médicale* 1973;2:2877-2880.
- FA89. Zheng BY. Pulmonary alveolar microlithiasis: a rare familial inheritance with report of three cases in a family. *Zhonghua Jie He He Hu Xi Ji Bing Za Zhi* 1979;2:103-105.
- FA90. Zhang Y, Yang Y, Yu T, Qiao JH, Tumen W, Wu C, Ma Z. Three cases of pulmonary alveolar microlithiasis in a family and clinical analysis. *Chin J Tuberc Respir Dis* 2008;31:112-115.
- FA91. Lulu ARD, Humad SM, Al Anzi AA. Pulmonary alveolar microlithiasis. *Med Principles Pract* 1996;5:227-233.
- FA92. Al-Alawi AS. Familial occurrence of pulmonary alveolar microlithiasis in 3 siblings. *Saudi Med J* 2006;27:238-240.
- FA93. Gaber KA, Najem SA, Twair A, Dharrat A. Pulmonary Alveolar Microlithiasis In Living Adult Monozygotic Twin; CT Scan Versus CXR Family Screening Results. Doi:10.1164/ajrccm-conference.2012.185.1_MeetingAbstracts.

- FA94. Sato K. Three cases of microlithiasis alveolaris pulmonum occurring in one family. Sc Report Res Inst Tohoku Univ 1955;6:391-399.
- FA95. Mariani B, Bassi A. Microlitiasi polmonare endoalveolare familiare. G Pneumol 1966;10:579-583.
- FA96. Mitra S, Ghoshal AG. A family of pulmonary alveolar microlithiasis. Lung India 2000;18:97-100.
- FA97. Ma T, Ren J, Yin J. A Pedigree with Pulmonary Alveolar Microlithiasis: A Clinical Case Report and Literature Review. Cell Biochem Biophys 2014;70:565-572.
- FA98. Yalin T, Arslan A, Selçuk M, Tanik A. Pulmoner Alveoler Mikrolitiazis: Altı Olgu Bildirisi. O.M.Ü Tip Dergisi 1993;10:47-50.
- FA99. Esguerra-Gómez G, Lichtemberger E, Santamaría A, Carvajal L, Jiménez-Peñuela B, Saaibí E, Ray Barrera A, Ordúz E, Correa-Kenao A. Familial pulmonary alveolar microlithiasis: Four cases from Colombia. Radiology 1959;72:550-561.
- FA100. Kiatboonsri S, Charoenpan P, Vathesatogkit P, Boonpucknavig V. Pulmonary Alveolar Microlithiasis: Report of five cases and literature review. J Med Assoc Thai 1985;68:672-677.
- FA101. Perosa L, Ramunni M. La microlitiasi endoalveolare del polmone. Rec Progr Med 1959;26:353-429.
- FA102. Thiruvengadam KV, Arunachalam K, Murali MR, Sarma AVS, Varadarajan MG, Shetty BS, Swamidasan G. Pulmonary alveolar microlithiasis in a family. The Journal of the Association of Physician of India. 1972;7:707-712.
- FA103. Mikhailov V. Pulmonary alveolar microlithiasis. Klin Med 1954;32:31-36.
- FA104. Biary MS, Abdullah MA, Assaf HM, Wazzan A. Pulmonary alveolar microlithiasis in a Saudi child and two cousins. Ann Trop Paediatr 1993;13:409-413.
- FA105. Monabati A, Ali Ghayumi M, Kumar PV. Familial Pulmonary Alveolar Microlithiasis Diagnosed by Bronchoalveolar Lavage. A case report. Acta Cytol 2007;51:80-82.

- FA106. Kanra G, Tanyol E, Gocmen A. Pulmonary alveolar microlithiasis. Turkish J Pediatr 1988; 30:61-67.
- FA107. Wang HY, Shen HH, Jiang ZN. Pulmonary alveolar microlithiasis: report of four familial cases. Chin Med J 2004;117:950-952.
- FA108. Castellana G, Lamorgese V. La microlitiasi endoalveolare polmonare. Caso clinico a sostegno dell'ipotesi ereditaria. Rass Pat App Resp 1997;12:247-251.
- FA109. Senyigit A, Yaramiş A, Gürkan F, Kirbaş G, Büyükbayram H, Nazaroglu H, Alp MN, Topçu F. Pulmonary alveolar microlithiasis: a rare familial inheritance with report of six cases in a family. Respiration 2001;68:204-209.
- FA110. Ye Feng, Xie J, Zhang N, Zhong S, Chen G, Zhong N. Pulmonary alveolar microlithiasis: report of three cases and literature review. Int J Respir 2011;31:1394-1398.

Table E2: Cases of PAM with a slow clinical evolution and longest follow-up (with references).

Author	Reference	Sex	Age at diagnosis (years)	Survival after diagnosis (years)
Raffa et al., 1996	E1	F	18	30
Usui et al., 1993	E2	M	12	30
Hishida et al., 1992	E3	F	43	33
Uhlinger, 1965	E4	M	25	33
Shishido et al., 1993	E5	M	12	34
Prakash et al., 1983	E6	M	20	34
Tatti and Riniker, 1962	E7	M	22	35
Gialafos et al., 2005	E8	F	20	35
Coulibaly et al., 2009	E9	F	11	38
de Velasco, 1964	E10	M	16	40
Moran et al., 1997	E11	F	30	40
Moran et al., 1997	E11	M	13	41
Gramiccioni et al., 1984	E12	M	12	45
Hagiwara et al., 2010	E13	F	10	47
Jinta et al., 2012	E14	M	6	47
Sahoo et al., 2013	E15	M	7	47
Hagiwara et al., 2010	E13	M	8	48
Castellana et al., 1998	E16	M	27	58 *

* The longest-lived clinical case, with an absolutely stationary clinical, functional and radiographic picture, is still alive, 58 years after the diagnosis.

- E1. Raffa H, El-Dakhakny M, Al-Ibrahim K, Mansour MS. Single lung transplantation for alveolar microlithiasis: The first clinical report. Saudi J Kidney Dis Transpl 1996;7:189-193.
- E2. Usui M, Watanabe M, Hattori J, Horie K, Shima H. A case of pulmonary alveolar microlithiasis. Nippon Kyobu Shikkan Gakkai Zasshi 1993;31:501-505.
- E3. Hishida T, Furutani M. Ultrastructural observation of bronchoalveolar lavage fluid in pulmonary alveolar microlithiasis. J Clin Electron Microscopy 1992;25:55-61.
- E4. Uhlinger E. Microlitiasi, amiloidosi, proteinosi del polmone. Beitr Klein Erforsch Tuberk 1965;132:130.
- E5. Shishido S, Toritani T, Nakano H, Tokushima T. A case of alveolar microlithiasis which developed spontaneous pneumothorax due to progression of emphysematous bullae

- during 34 years after established diagnosis. *Nippon Kyobu Shikkan Gakkai Zasshi* 1993;31:881-885.
- E6. Prakash UB, Barham SS, Rosenow EC, Brown ML, Payne WS. Pulmonary alveolar microlithiasis. A review including ultrastructural and pulmonary function studies. *Mayo Clin Proc* 1983;58:290-300.
- E7. Tatti V, Riniker P. Diffuse a familial pulmonary alveolar microlithiasis. *Helv Med Acta* 1962;29:611-613.
- E8. Gialafos EJ, Moyssakis I, Taktikou H, Votzas V, Sfikakis PP. Treatment of pulmonary hypertension secondary to alveolar microlithiasis with bosentan: a case report. *Sarcoidosis Vasc Diffuse Lung Dis* 2005;22:237.
- E9. Coulibaly B, Fernandez C, Reynaud-Gaubert M, D'Journo X, Doddoli C, Taséi AM. Microlithiase Alvéolaire avec fibrose intestitielle sévère conduisant à la greffe. *Annales de pathologie* 2009;29:241-244.
- E10. De Velasco L. Microlithiasis alveolar pulmonum. *Prax Pneumol* 1964;18:480.
- E11. Moran CA, Hochholzer L, Hasleton PS, Johnson FB, Koss MN. Pulmonary alveolar microlithiasis. A clinicopathologic and chemical analysis of seven cases. *Arch Pathol Lab Med* 1997;121:607-611.
- E12. Gramiccioni E, Montanari S, Pasqua F, Roca A, Innocenti MG. La microlitiasi polmonareendoalveolare diffusa: revisione della letteratura e illustrazione di un caso. *Ann Ist Forlanini* 1984;4:78-88.
- E13. Hagiwara K, Johkob T, Tachibana T. Pulmonary Alveolar Microlithiasis. In McCormack FX, Trapnell BC, Panos RJ. *Molecular Basis of Pulmonary Disease: insights from rare lung disorders.*, Respiratory Medicine, Springer Science+Business Media,2010:325-338.

- E14. Jinta T, Tomishima Y, Horinouchi H, Shimazaki K, Taki F, Nishimura N, Miyazawa H, Hagiwara K, Chohnabayashi N. A case of pulmonary alveolar microlithiasis in which dialysis was performed for the concomitant renal disease. *AJRS* 2012;1:267-272.
- E15. Sahoo MK, Karunanithi S, Bal CS. Pulmonary alveolar microlithiasis: imaging characteristics of planar and SPET/CT bone scan versus ¹⁸F-FDG and ¹⁸F-sodium fluoride PET/CT scanning. *Jpn J Radiol* 2013;31:766-769.
- E16. Castellana G, Fanelli C, Napoli D, V. Lamorgese. La microlitiasi alveolare polmonare: decorso clinico, terapia e rivisitazione di un singolare caso lungovivente. *Quad Pat Tor D Cotugno* 1998;7:26-29.

References for each paragraph other than the ones already listed in the manuscript

Introduction

11. Malpighi M. Manoscritti vol XII foglio 81. In: Anzalone, Marcello Malpighi e i suoi scritti sugli organi del respiro. Ed Tamari, Bologna. 1966;259.
12. Harbitz F. Extensive calcification of the lungs as a distinct disease. Arch Intern Med 1918;21:139-146.
13. Schildknecht O. Pulmonary alveolar microlithiasis. Arch J Path Anat. 1932;285:466-480.
14. Pühr L. Microlithiasis alveolaris pulmonum. Virchows Arch Path Anat 1933;290:156-160.
15. Mariani B, Montanini N, Torelli G. La microlitiasi polmonare. Ann Ist C Forlanini 1947;10:179-199.
16. Mikhailov V. Pulmonary alveolar microlithiasis. Klin Med 1954;32:31-36.
17. Sosman MC, Dodd GD, Jones DW, Pillmore GU. The familial occurrence of pulmonary alveolar microlithiasis. Am J Roentgenol 1957;77:947-1012.
18. Perosa L, Ramunni M. La microlitiasi endoalveolare del polmone. Rec Progr Med 1959;26:353-429.
19. Mariani B, Bassi A. Attualità in tema di microlitiasi polmonare endoalveolare. Proposte per una classificazione anatomo-clinica. Min Med 1967;58:3761-3766.
110. Burguet W, Reginster A. L'hérédité de la microlithiase alvéolaire pulmonaire. A propos d'une nouvelle observation familiale. Annales de Génétique 1967; 10:75-81.
111. Susini S, Bini P, Romagnoli E, Di Cesare L. Illustrazione di due rare osservazioni di microlitiasi polmonare endoalveolare diffusa. Riv Pat Clin Tuberc 1970;43:569-598.

Familiality

36 families in which the parents were first cousins.

- F1. Aoun-Bacha Z, Khayat G, Aoun N, Khoury F. Microlithiase alvéolaire avec calcification pleurale. *Rev Mal Respir* 1999;16:102-103.
- F2. Biary MS, Abdullah MA, Assaf HM, Wazzan A. Pulmonary alveolar microlithiasis in a Saudi child and two cousins. *Ann Trop Paediatr* 1993;13:409-413.
- F3. Burguet W, Reginster A. L'hérédité de la microlithiase alvéolaire pulmonaire. A propos d'une nouvelle observation familiale. *Annales de Génétique* 1967;10:75-81.
- F4. Castellana G, Lamorgese V. La microlitiasi endoalveolare polmonare. Caso clinico a sostegno dell'ipotesi ereditaria. *Rass Pat App Resp* 1997;12:247-251.
- F5. Chaieb J, Porto N, Zamel N. Um caso de microlitiasi alveolar pulmonar no Rio grande do Sul. *O Hosp* 1963;63:193-199.
- F6. De Maestri A, Liodice G. Microlitiasi endoalveolare polmonare in un bambino. *Min Ped* 1961;13:890-899.
- F7. Freour P, Laumonier P, Verger P, Germouty R, Cardinaud JP. Les microlithiases pulmonaires alvéolaires. *J Méd Bordeaux* 1959;4:459-466.
- F8. Hagiwara K, Johkob T, Tachibana T. Pulmonary Alveolar Microlithiasis. In McCormack FX, Trapnell BC, Panos RJ. *Molecular Basis of Pulmonary Disease: insights from rare lung disorders.*, *Resp Med*, Springer Science+Business Media,2010:325-338. (9 cases)
- F9. Kanra G, Tanyol E, Gocmen A. Pulmonary alveolar microlithiasis. *Turkish JPediatr*1988; 30:61-67.
- F10. Ma T, Ren J, Yin J. A Pedigree with Pulmonary Alveolar Microlithiasis: A Clinical Case Report and Literature Review. *Cell Biochem Biophys* 2014;70:565-572.
- F11. Mariotta S, Guidi L, Mattia P, Torrelli L, Pallone G, Pedicelli G, Bisetti A. Pulmonary microlithiasis: Report of two cases. *Respiration* 1997;64:165-169.
- F12. Mikhailov V. Pulmonary alveolar microlithiasis. *Klin Med* 1954;32:31-36.

- F13. Monabati A, Ali Ghayumi M, Kumar PV. Familial Pulmonary Alveolar Microlithiasis Diagnosed by Bronchoalveolar Lavage. A case report. *Acta Cytol* 2007;51:80-82.
- F14. O'Neill RP, Cohen JE, Pellegrino ED. Pulmonary alveolar microlithiasis a family study. *Ann Intern Med* 1967;67:957-967.
- F15. Passariello R. La microlitiasi alveolare del polmone. Revisione della letteratura e presentazione di 6 nuovi casi. *Riv Radiol* 1968;8:3-75.
- F16. Perosa L, Ramunni M. La microlitiasi endoalveolare del polmone. *Rec Progr Med* 1959;26:353-429.
- F17. Rotem Y, Solomon M, Hertz-Frankenhuis M. Pulmonary alveolar microlithiasis. *Ann Paediat* 1963;201:4-12.
- F18. Sato K. Three cases of microlithiasis alveolaris pulmonum occurring in one family. *Sc Report Res Inst Tohoku Univ* 1955;6:391-399.
- F19. Schmidt H, Lorcher U, Kitz R, Zielen S, Ahrens P, Konig R. Pulmonary alveolar microlithiasis in children. *Pediatr Radiol* 1996;26:33-36.
- F20. Senyigit A, Yaramiş A, Gürkan F, Kirbaş G, Büyükbayram H, Nazaroglu H, Alp MN, Topçu F. Pulmonary alveolar microlithiasis: a rare familial inheritance with report of six cases in a family. *Respiration* 2001;68:204-209.
- F21. Shishido S, Toritani T, Nakano H, Tokushima T. A case of alveolar microlithiasis which developed spontaneous pneumothorax due to progression of emphysematous bullae during 34 years after established diagnosis. *Nippon Kyobu Shikkan Gakkai Zasshi* 1993;31:881-885.
- F22. Wallis C, Whitehead B, Malone M, Dinwiddie R. Pulmonary alveolar microlithiasis in childhood: diagnosis by transbronchial biopsy. *Pediatr Pulmonol* 1996;21:62-63.

- F23. Wang HY, Shen HH, Jiang ZN. Pulmonary alveolar microlithiasis: report of four familial cases. Chin Med J 2004;117:950-952.
- F24. Ye F, Xie J, Zhang N, Zhong S, Chen G, Zhong N. Pulmonary alveolar microlithiasis: report of three cases and literature review. Int J Respir 2011;31:1394-1398. (5 cases)
- F25. Ye J, Zhao L, Fang Z, Xiu Q, Li B. Pulmonary Alveolar Microlithiasis: One Case report and Literature Review. Chin J Respir Crit Care Med 2013;12:601-604.
- F26. Zhou C. Microlithiasis: report of 2 cases and review of literature. Clin J Tub Resp Dis 1985;8:293-295.

Clinical presentation and course

6 cases in which it was possible to establish the date of onset of the disease, thanks to the availability of previous chest X-rays showing an entirely normal picture.

- C1. Biressi PC, Casassa PM. La microlitiasi polmonare endoalveolare. Min Med 1956;47:930-939.
- C2. Kino T, Kohara Y, Tsuji S. Pulmonary Alveolar Microlithiasis. Am Rev Resp Dis 1972;105:105-110.
- C3. Krokowsky E, Michel H. The roentgenogram in the course of microlithiasis alveolaris pulmonum. Forsch Roentgenstr 1966;105:201-203.
- C4. Laake H. Calcification of the lungs: Pulmonary alveolar microlithiasis Acta Tuberc Scand 1959;36:249.
- C5. Puhr L. Microlithiasis alveolaris pulmonum. Virchows Arch Path Anat 1933;290:156-160.
- C6. Rotem Y, Solomon M, Hertz-Frankenhuis M. Pulmonary alveolar microlithiasis. Ann Paediat 1963;201:4-12.

72 cases with finger clubbing

- C7. Aksel N, Şahin B, Özsöz A. Pulmoneralveoler mikrolitiazis: olgu sunumu. Izmir Gogus Hastanesi Dergisi 2005;2:65-69.
- C8. Al-Alawi AS. Familial occurrence of pulmonary alveolar microlithiasis in 3 siblings. Saudi Med J 2006;27:238-240.
- C9. Aliperta A, Mauro G, Saviano S, Bellissimo U, Perna A, Martufi S. Proteinosi alveolare, pneumopatia a corpi amilacei e microlitiasi polmonare: contributo istopatologico. Arch Mon Mal Tor 1976;31:87-118.
- C10. Antonini A, Mosca R, Scafì M. Contributo clinico-fisiopatologico di un caso di microlitiasi endoalveolare polmonare. Progr Med 1975;31:562-567.
- C11. Aoun-Bacha Z, Khayat G, Aoun N, Khoury F. Microlithiase alvéolaire avec calcification pleurale. Rev Mal Respir 1999;16:102-103.
- C12. Badger TL, Gottlieb L, Gaensler EA. Pulmonary alveolar microlithiasis, or calcinosis of the lung. N Engl J Med 1955;253:709-715.
- C13. Bahadur P, Seetharaman M, Krishnamurthy H. Pulmonary alveolar microlithiasis-a case report. Lung India 1987;4:187-188.
- C14. Balikian JP, Fuleihan CN, Nucho CN. Pulmonary alveolar microlithiasis. Report of five cases with special reference to roentgen manifestations. Am J Roentgenol Radium Ther Nucl Med 1968;103:509-518.
- C15. Bhatia JT, Thind GS. Pulmonary alveolar microlithiasis. Indian J Tuberculosis. 1976;33:110.
- C16. Bhatt S, Luqman-Arafath T, Mohan A, Gularia R. A rare cause of dyspnoea. Postgrad Med J 2007;83:1-2.

- C17. Bhattacharjee BK, Barua R, Duta JK. Pulmonary alveolar microlithiasis. *Indian J Chest Disease* 1965;7:51-53.
- C18. Biressi PC, Casassa PM. La microlitiasi polmonare endoalveolare. *Min Med* 1956;47:930-939.
- C19. Bunger P, Fassbender CW, Schutze G. Zur Microlithiasis alveolaris pulmonum. *Fortschr Roentgenstr* 1962;97:775-779.
- C20. Ceylan E, Kanbay A, Gedik C, Çakanlar N. Pulmoner Alveoler Mikrolitiazis. *Respir Case Rep* 2014;3:24-28.
- C21. Challa-Sudha, Dusaj, Kumar, Melhotra. Pulmonaris alveolar microlithiasis. *Indian J Chest Dis* 1984,26,263-266.
- C22. Chalmers AG, Wyatt J, Robinson PJ. Computed tomography and pathological findings in pulmonary alveolar microlithiasis. *Br J Radiol* 1986;59:408-411.
- C23. Chatterji R, Gaude GS, Patil PV. Pulmonary Alveolar Microlithiasis: Diagnosed by Sputum Examination and Transbronchial Biopsy. *Indian J Chest Dis Allied Sci* 1997;39:263-267.
- C24. Chen W, Gu T. A case of pulmonary alveolar microlithiasis with Cor Pulmonale. *Imaging Med Surg* 2012;2:65-67.
- C25. Chinachoti N, Tangchai P. Pulmonary alveolar microlithiasis associated with inhalation of snuff in Thailand. *Dis Chest* 1957;32:687-689.
- C26. de Souza Filho JOB, Cavalcante Silveira CM, Barreto da Cunha A, Ferreira Pinheiro VG, de Lucena Feitosa FE, Alcantara Holanda M. Pregnancy in a patient with severe pulmonary alveolar microlithiasis. *J Bras Pneumol* 2008;34:885-888.
- C27. Dwivedi MK, Pal RK, Borkar PB. Images - Pulmonary alveolar microlithiasis. *Indian Journal of Radiology and Imaging* 1999;9:195-196.

- C28. Epardeau B, Desche P, Tainturier C, Caubarrère I. Microlithiase alvéolaire, diagnostic non invasif par lavage alvéolaire et scintigraphie au technetium. *Ann Pathol* 1987;7:154-157.
- C29. Erelel M, Kiyan E, Çuhadaroğlu Ç, Yilmazbayhan D, Kiliçaslan Z. Pulmonary Alveolar Microlithiasis in Two Siblings. *Respiration* 2001;68:327-330.
- C30. Ghavamian M. Pulmonary alveolar microlithiasis. A Report of Two Cases. *Nebr Med J* 1972;57:259-264.
- C31. Gramiccioni E, Montanari S, Pasqua F, Roca A, Innocenti MG. La microlitiasi endoalveolare diffusa: revisione della letteratura e illustrazione di un caso. *Ann Ist Forlanini* 1984;4:78-88.
- C32. Kanat F, Teke T, Imecik O. Pulmonary alveolar microlithiasis with epididymal and periurethral calcifications causing obstructive azospermia. *Int J Tuberc Lung Dis* 2004;8:1274-1276.
- C33. Krokowsky E, Michel H. The roentgenogram in the course of microlithiasis alveolaris pulmonum. *Forsch Roentgenstr* 1966;105:201-203.
- C34. Lulu ARD, Humad SM, Al Anzi AA. Pulmonary alveolar microlithiasis. *Med Principles Pract* 1996;5:227-233. (2 cases)
- C35. Malur PR, Keni A, Jayaram N. Alveolar microlithiasis - Report of Two Cases. *Indian J Pathol Microbiol* 1993;36:163-167.
- C36. Mansouri F, Kavianpour MA. Two cases of Pulmonary Alveolar microlithiasis in a family. *J Medicine* 2013;14:80-82. (2 cases)
- C37. Mascie-Taylor BH, Wardman AG, Madden CA, Page RL. A case of alveolar microlithiasis: observation over 22 years and recovery of material by lavage. *Thorax* 1985;40:952-953.

- C38. Mitra S, Ghoshal AG. A family of pulmonary alveolar microlithiasis. Lung India 2000;18:97-100.
- C39. Monabati A, Ali Ghayumi M, Kumar PV. Familial Pulmonary Alveolar Microlithiasis Diagnosed by Bronchoalveolar Lavage. A case report. Acta Cytol 2007;51:80-82.
- C40. Nabahati M, Mehraiz R, Monadi M, Rajabi M, Khani A. Pulmonary Alveolar Microlithiasis. IJARS 2014;3:20.
- C41. Nagata. A case of Pulmonary alveolar microlithiasis in which diffuse micronodulations on chest roentgenogram has been noticed 26 years before. Nippon Naika Gakkai Zasshi 1987;76:1554-1558.
- C42. O'Neill RP, Cohen JE, Pellegrino ED. Pulmonary alveolar microlithiasis a family study. Ann Intern Med 1967;67:957-967.
- C43. Passariello R. La microlitiasi alveolare del polmone. Revisione della letteratura e presentazione di 6 nuovi casi. Riv Radiol 1968;8:3-75.
- C44. Perosa L, Ramunni M. La microlitiasi endoalveolare del polmone. Rec Progr Med 1959;26:353-429.
- C45. Portnoy LM, Amadeo B, Henningar GR. Pulmonary alveolar microlithiasis: an unusual case. Am J Clin Pathol 1964;41:194-201.
- C46. Prakash UB, Barham SS, Rosenow EC, Brown ML, Payne WS. Pulmonary alveolar microlithiasis. A review including ultrastructural and pulmonary function studies. Mayo Clin Proc 1983;58:290-300.
- C47. Rama Rao B, Martin MB. Pulmonary Alveolar microlithiasis. Aust Radiol 1980;24:24-26.

- C48. Samano MN, Waisberg DR, Canzian M, Campos SV, Pêgo-Fernandes PM, Jatene FB. Lung transplantation for pulmonary alveolar microlithiasis: a case report. *Clinics (Sao Paulo)* 2010;6:233-236.
- C49. Sarkissian S, Shamsa AMZ. A case of Pulmonary Microlithiasis. *Acta Med Iran* 1960;3:12-15.
- C50. Sharma SK, Sharma S, Mukhopadhyaya S, Padhy AK, Vijayraghavan M. Pulmonary Alveolar Microlithiasis. *Indian J Chest Dis Allied Sci* 1992;34:205-215.
- C51. Singh NK, Gupta A. Pulmonary Alveolar Microlithiasis. *J Assoc Physicians India* 1995;43:647-648.
- C52. Stamatis G, Zerkowski HR, Doetsch N, Greshuchna D, Konietzko N, Reidemeister JC. Sequential bilateral lung transplantation for pulmonary alveolar microlithiasis. *Ann Thorac Surg* 1993;56:972-975.
- C53. Takahashi H, Chiba H, Shiratori M, Tachibana T, Abe S. Elevated serum surfactant protein A and D in pulmonary alveolar microlithiasis. *Respirology* 2006;11:330-333.
- C54. Taneja VP, Sen D. Pulmonary Alveolar Microlithiasis. *J Asso Phys Ind* 1981;29:411-414.
- C55. Thiruvengadam KV, Arunachalam K, Murali MR, Sarma AVS, Varadarajan MG, Shetty BS, Swamidasan G. Pulmonary alveolar microlithiasis in a family. *The Journal of the Association of Physician of India*. 1972;7:707-712.
- C56. Thomson WB. Pulmonary Alveolar Microlithiasis. *Thorax* 1959;14:76-81.
- C57. Tunç M, Çalışır HC, Sazak H, Ulus F, Şipit T, Şavkilioğlu E. Respiratory Failure Due to Pulmonary Alveolar Microlithiasis: A Case Report. *Turkish Respiratory Journal* 2005;6:105-108.

- C58. Uçan ES, Keyf AI, Aydilek R, Yalcin Z, Sebit S, Kudu M, Ok U. Pulmonary alveolar microlithiasis: review of Turkish reports. *Thorax* 1993;48:171-173. (12 cases)
- C59. Vidyasagar B, Ranjana SD, Jayan R, Nagaraja Setty KL, Shivalingappa GS. Pulmonary alveolar microlithiasis. *Lung India* 1998;2:80-82. (2 cases)
- C60. Wang HY, Shen HH, Jiang ZN. Pulmonary alveolar microlithiasis: report of four familial cases. *Chin Med J* 2004;117:950-952. (3 cases)
- C61. Waters HM. Microlithiasis alveolaris pulmonum. *Tubercle* 1960;41:276-278.
- C62. Zetina López A, Rivas Bobadilla E, Cabrera Juárez H, Bran JL. Microlithiasis alveolar pulmonar: imágenes de un caso interesante y revisión de literatura. *Rev Med Interna* 1997;8:22-23.

16 cases with pneumothorax

- C63. Batchelor TJ, Ngaage DL, McGivern DV, Cowen ME. Surgical Management of Pneumothorax in Pulmonary Alveolar Microlithiasis. *Ann Thorac Surg* 2007;84:290-292.
- C64. Chatterji R, Gaude GS, Patil PV. Pulmonary Alveolar Microlithiasis: Diagnosed by Sputum Examination and Transbronchial Biopsy. *Indian J Chest Dis Allied Sci* 1997;39:263-267.
- C65. Gaude GS, Pinto MJW, Bagga AS. Pneumothorax in pulmonary alveolar microlithiasis: a case report. *Antiseptic* 1995;91:135-136.
- C66. Gramiccioni E, Montanari S, Pasqua F, Roca A, Innocenti MG. La microlitiasi polmonare endoalveolare diffusa: revisione della letteratura e illustrazione di un caso. *Ann Ist Forlanini* 1984;4:78-88.
- C67. Hishida T, Furutani M. Ultrastructural observation of bronchoalveolar lavage fluid in pulmonary alveolar microlithiasis. *J Clin Electron Microscopy* 1992;25:55-61.

- C68. Kawakami M, Sato S, Takishima T. Electron microscopic studies on pulmonary alveolar microlithiasis. *Tohoku J Exp Med* 1978;126:343-361.
- C69. Ma T, Ren J, Yin J. A Pedigree with Pulmonary Alveolar Microlithiasis: A Clinical Case Report and Literature Review. *Cell Biochem Biophys* 2014;70:565-572.
- C70. Mariani B, Montanini N, Torelli G. La microlitiasi polmonare. *Ann Ist C Forlanini* 1947;10:179-199.
- C71. Morandi D. Microlithiasis alveolaris pulmonum. *Respiration* 1968;25:184-199.
- C72. Naseh S, Shilan M. First presentation of a case of pulmonary alveolar microlithiasis with spontaneous pneumothorax. *ERJ* 2012;40:Suppl 56 P3505.
- C73. Rodríguez F, Ferrer J, Briozzo L, Pons J. Pulmonary alveolar microlithiasis and pregnancy. *J Matern Fetal Neonatal Med* 2006;19:239-241.
- C74. Sartori C, Colamosca C. Eccezionale associazione di microlitiasi polmonare e tubercolosi. *Min Med* 1960;51:433-437.
- C75. Shigemura N, Bermudez C, Hattler BG, Johnson B, Crespo M, Pilewski J, Toyoda Y. Lung transplantation for pulmonary alveolar microlithiasis, *J Thorac Cardiovasc Surg* 2010;139:50-52.
- C76. Shishido S, Toritani T, Nakano H, Tokushima T. A case of alveolar microlithiasis which developed spontaneous pneumothorax due to progression of emphysematous bullae during 34 years after established diagnosis. *Nippon Kyobu Shikkan Gakkai Zasshi* 1993;31:881-885.
- C77. Torres Esteche V, Meerovich Alvarez E, Alietti C. Microlithiasis alveolar cálcica. *Arch Med Interna* 2005;327:37-40.
- C78. Winzelberg GG, Boller M, Sachs M, Weinberg J. CT evaluation of pulmonary alveolar microlithiasis. *J Comput Assist Tomogr* 1984;8:1029-1031.

Comorbidities

Milk Alkali Syndrome

D1. Portnoy LM, Amadeo B, Henningar GR. Pulmonary alveolar microlithiasis: an unusual case. Am J Clin Pathol 1964;41:194-201.

Pericardial Cyst

D2. Castellana G, Lamorgese V. La microlitiasi endoalveolare polmonare. Caso clinico a sostegno dell'ipotesi ereditaria. Rass Pat App Resp 1997;12:247-251.

Lymphocytic Interstitial Pneumonitis

D3. Ratjen FA, Schoenfeld B, Wiesemann HG. Pulmonary alveolar microlithiasis and lymphocytic interstitial pneumonitis in a ten year old girl. Eur Respir J 1992;5:1283-1285.

Diaphyseal Aclasia

D4. Ritchie DA, O'Connor SA, McGivern D. An unusual presentation of pulmonary alveolar microlithiasis and diaphyseal aclasia. Br J Radiol 1992;65:178-181.

Autosomal Recessive Waardenburg-Anophthalmia Syndrome

D5. Schmidt H, Lorcher U, Kitz R, Zielen S, Ahrens P, König R. Pulmonary alveolar microlithiasis in children. Pediatr Radiol 1996;26:33-36.

Hypertrophic Pulmonary Osteoarthropathy

D6. Emri S, Cöplü L, Selcuk ZT, Sahin AA, Baris YI. Hypertrophic pulmonary osteoarthropathy in a patient with pulmonary alveolar microlithiasis. Thorax 1991;46:145-154.

D7. Kirova G, Sergieva S, Palaveev K, Vlassov V, Veleva I. Pulmonary alveolar microlithiasis associated with hypertrophic osteoarthropathy - CT and scintigraphic presentations in two siblings. Eur J Radiol Extra 2004;51:31-35. (2 cases)

Pectus excavatum

- D8. Hasan S, Cevat O, Sami C, Mehmet TY, Tahir Y, Mehmet G, Sadi SG. Pulmonary alveolar microlithiasis with pectus excavatum. *Ind J Med Sci* 1994;48:199-200.
- D9. Kanat F, Teke T, Imecik O. Pulmonary alveolar microlithiasis with epididymal and periurethral calcifications causing obstructive azospermia. *Int J Tuberc Lung Dis* 2004;8:1274-1276.
- D10. Kacmaz F, Alyan O, Celenk M, Ozdemir O, Turkvatan A, Dogan M, Ilkay E. A case of Pulmonary Alveolar Microlithiasis with Cardiac Constriction Secondary to Severe Adjacent Pleural Involvement. *Cardiology* 2007;107:213-216.
- D11. Sahoo MK, Karunanithi S, Bal CS. Pulmonary alveolar microlithiasis: imaging characteristics of planar and SPECT/CT bone scan versus 18F-FDG and 18F-sodium fluoride PET/CT scanning. *Jpn J Radiol* 2013;31:766-769.
- D12. Balkahli S, Demir R, Patiroglu T, Özesmi M. Pulmoner alveolar mikrolithiazis tanisinda bronkoalveolar lavaj. *Tüberküloz ve Toraks* 1987;35:212-216.

Rheumatoid Arthritis

- D13. Ozbay B, Sakarya ME, Dilek I, Uzun K, Mete R, Akman E. A case of pulmonary alveolar microlithiasis an rheumatoid arthritis. *Eastern J Med* 1999;4:34-36.

Psoriasis

- D14. Al Awadi A, Djazmati W, El-Sameed YA. The Clinical Course of Progressive Pulmonary Alveolar Microlithiasis. *Chest* 2013;144:940A. doi:10.1378/chest 1701171.

Renal transplant recipients

- D15. Richardson J, Slovis B, Miller G, Dummer S. Development of pulmonary alveolar microlithiasis in a renal transplant recipient. *Transplantation* 1995;59:1056-1057.

Osteopetrosis

D16. Izadi P, Izadi B, Amini M, Keivani M. Pulmonary alveolar microlithiasis and osteopetrosis. *Tanaffos* 2008;7:60-63.

Non-Hodgkin lymphoma

D17. Omoniyi-Esan GO, Adediran IA, Famurewa OC, Badmos KB. Pulmonary alveolar microlithiasis: a case report. *Afr J Med Sci* 2005;34:195-197.

Antiphospholipid syndrome and discoid lupus

D18. Yilmaz MI, Koc B, Kantarcioglu M, Akinci SB, Ayta H, Bulucu F, Bal S. Pulmonary alveolar microlithiasis after Varicella zoster infection in a patient presenting with antiphospholipid syndrome and discoid lupus. *Rheumatol Int* 2002;22:213-215.

Sjogren's syndrome

D19. Soytürk AN, Argüder E, Karaleshi A, Hasanoğlu HC. A case of Pulmonary alveolar microlithiasis with Sjögren's syndrome. *Tuberk Toraks* 2013;61:258-259.

Diagnosis during pregnancy

D20. Abba AA. Asymptomatic full term pregnant patient with a grossly abnormal chest radiograph. *Saudi Med J* 2003;24:677-679.

D21. Al-Alawi AS. Familial occurrence of pulmonary alveolar microlithiasis in 3 siblings. *Saudi Med J* 2006;27:238-240.

D22. de Souza Filho JOB, Cavalcante Silveira CM, Barreto da Cunha A, Ferreira Pinheiro VG, de Lucena Feitosa FE, Alcantara Holanda M. Pregnancy in a patient with severe pulmonary alveolar microlithiasis. *J Bras Pneumol* 2008;34:885-888.

D23. Erdem G, Göktan A, Erbay F, Baysal T. Pulmonary Alveolar Microlithiasis and Preterm Delivery: A Case Report. *Turk Toraks Derg* 2014;15:33-35.

D24. Kannangara RD, Ragunathan MK, Perera A. A pregnant mother with pulmonary alveolar microlithiasis. *Galle Medical Journal* 2006;11:53-54.

D25. Rodríguez F, Ferrer J, Briozzo L, Pons J. Pulmonary alveolar microlithiasis and pregnancy. J Matern Fetal Neonatal Med 2006;19:239-241.

Microliths and calcifications in extrapulmonary sites

Medullary Nephrocalcinosis

M1. Brandenburg V, Schubert H . Pulmonary Alveolar Microlithiasis. N Engl J Med 2003;348:1555.

M2. Giallauria F, Giallauria G. Images in Thorax: Pulmonary alveolar microlithiasis. Thorax 2011;66:840.

M3. Kruger S, Brandenburg VM, Hoffman R, Breuer C, Riehl J. Pulmonary Alveolar Microlithiasis - a rare cause of bilateral extensive pulmonary infiltrates. Med Klin (Munich) 2002;97:304-307.

M4. Pant K, Shah A, Mathur RK, Chhabra SWK, Jain SK. Pulmonary alveolar microlithiasis with pleural calcification and nephrolithiasis. Chest 1990;96:245-246.

Pericardial Calcification

M5. Changbin Q, Shulin J, Baoming H. Radiological and CT Correlative Study of Pulmonary Alveolar Microlithiasis. Journal of Clinical Radiology 1998.

M6. Hishihara Y, Hagiwara K, Zen K, Huqun, Hosokawa Y, Natsuhara A. A case of pulmonary alveolar microlithiasis with an intragenetic deletion in SCL34A2 detected by a genome-wide SNP study. Thorax 2009;64:365-367.

M7. Kashyap S, Negi RS, Mohapatra PR. Pulmonary Alveolar Microlithiasis: a report of five cases from north western Himalayan region of India. Chest 2007;132:587-588.

- M8. Kiatboonsri S, Charoenpan P, Vathesatogkit P, Boonpucknavig V. Pulmonary Alveolar Microlithiasis: Report of five cases and literature review. *J Med Assoc Thai* 1985;68:672-677.
- M9. Richardson J, Slovis B, Miller G, Dummer S. Development of pulmonary alveolar microlithiasis in a renal transplant recipient. *Transplantation* 1995;59:1056-1057.
- M10. Wang HY, Shen HH, Jiang ZN. Pulmonary alveolar microlithiasis: report of four familial cases. *Chin Med J* 2004;117:950-952.

Gallbladder Stones

- M11. Abu-Ghazzeah YM. Pulmonary alveolar microlithiasis: High-resolution CT scan. *Ann Saudi Med* 2000;20:47-48.
- M12. Babu MK, Thomas JA. Pulmonary alveolar microlithiasis. *Indian J Pathol Microbiol* 1992;35:149-152.
- M13. Giallauria F, Giallauria G. Images in Thorax: Pulmonary alveolar microlithiasis. *Thorax* 2011;66:840.
- M14. Özmen İ, Ogun H, Yildirim E, Ak A, Çalışır HC. Pulmonary Alveolar Microlithiasis. *Respir Case Rep* 2014;3:97-100.

Kidney Stones

- M15. Badger TL, Gottlieb L, Gaensler EA. Pulmonary alveolar microlithiasis, or calcinosis of the lung. *N Engl J Med* 1955;253:709-715.
- M16. Jönsson ÅL, Hilberg O, Bendstrup EM, Mogensen S, Simonsen U. SLC34A2 gene mutation may explain comorbidity of pulmonary alveolar microlithiasis and aortic valve sclerosis. *Am J Respir Crit Care Med* 2012;185:464.

Prostatic Calcification

M17. Badger TL, Gottlieb L, Gaensler EA. Pulmonary alveolar microlithiasis, or calcinosis of the lung. N Engl J Med 1955;253:709-715.

M18. Bunger P, Fassbender CW, Schutze G. Zur Microlithiasis alveolaris pulmonum. Fortschr Roentgenstr 1962;97:775-779.

Urolithiasis and Colelithiasis

M19. Piesak P, Kasibowska-Kuzniar K, Jankowska R. Pulmonary Alveolar Microlithiasis in a patient with urolithiasis and cholelithiasis. Pneumonol Alergol Pol 2001;69:285-289.

Diagnostic procedures

M1. Biressi PC, Casassa PM. La microlitiasi polmonare endoalveolare. Min Med 1956;47:930-939.

M2. Harbitz F. Extensive calcification of the lungs as a distinct disease. Arch Intern Med 1918;21:139-146.

M3. Mariani B, Montanini N, Torelli G. La microlitiasi polmonare. Ann Ist C Forlanini 1947;10:179-199.

Radiologic aspects

R1. Balikian JP, Fuleihan CN, Nucho CN. Pulmonary alveolar microlithiasis. Report of five cases with special reference to roentgen manifestations. Am J Roentgenol Radium Ther Nucl Med 1968;103:509-518.

R2. Castellana G, Castellana R, Fanelli C, Lamorgese V, Florio C. La microlitiasi alveolare polmonare : decorso clinico e radiologico, convenzionale e HRCT, in tre casi. Ipotesi di classificazione radiologica della malattia. Radiol Med 2003;106:160-168.

- R3. Chang YC, Yang PC, Luh KT, Tsang YM, Su CT. High-Resolution computed tomography of pulmonary alveolar microlithiasis. *J Formos Med Assoc* 1999;98:440-443.
- R4. Helbich TH, Wojnarovsky C, Wunderbaldinger P, Heinz-Peer G, Eicher I, Herold CJ. Pulmonary Alveolar Microlithiasis in children: radiographic and high-resolution CT findings. *Am J Roentgenol* 1997;168:63-65.
- R5. Kino T, Kohara Y, Tsuji S. Pulmonary Alveolar Microlithiasis. *Am Rev Resp Dis* 1972;105:105-110.
- R6. Prakash UB, Barham SS, Rosenow EC, Brown ML, Payne WS. Pulmonary alveolar microlithiasis. A review including ultrastructural and pulmonary function studies. *Mayo Clin Proc* 1983;58:290-300.
- R7. Schmidt H, Lorcher U, Kitz R, Zielen S, Ahrens P, König R. Pulmonary alveolar microlithiasis in children. *Pediatr Radiol* 1996;26:33-36.
- R8. Sears MR, Chang AR, Taylor AJ. Pulmonary alveolar microlithiasis. *Thorax* 1971;26:704-711.
- R9. Volle E, Kaufmann HJ. Pulmonary alveolar microlithiasis in pediatric patients: Review of the world literature and two new observations. *Pediatr Radiol* 1987;17:439-442.

Differential diagnosis

5 cases of Pulmonary Alveolar Microlithiasis and associated Tuberculosis

- T1. Bhatia JT, Thind GS. Pulmonary alveolar microlithiasis. *Indian J Tuberculosis*. 1976;33:110.
- T2. Samano MN, Waisberg DR, Canzian M, Campos SV, Pêgo-Fernandes PM, Jatene FB. Lung transplantation for pulmonary alveolar microlithiasis: a case report. *Clinics (Sao Paulo)* 2010;6:233-236.

T3. Takahashi H, Chiba H, Shiratori M, Tachibana T, Abe S. Elevated serum surfactant protein A and D in pulmonary alveolar microlithiasis. *Respirology* 2006;11:330-333.

T4. Uçan ES, Keyf AI, Aydılek R, Yalcin Z, Sebit S, Kudu M, Ok U. Pulmonary alveolar microlithiasis: review of Turkish reports. *Thorax* 1993;48:171-173. (2 cases)

Cases of Pulmonary Alveolar Microlithiasis misdiagnosed of Tuberculosis

T5. Adnet JJ, Blanchard J, Gaillard D, Lebreuil G. La microlithiase alvéolaire: étude en microscopie électronique et en immunofluorescence d'une biopsie pulmonaire. *Arch Anat Cytol Path* 1981;29:105-108.

T6. al Damluji SF, al-Omari MM, al-Fakhri S. Pulmonary Alveolar Microlithiasis in two siblings from Iraq. *Br J Dis Chest* 1973;67:246-252. (2 cases)

T7. Al-Alawi AS. Familial occurrence of pulmonary alveolar microlithiasis in 3 siblings. *Saudi Med J* 2006;27:238-240.

T8. Albayrak D, Ecer TN, Taştepe I, Alpay D, İşlek I. Pulmonary alveolar microlithiasis: a case report. *Turkiye Klinikleri J Pediatr* 1993;2:145-147.

T9. Azim S, Azim W, Hayat F, Shafi H. Treatment of pulmonary alveolar microlithiasis with allendronate sodium. *Biomedica* 2004;20:32-35. (2 cases)

T10. Babu MK, Thomas JA. Pulmonary Alveolar Microlithiasis. *Indian J Pathol Microbiol* 1992;35:149-152.

T11. Bhatt S, Luqman-Arafath T, Mohan A, Gularia R. A rare cause of dyspnoea. *Postgrad Med J* 2007;83:1-2.

T12. Bunger P, Fassbender CW, Schutze G. Zur Microlithiasis alveolaris pulmonum. *Fortschr Roentgenstr* 1962;97:775-779.

T13. Cetrángolo R, Guman N, Bordo HH, Costa AB, Jurado M. Microlithiasis alveolar pulmonar. *Rev Asoc Méd Argent* 1966;80:306-312. (2 cases)

- T14. Chandra S, Mohan A, Guleria R, Das P, Sarkar C. Bilateral stony lung: Pulmonary alveolar microlithiasis. *BMJ Case Rep* 2009. doi:10.1136/bcr.09.2008.1012.
- T15. Fiore CA, Duarte-Sotelo L, Vázquez S, Mirofsky M, Bauni C. Imágenes en Medicina: Microlitiasis alveolar pulmonar. *Medicina* 2006;66:50.
- T16. Freour P, Laumonier P, Verger P, Germouty R, Cardinaud JP. Les microlithiases pulmonaires alvéolaires. *J Méd Bordeaux* 1959;4:459-466.
- T17. Gaber KA, Najem SA, Twair A, Dharrat A. Pulmonary Alveolar Microlithiasis In Living Adult Monozygotic Twin; CT Scan Versus CXR Family Screening Results. Doi:10.1164/ajrccm-conference.2012.185.1_MeetingAbstracts.
- T18. Galhotra R, Gupta K. Pulmonary Alveolar Microlithiasis. *J Pulmon Resp Med* 2012;2:1000124.
- T19. Gayatri Devi HJ, Mohan Rao KN, Prathima KM, Das JK. Pulmonary alveolar microlithiasis. *Lung India* 2011;28:139-141.
- T20. Grube-Pagola P, Carrasco-Daza D, Pérez-Fernández L, Alvarado-Rodríguez JE. Microlitiasis alveolar pulmonar, informe de un caso pediátrico con revisión de los casos en México. *Patología* 2009;47:242-245.
- T21. Jankovic S, Pavlov N, Ivkovic A, Erceg I, Glavina-Durdov M, Tocily J, Dragisic-Ivulic S, Primorac D. Pulmonary Alveolar Microlithiasis in Childhood: Clinical and Radiological Follow-up. *Pediatric Pulmonology* 2002;34:384-387.
- T22. Kent G, Gilbert ES, Meyer HH. Pulmonary Microlithiasis. *Brit J Dis Chest* 1955;58:556-562.
- T23. Kiatboonsri S, Charoenpan P, Vathesatogkit P, Boonpucknavig V. Pulmonary Alveolar Microlithiasis: Report of five cases and literature review. *J Med Assoc Thai* 1985;68:672-677.

- T24. Kino T, Kohara Y, Tsuji S. Pulmonary Alveolar Microlithiasis. *Am Rev Resp Dis* 1972;105:105-110.
- T25. Lee YC, Milne D, Rea HH. Pulmonary alveolar microlithiasis: an alternative diagnosis to miliary tuberculosis. *Aust NZ J Med* 1997;27:336-337.
- T26. Lema LEK, Munema FM, Gordon G. Pulmonary Alveolar Microlithiasis: case report. *East Afr Med J* 1989;66:365-367.
- T27. Lopez-Areal L, Zumárraga R, Gil-Turner C, Martín-Granizo IF, Vara Cuadrado F, Duque Fraile J. Microlitiasis alveolar pulmonar familiar e infantil. *Rev Clin Esp* 1965;97:389-395.
- T28. Mándi L, Simay A, Kelemen JT, Szabó A, Dayka Á. Microlithiasis alveolaris pulmonum. *Orv Hetil* 1968;7:1463-1466.
- T29. Marc K, Bourkadi JE, Jahid A, Cherradi N, Benamor J, Mahassini N, Fassy MT, Iraqi G. La microlithiase alvéolaire pulmonaire: à propos de quatre cas. *Revue Pneumologie Clinique* 2008;64:221-224.
- T30. Mitra S, Ghoshal AG. A family of pulmonary alveolar microlithiasis. *Lung India* 2000;18:97-100.
- T31. Moreno-Camacho A, Miro JM, Coca-Payeras A, Camacho L, Mensa Pueyo J, Sasal M, Marin A, Segura F, Soriano E. Microlithiasis alveolar pulmonar. Dos nuevos casos en hermanos. *Rev Clin Esp* 1981;160:275-277.
- T32. Nouh MS. Is the Desert Lung Syndrome (Nonoccupational Dust Pneumoconiosis) a Variant of Pulmonary Alveolar Microlithiasis? *Respiration* 1989;55:122-126.
- T33. Petit MA, Hamladji O, Vedrenne C, Haddam T, Cernay J. Special case of pulmonary alveolar microlithiasis with added tuberculous infection. *Rev Tuberc Pneumol* 1968;32:438-447. (2 cases)

- T34. Petitjean R, Bierry JP, Burghard G. Microlithiase Alvéolaire. Le Poumon et Le Coeur 1975;31:145-148.
- T35. Pivetaud J. A propos d'un cas de microlithiase alveolaire. Le diagnostic des images miliaries. Maroc Med 1960;427:1322-1327.
- T36. Qiu H, Wei G, Zhang Q, Yu X, Meng F. Pulmonary alveolar microlithiasis: presentation of three cases. Chin J Clinicians 2011;5:3391-3394.
- T37. Raffa H, El-Dakhakny M, Al-Ibrahim K, Mansour MS. Single lung transplantation for alveolar microlithiasis: The first clinical report. Saudi J Kidney Dis Transpl 1996;7:189-193.
- T38. Rakusic N, Radosevic Z. Microlitiasis alveolar pulmonar. Presentación familiar en dos hermanas. An Med Intern 1991;8:445-447.
- T39. Ravines HT. Pulmonary alveolar microlithiasis. Report of nine cases with familial incidence in seven of the nine cases among three families. Am J Clin Pathol 1969;52:767.
- T40. Ribo JL, Camps F, Barnadas M, Manzanares R, Medina M. Microlithiasis alveolar pulmonar. 1985;27:27-30.
- T41. Saleem A, Chaudhary A, Iqbal ZH. Pulmonary Alveolar Microlithiasis. J College Physicians Surgeons Pakistan 2009;19:391-392.
- T42. Sambasiva Rao C, Madhusudhana Rao Y, Bhaskara Reddy D, Sarada D. Pulmonary Alveolar Microlithiasis. J Ind Med Assoc 1968;50:427.
- T43. Sclafani G, Piga C. La microlitiasi endoalveolare del polmone: descrizione di due casi in fratelli. Riv Clin Pediat 1968;81:1338-1340. (2 cases)
- T44. Sears MR, Chang AR, Taylor AJ. Pulmonary alveolar microlithiasis. Thorax 1971;26:704-711.

- T45. Senyigit A, Yaramiş A, Gürkan F, Kirbaş G, Büyükbayram H, Nazaroglu H, Alp MN, Topçu F. Pulmonary alveolar microlithiasis: a rare familial inheritance with report of six cases in a family. *Respiration* 2001;68:204-209. (3 cases)
- T46. Sharma SK, Sharma S, Mukhopadhyaya S, Padhy AK, Vijayraghavan M. Pulmonary Alveolar Microlithiasis. *Indian J Chest Dis Allied Sci* 1992;34:205-215.
- T47. Shishido S, Toritani T, Nakano H, Tokushima T. A case of alveolar microlithiasis which developed spontaneous pneumothorax due to progression of emphysematous bullae during 34 years after established diagnosis. *Nippon Kyobu Shikkan Gakkai Zasshi* 1993;31:881-885.
- T48. Singh M, Saini AG, Mathew J, Nahar U, Vaiphei K. Pulmonary Alveolar Microlithiasis in Children: Case Series and Review of Literature. *Pediatric Allergy, Immunology and Pulmonology* 2011;24:221-224. (2 cases)
- T49. Singh NK, Gupta A. Pulmonary Alveolar Microlithiasis. *J Assoc Physicians India* 1995;43:647-648.
- T50. Taneja VP, Sen D. Pulmonary Alveolar Microlithiasis. *J Asso Phys Ind* 1981;29:411-414.
- T51. Tanrikuku AÇ, Dağlı EC, Şenyiğit A, Nazaroğlu H, Babayiğit C. Pulmonary Alveolar Microlithiasis: Radiologic Findings of Eight Cases in Turkey. *Turkiye Klinikleri J Med Sci* 2010;30:713-20. (4 cases)
- T52. Thind GS, Bathia JL. Pulmonary Alveolar Microlithiasis. *Br J Dis Chest* 1978;72:151-154. (2 cases)
- T53. Turktas H, Ozturk C, Guven M, Ugur P, Erzen C. Pulmonary Alveolar Microlithiasis with the absence of Technetium-99m MDP Uptake of Lungs. *Clin Nucl Med* 1988;13:883-885.

- T54. Uçan ES, Keyf AI, Aydilek R, Yalcin Z, Sebit S, Kudu M, Ok U: Pulmonary alveolar microlithiasis: review of Turkish reports. *Thorax* 1993;48:171-173. (13 cases)
- T55. Uddin SF, Alawi MH, Abdulshakoor BM. Pulmonary Alveolar Microlithiasis. *Saudi Medical Journal* 2004;5:663-666.
- T56. Usui M, Watanabe M, Hattori J, Horie K, Shima H.A case of pulmonary alveolar microlithiasis. *Nippon Kyobu Shikkan Gakkai Zasshi* 1993;31:501-505.
- T57. Varma BN. Pulmonary alveolar microlithiasis in a child of 13 years. *Br J Dis Chest* 1963;57:213-215.
- T58. Waters HM. Microlithiasis alveolaris pulmonum. *Tubercle* 1960;41:276-278.
- T59. Yang Y, Qiao JH, An JH, Zhang Y, Yu T, Jia B, Ma ZS. Detection of SCL34A2 in patients with pulmonary alveolar microlithiasis and the effect of SCL34A2 on transportation of calcium and phosphate in human alveolar epithelial cells. *Zhonghua Jie He He Hu7 Xi Za Zhi* 2008;31:908-911.
- T60. Ye Feng, Xie J, Zhang N, Zhong S, Chen G, Zhong N. Pulmonary alveolar microlithiasis: report of three cases and literature review. *Int J Respir* 2011;31:1394-1398.
- T61. Yenel F, Küçükusta AR. Bir akciğer microlithiasis olgusu. *Cerrahpaşa Tıp Fak Der* 1984;15:133-137.
- T62. Yurdakul AS, Mutlu I, Firat Güven S, Eren A, Şipit T. Alveoler Mikrolitiazis. *Solunum Hastalıkları* 2003;14:58-61.
- T63. Zegaya M, Djemel A, Ladjimi S, Kammoun M, Jeguirim M, Smaoui M, Kouzana N. La microlithiase alvéolaire pulmonaire. *Poumon-Cœur* 1983;39:253-256.