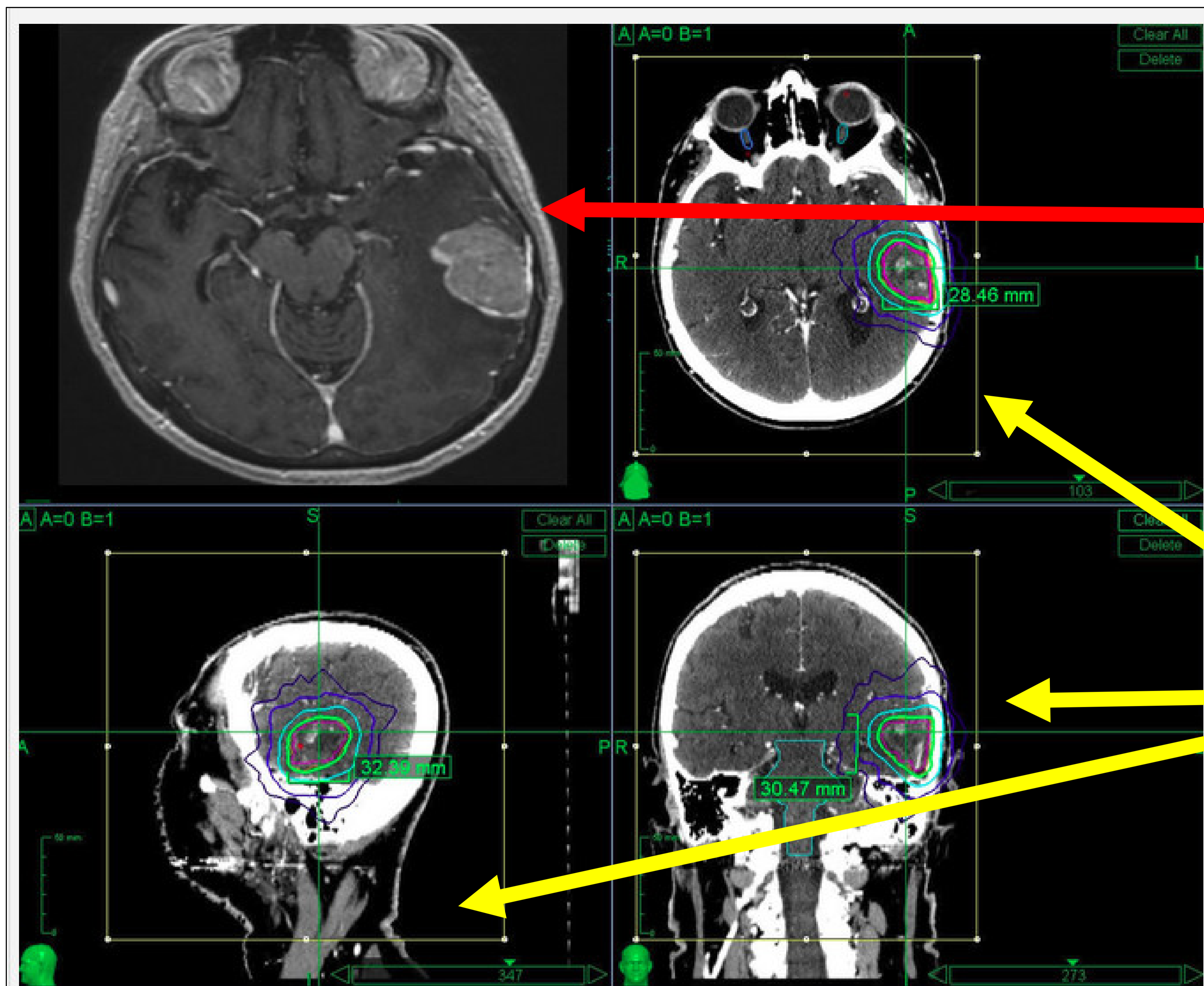


Example Survey Element

Screenshot from presurgical MRI

Screenshot of treatment planning for postoperative SRS

Questions to answer using the MRI DICOM file and MIMviewer software



For the case labeled "Case 1", which of the following features do you believe is present in the image?

* must provide value

- Local Recurrence
- Distant Recurrence
- Leptomeningeal Disease

How confident are you in your above annotation on a 1-5 scale? (where 1 = very uncertain and 5 = extremely confident)

* must provide value

- 0 1 2 3 4