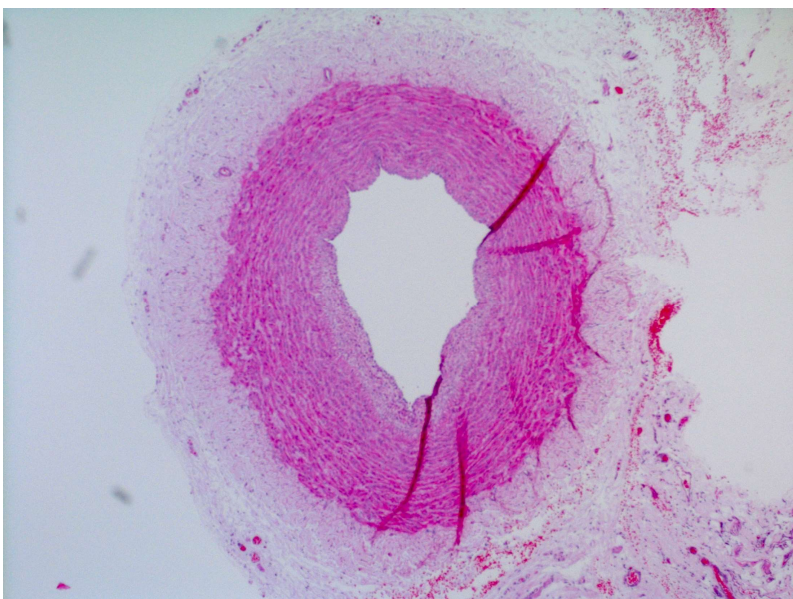
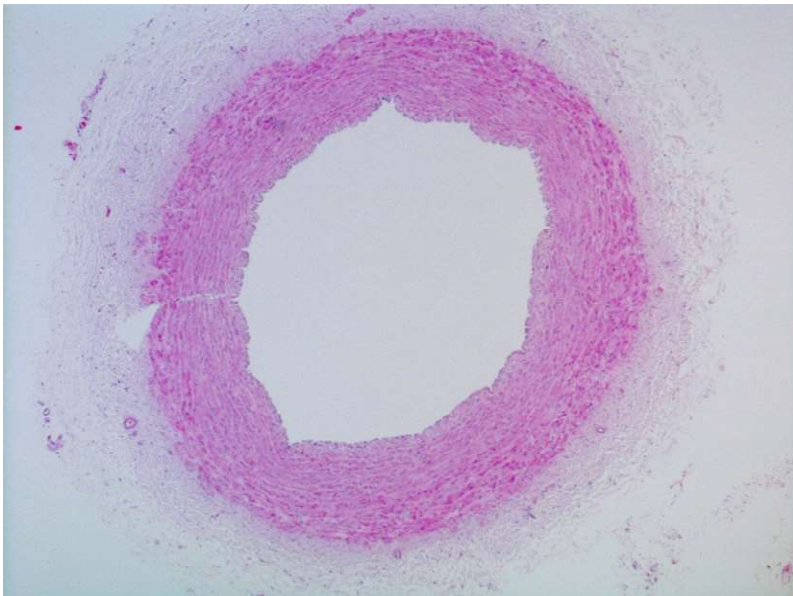
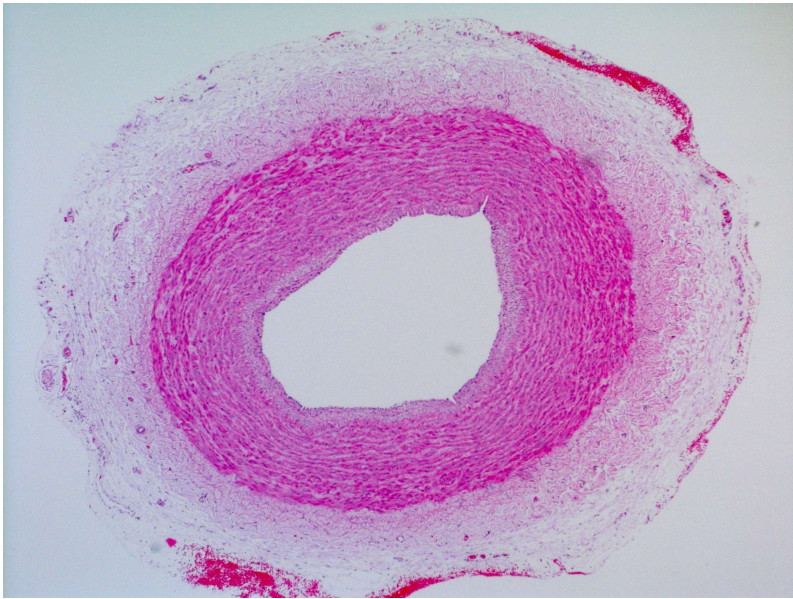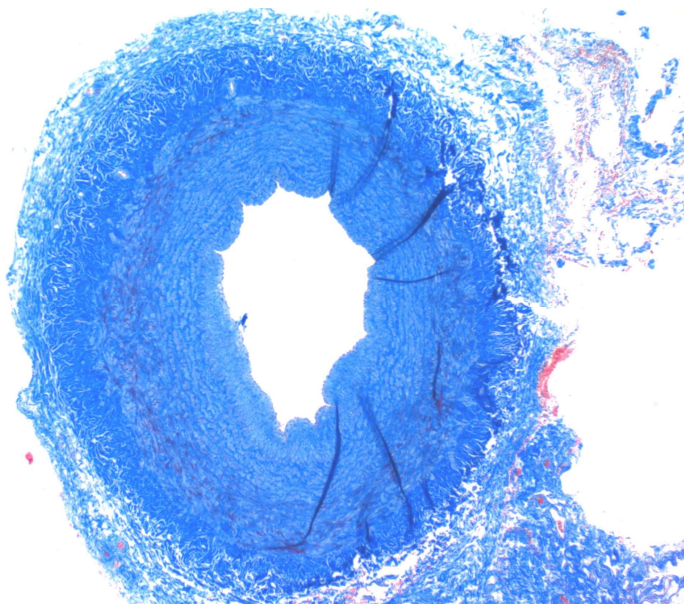




Raw histopathology images

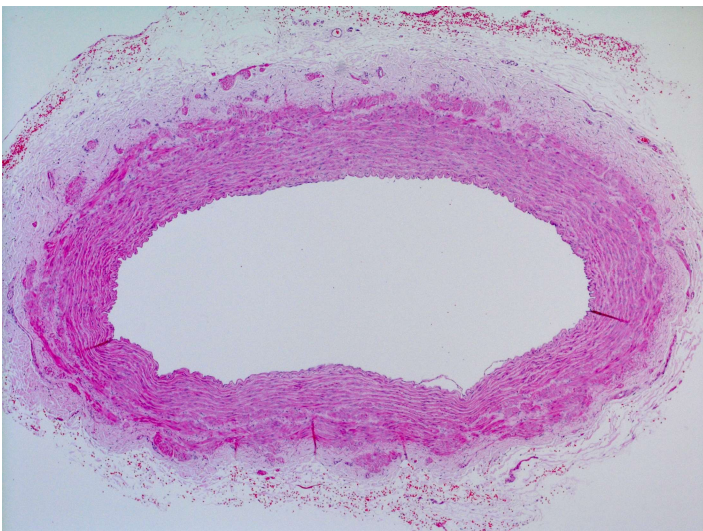
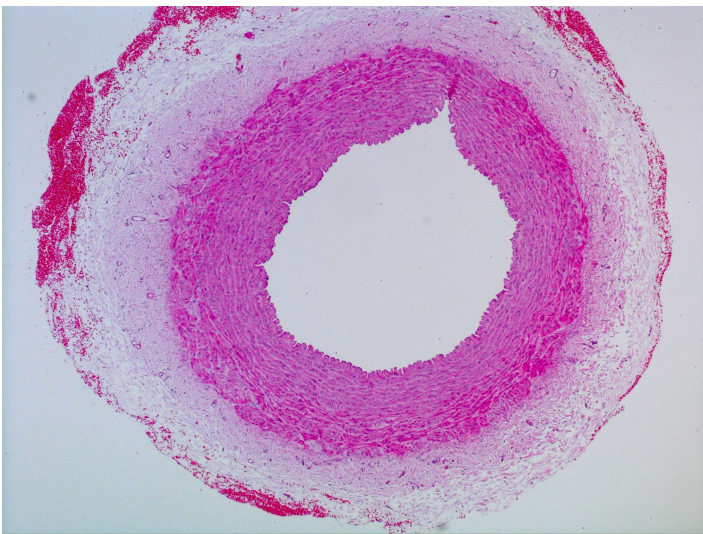
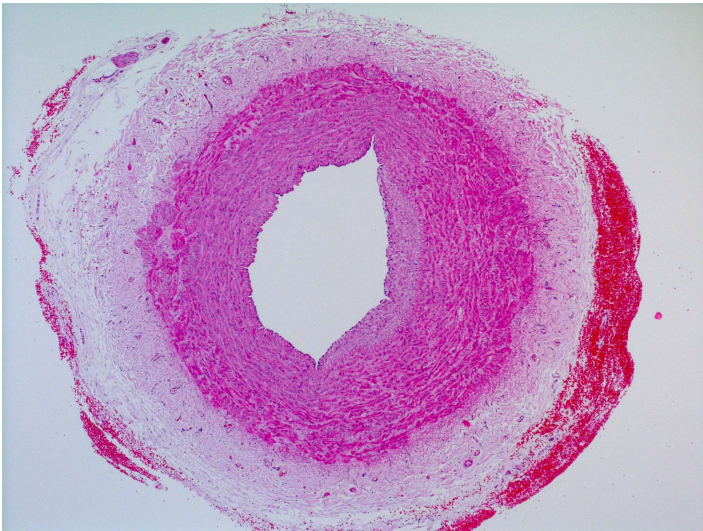
No.1 H&E (50X)



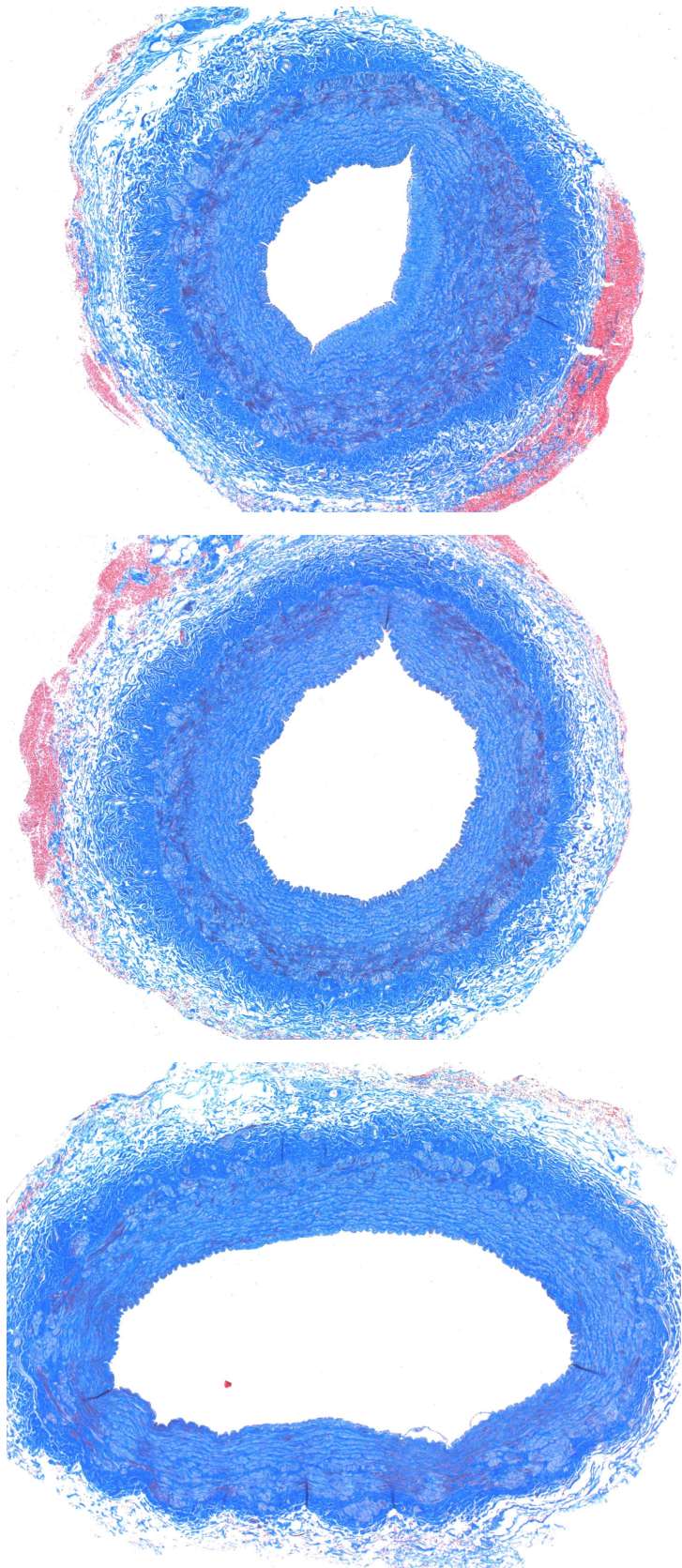
No.1 Masson's Trichrome (50X)



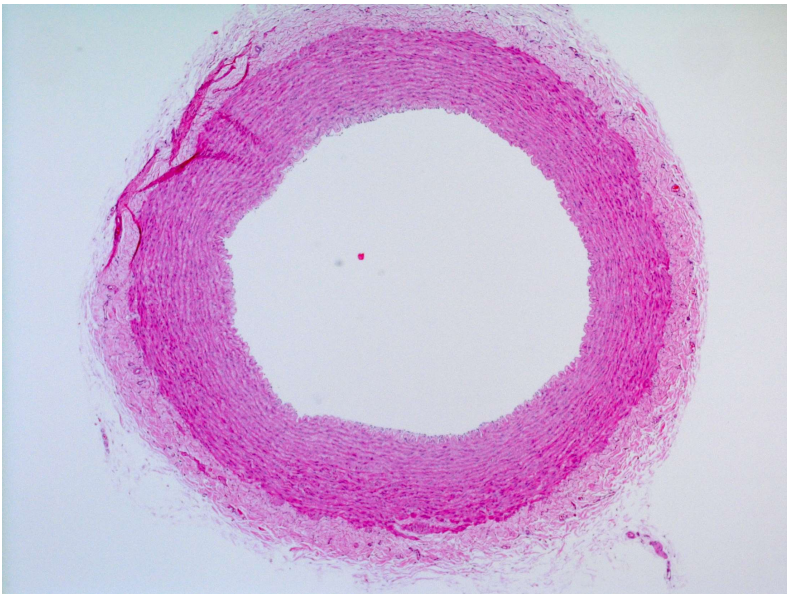
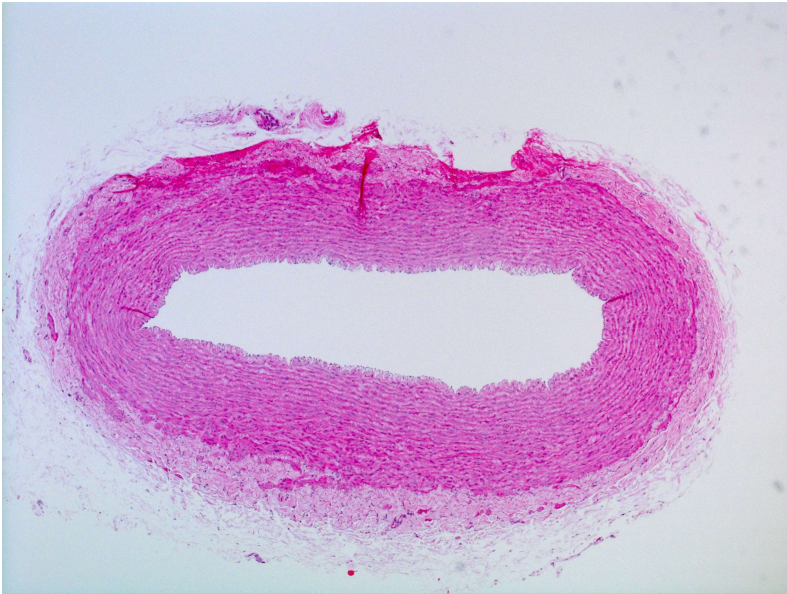
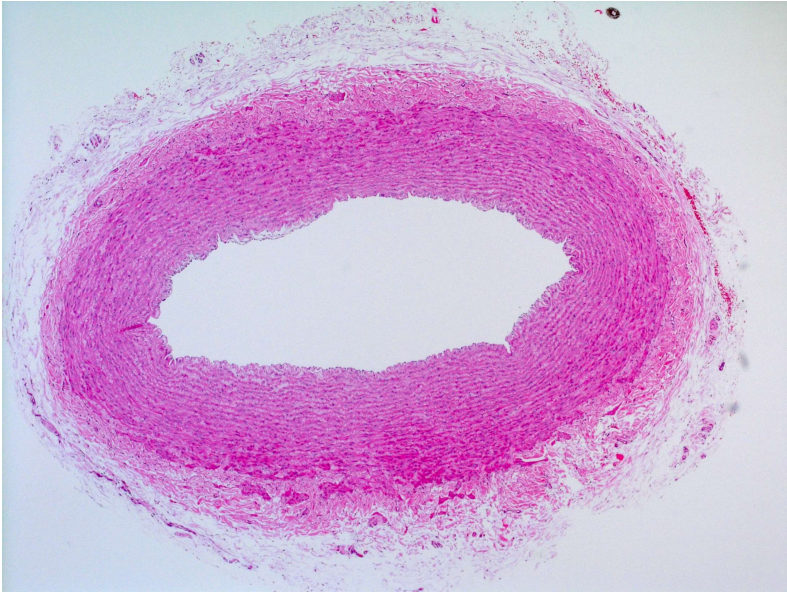
No.2 H&E (50X)



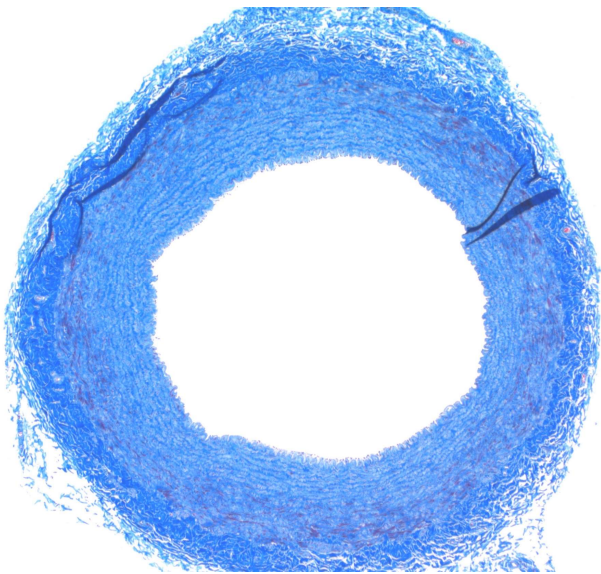
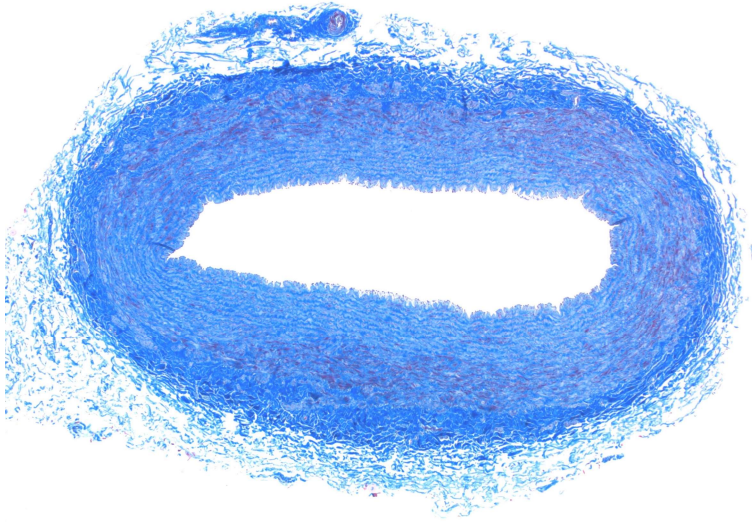
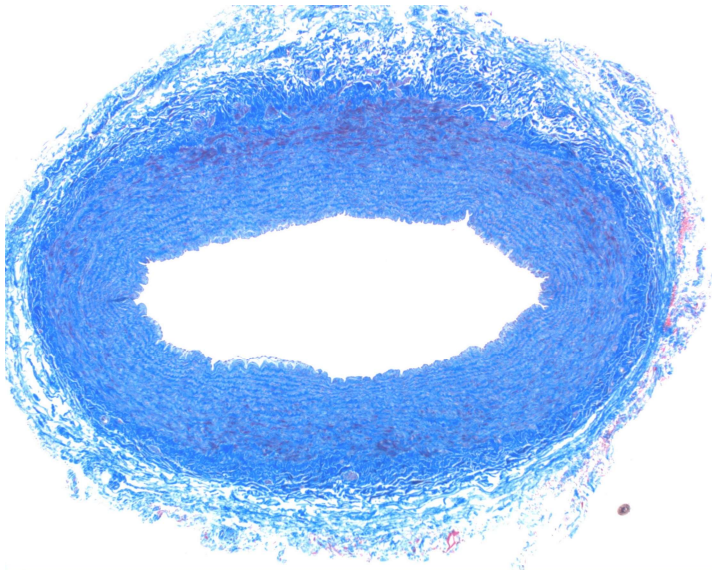
No.2 Masson's Trichrome (50X)



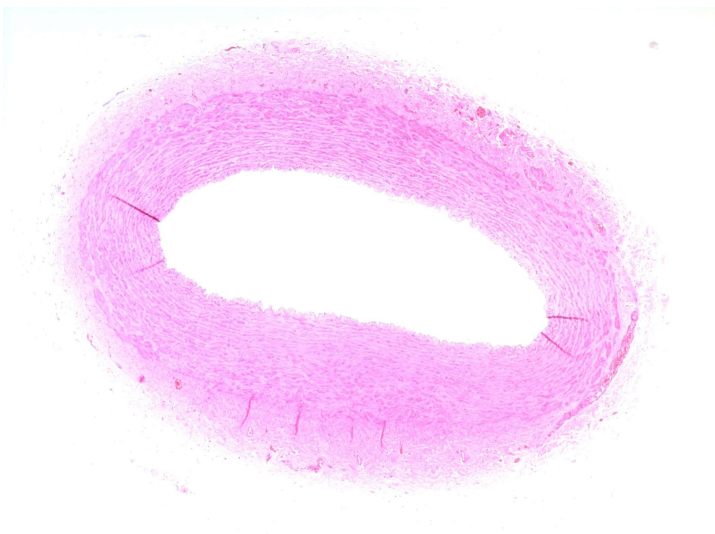
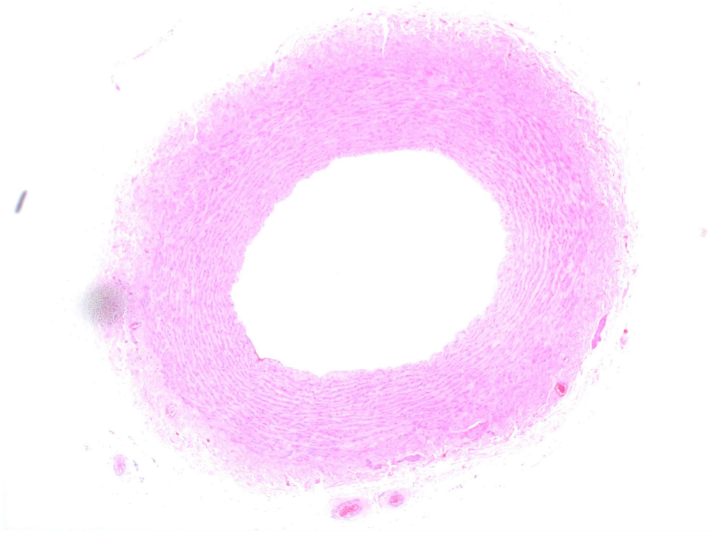

No.3 H&E (50X)



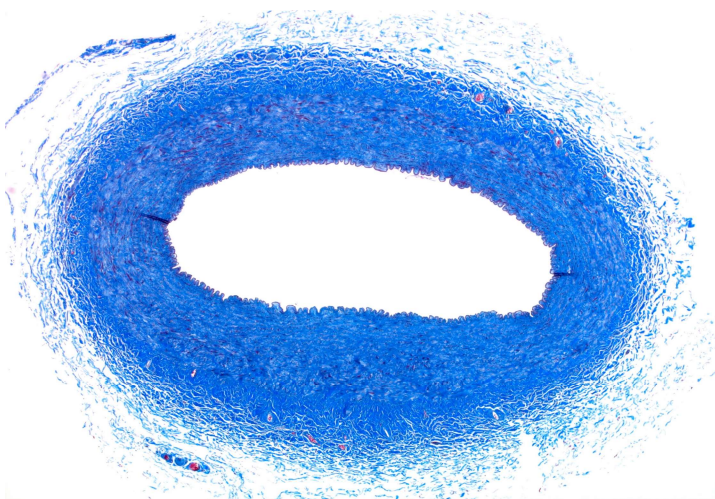
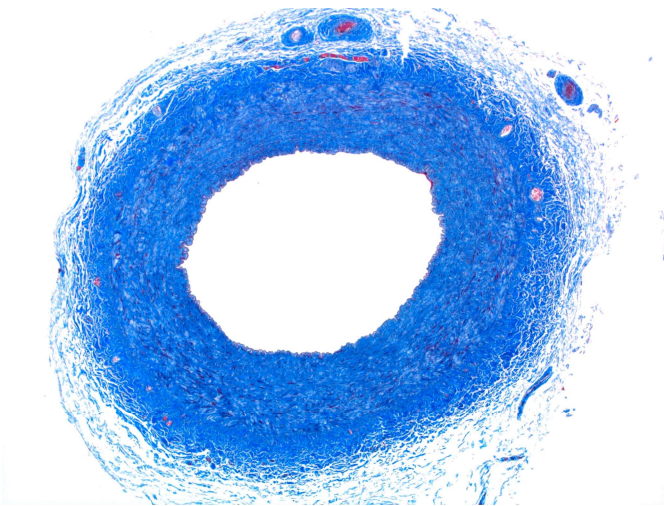
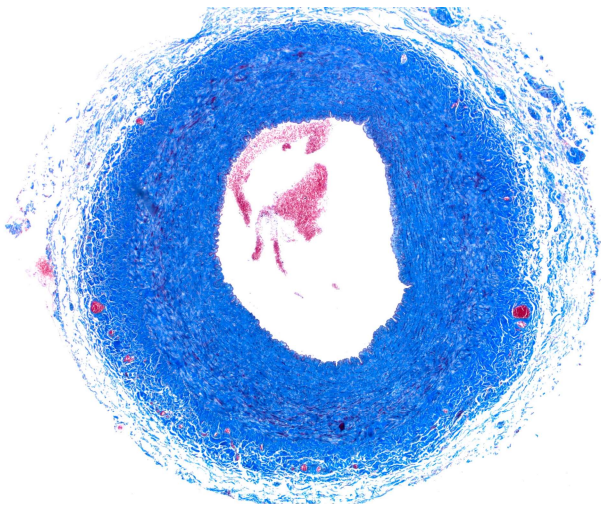
No.3 Masson's Trichrome (50X)




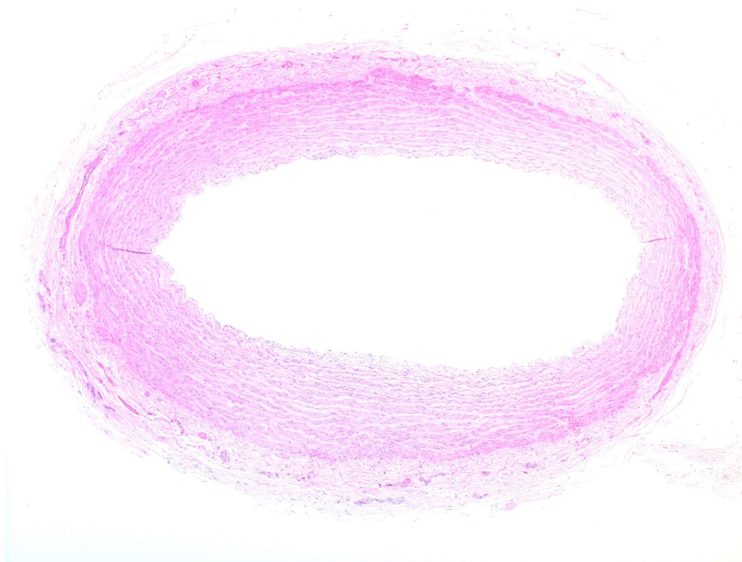
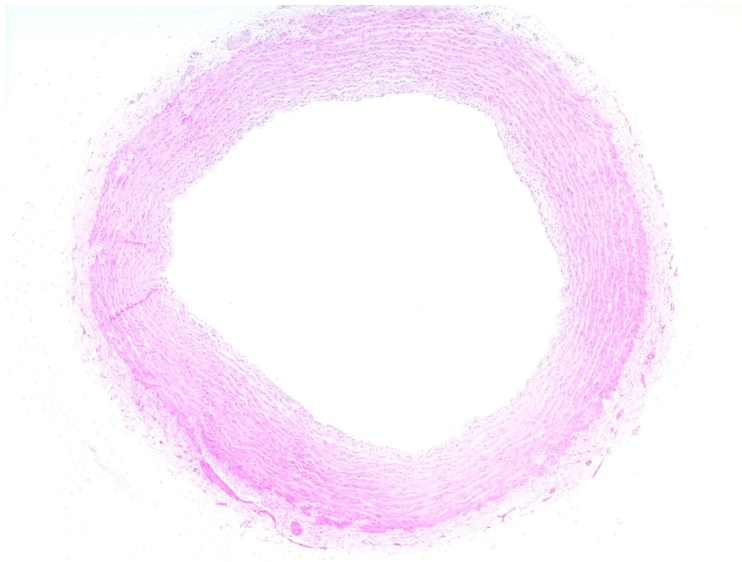
No.4 H&E (50X)



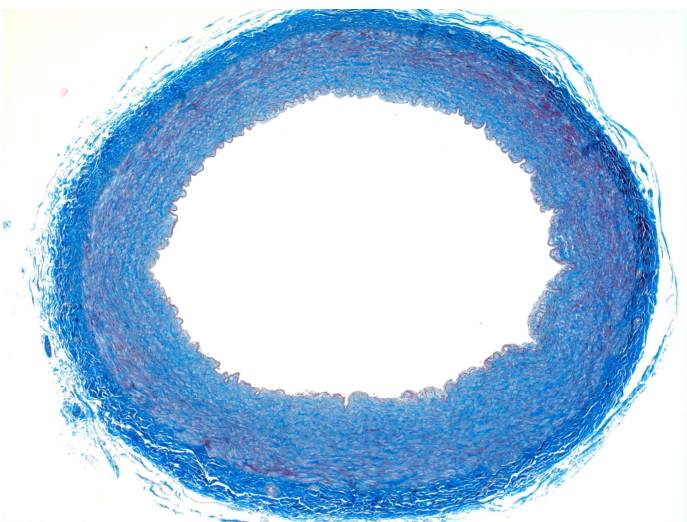
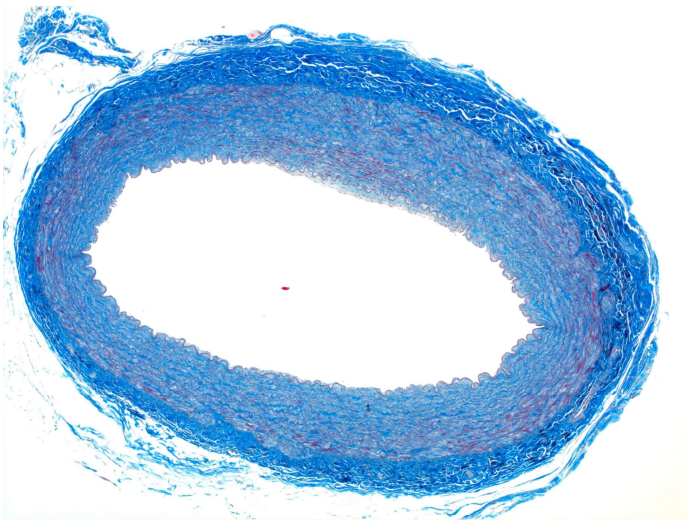
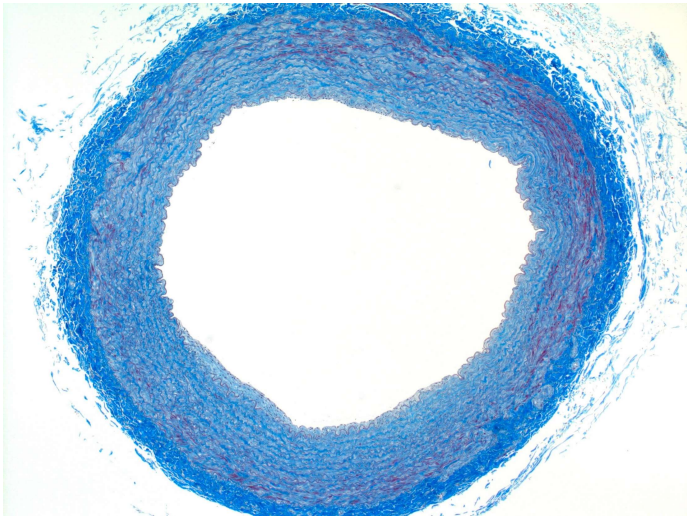
No.4 Masson's Trichrome (50X)




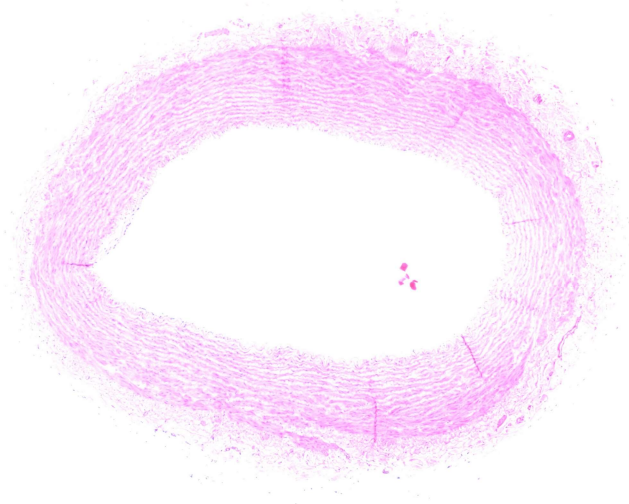
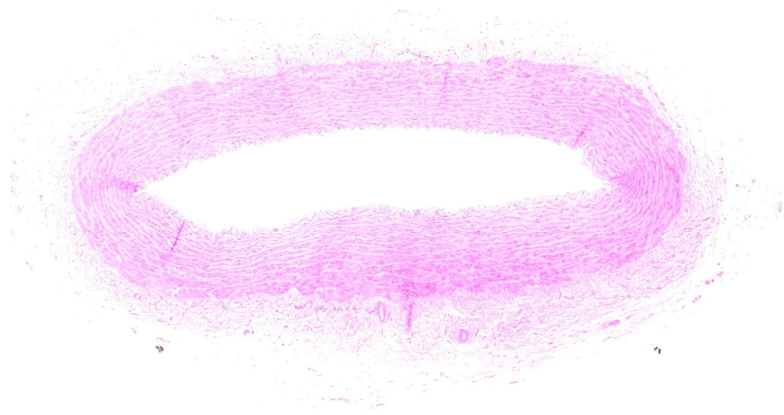
No.5 H&E (50X)



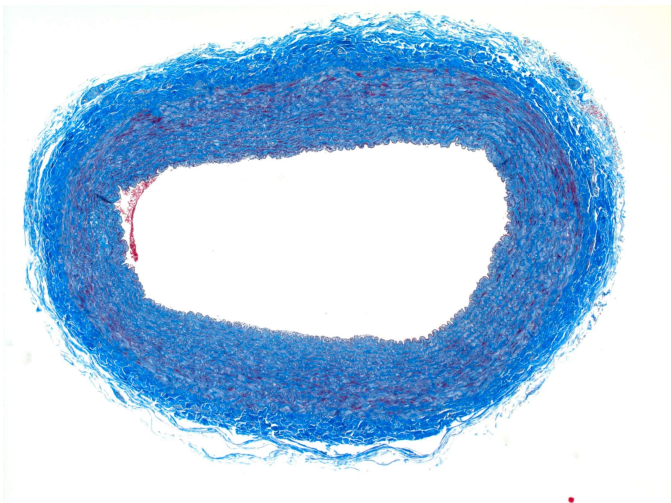

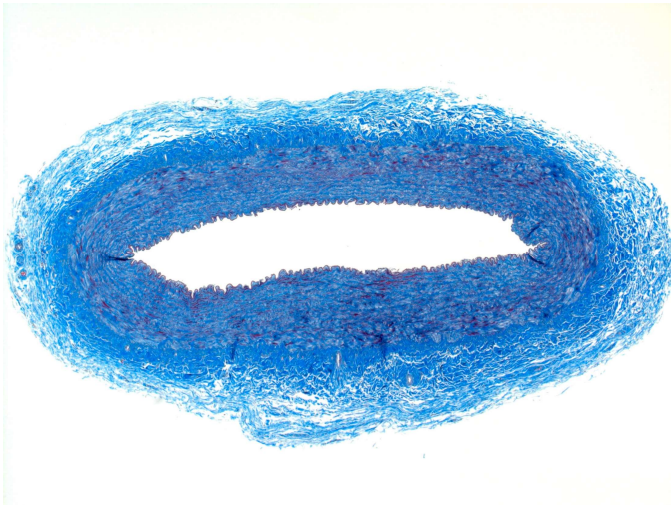
No.5 Masson's Trichrome (50X)



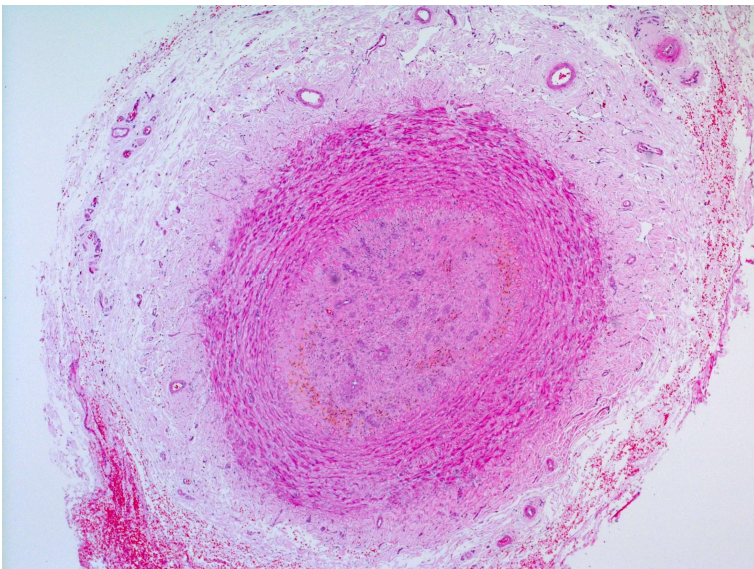
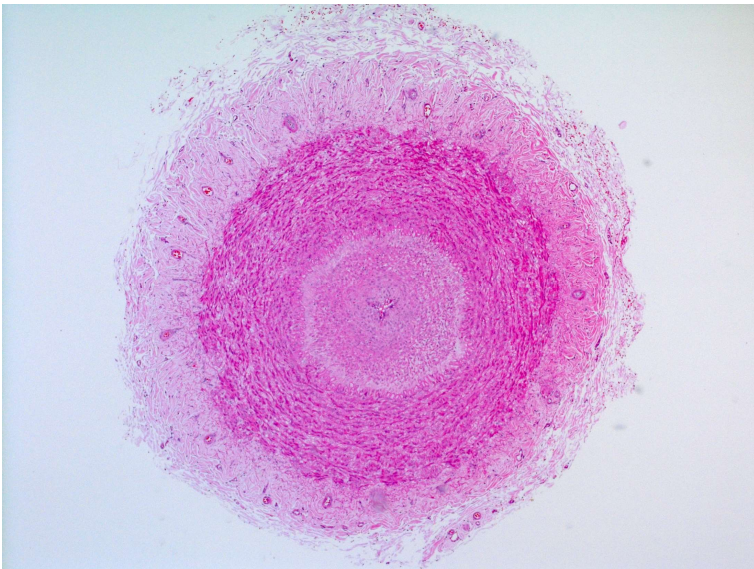
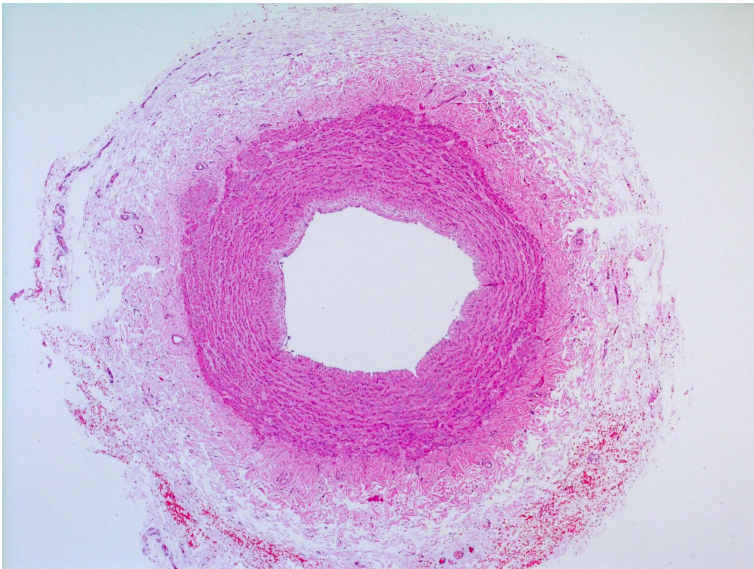
No.6 H&E (50X)



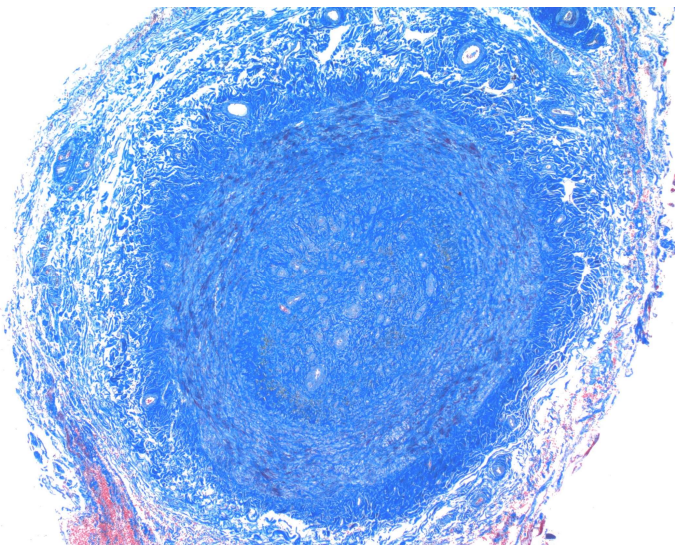

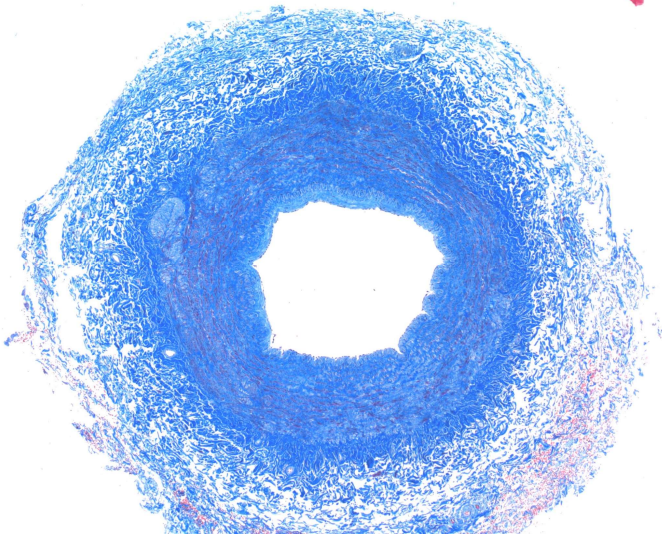
No.6 Masson's Trichrome (50X)



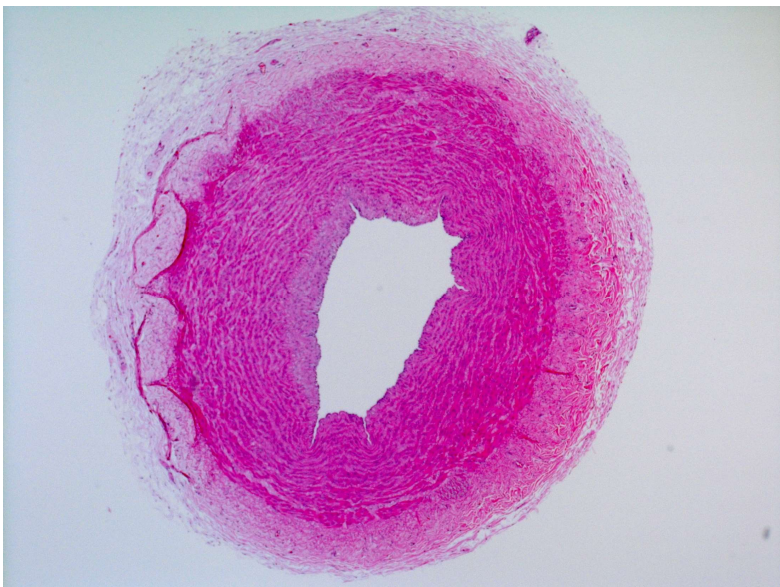
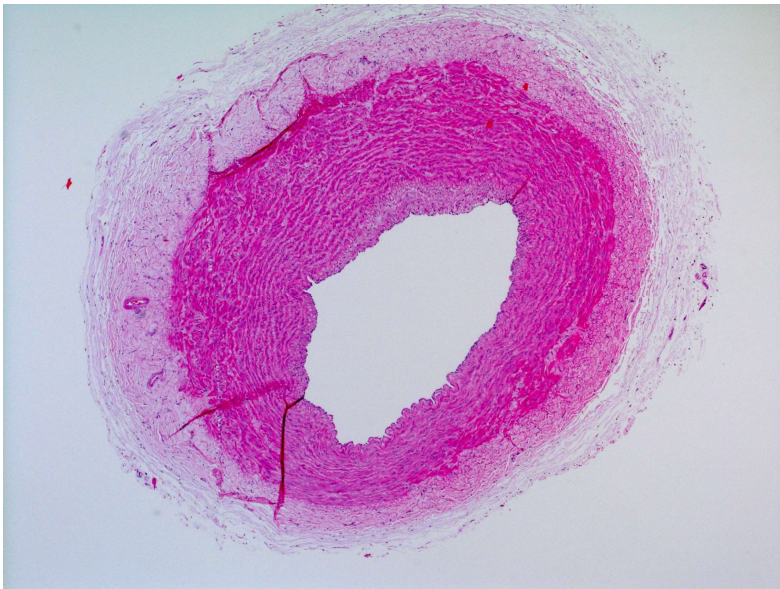
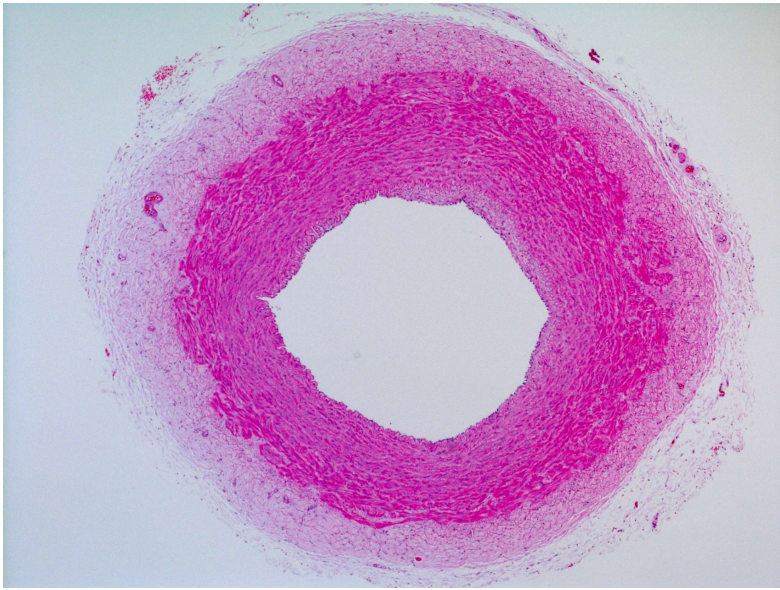
No.7 H&E (50X)




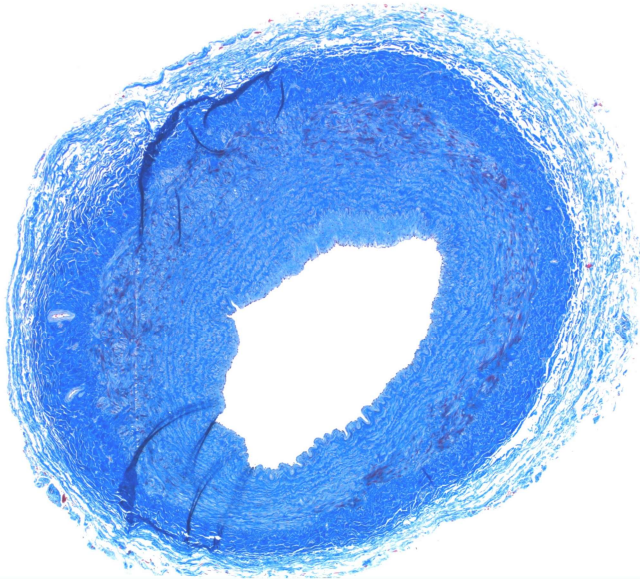
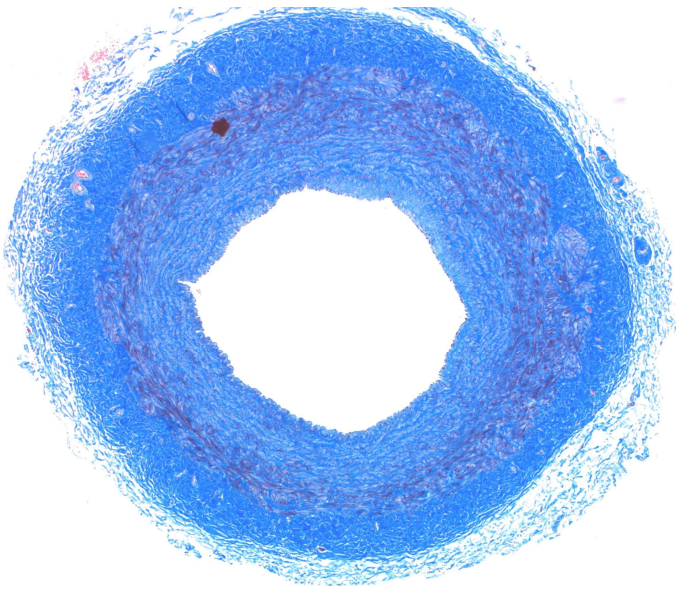
No.7 Masson's Trichrome (50X)



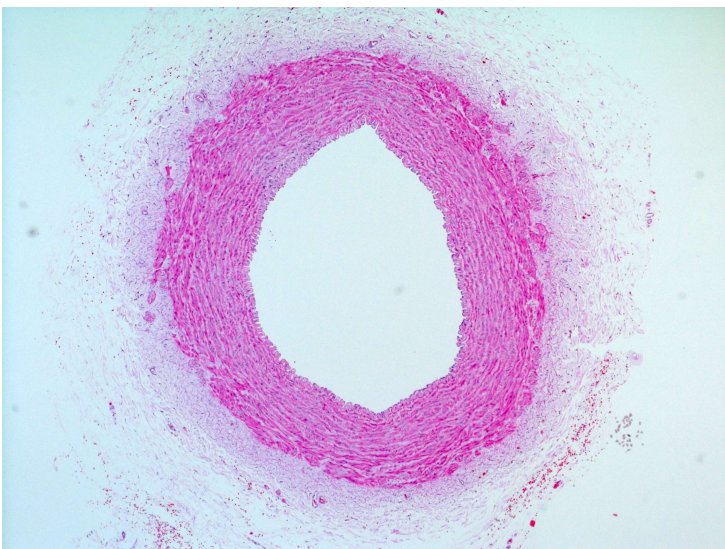
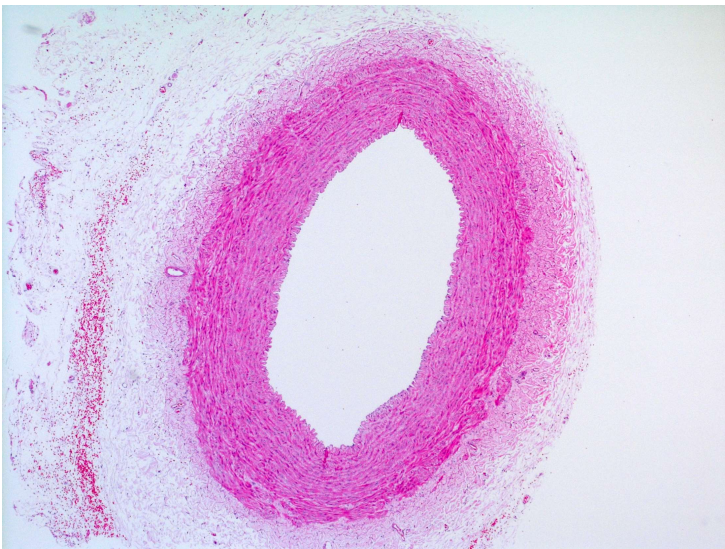
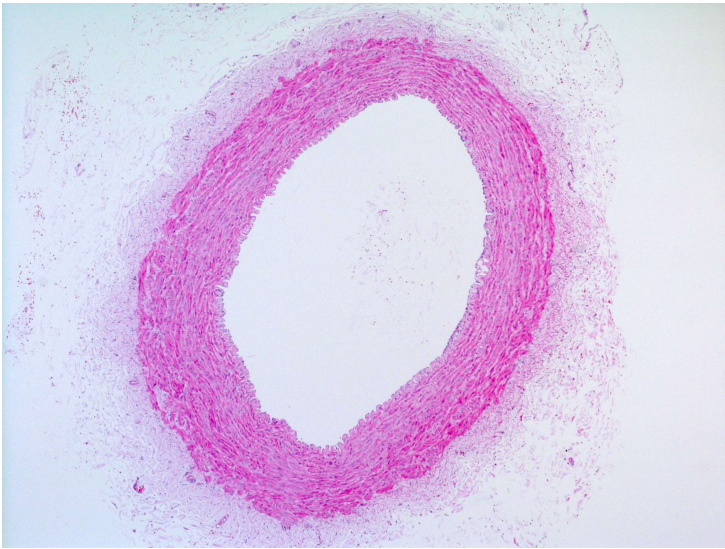
No.8 H&E (50X)



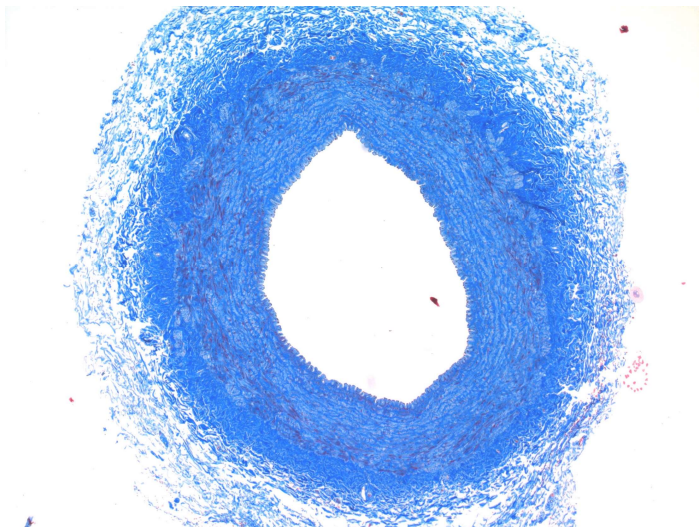
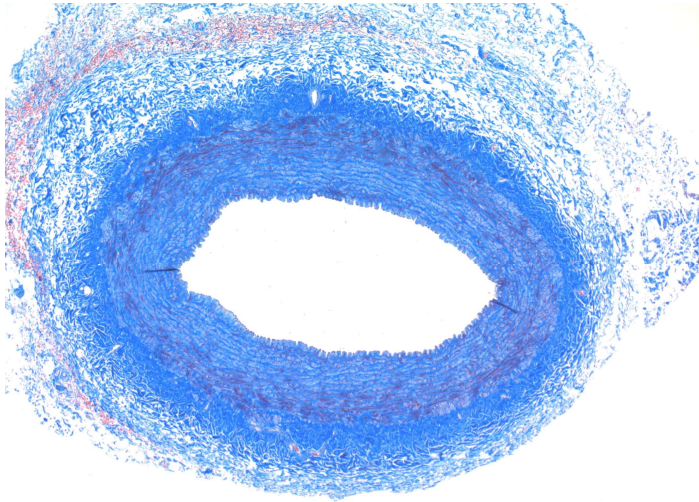

No.8 Masson's Trichrome (50X)






No.9 H&E (50X)



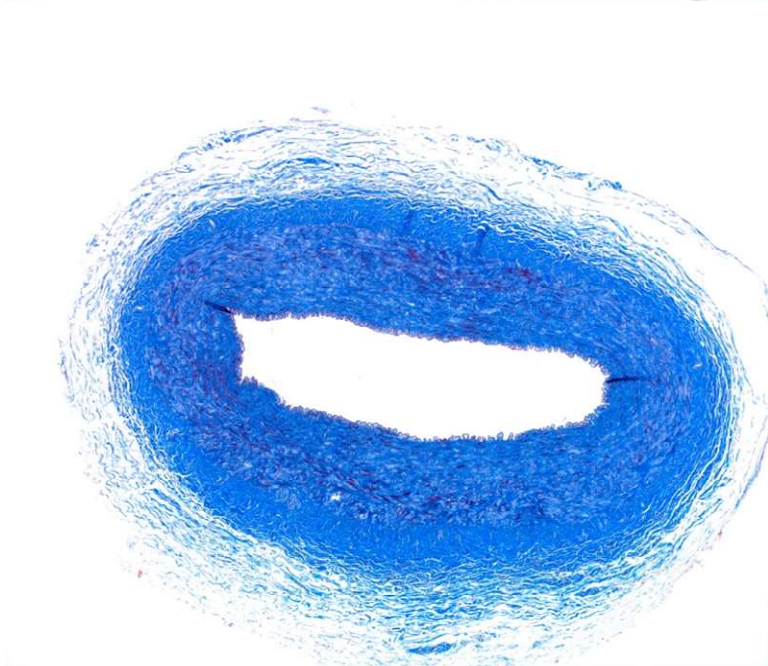
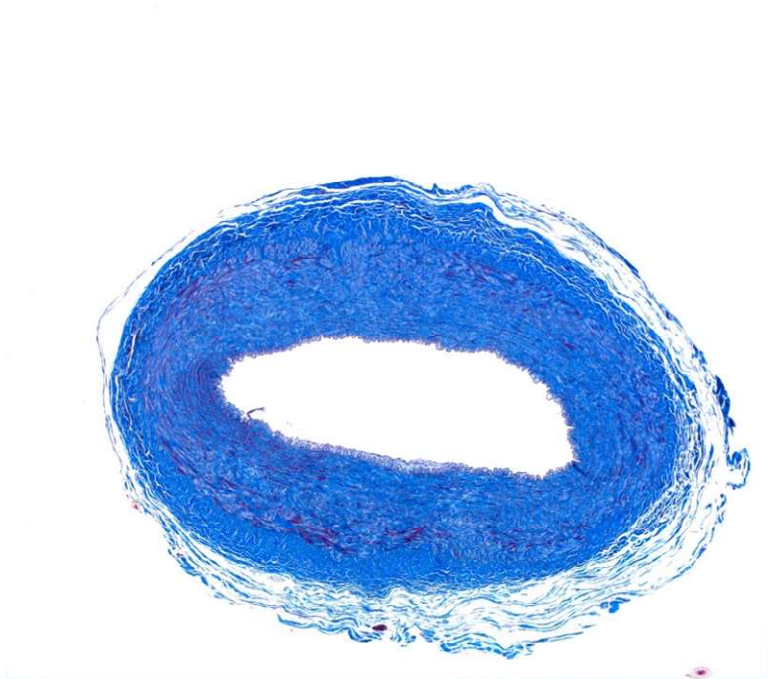
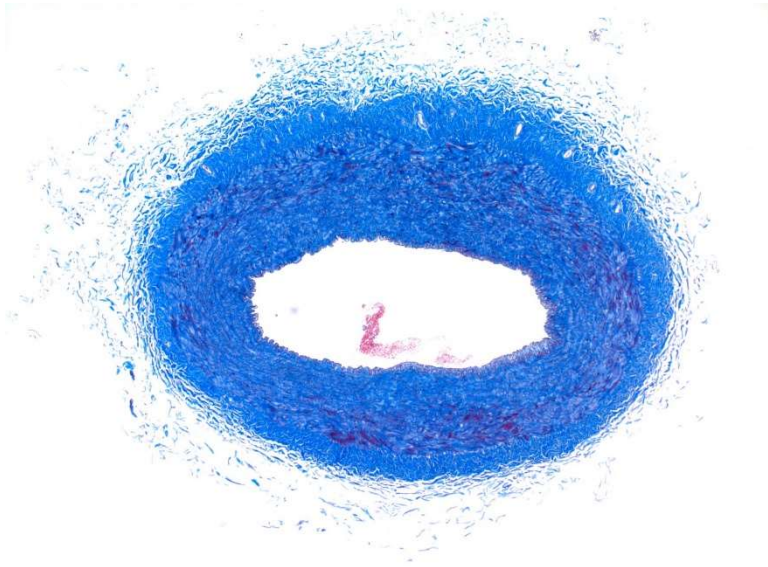
No.9 Masson's Trichrome (50X)



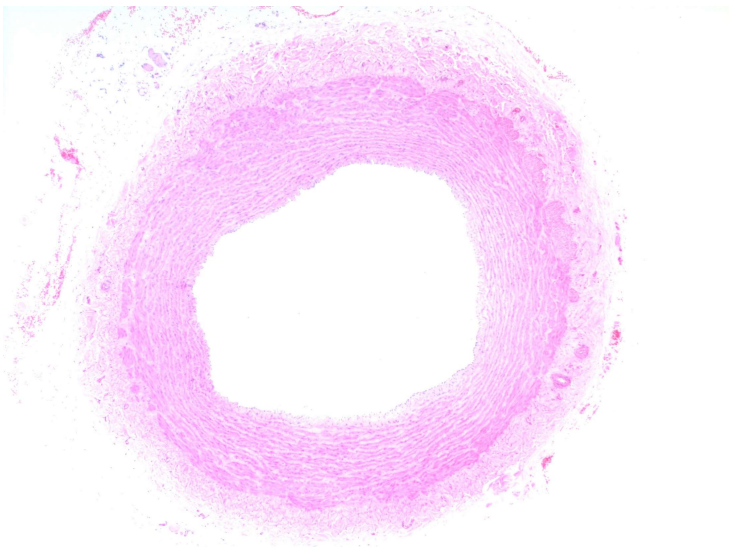

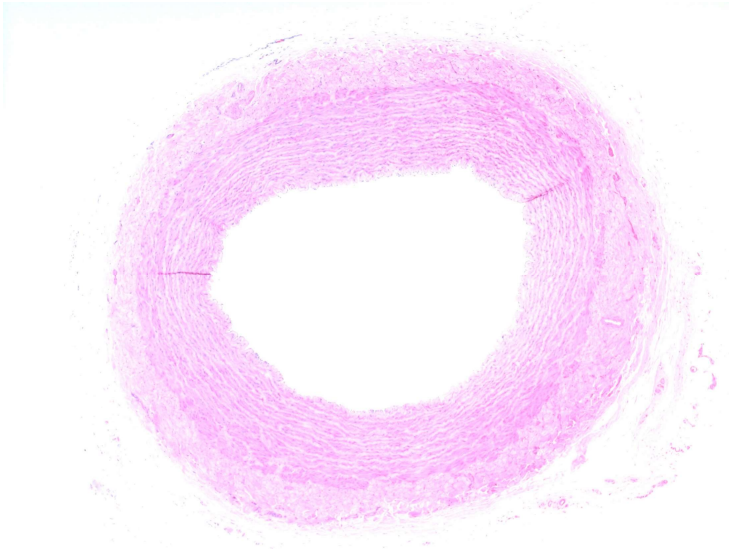
No.10 H&E (50X)



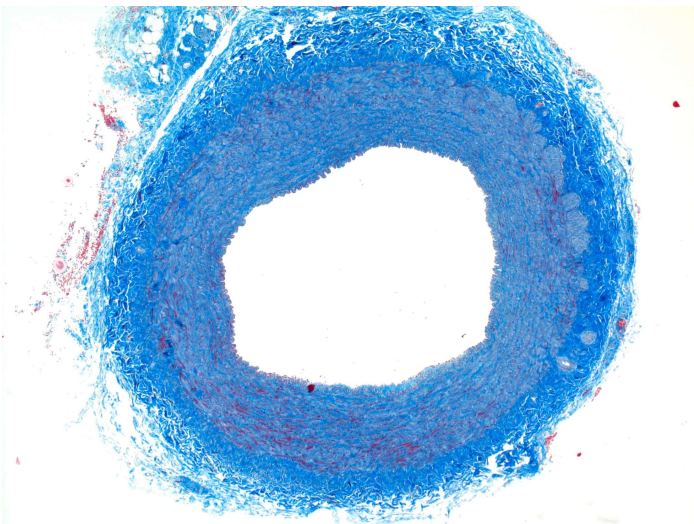
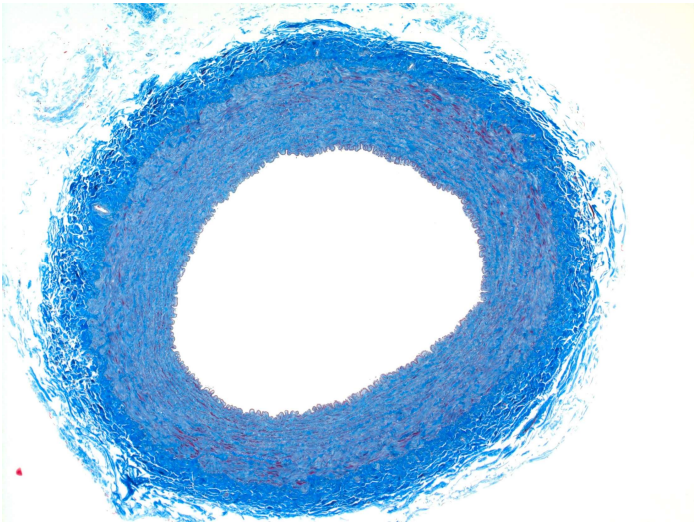
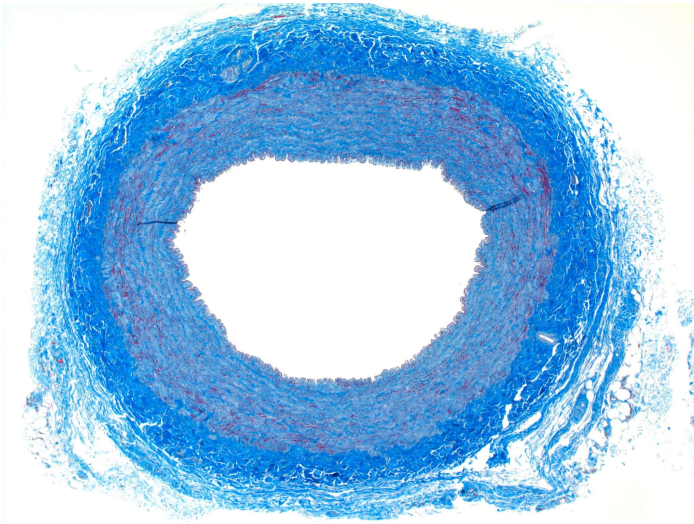
No.10 Masson's Trichrome (50X)



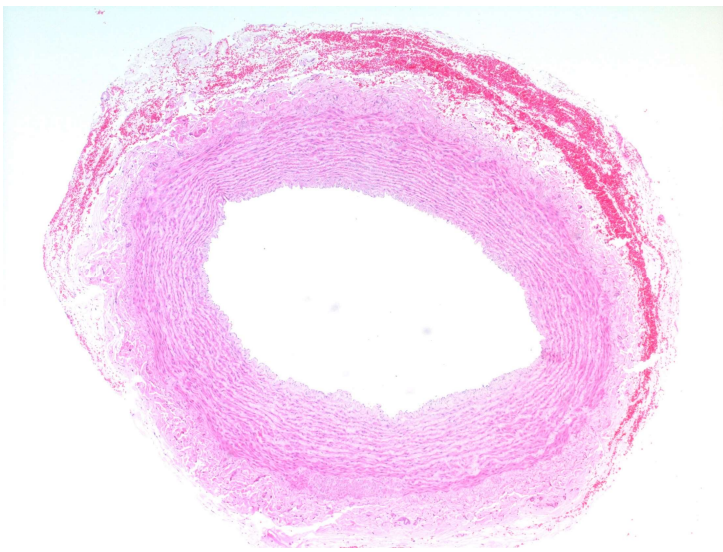


No.11 H&E (50X)



No.11 Masson's Trichrome (50X)



No.12 H&E (50X)



No.12 Masson's Trichrome (50X)

