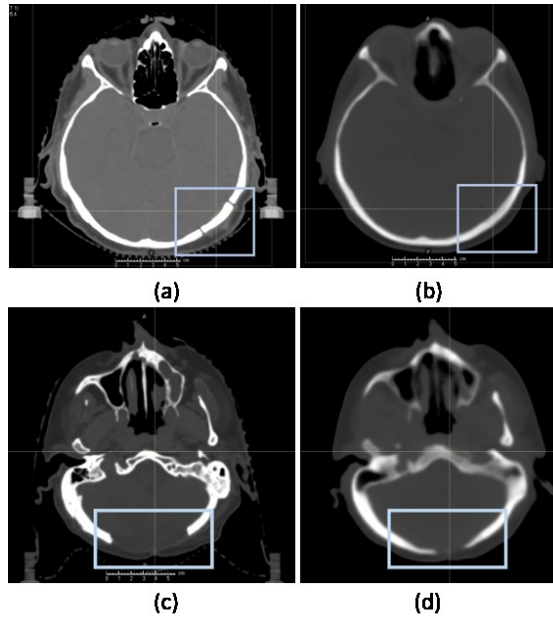


1 **Supplementary Material**

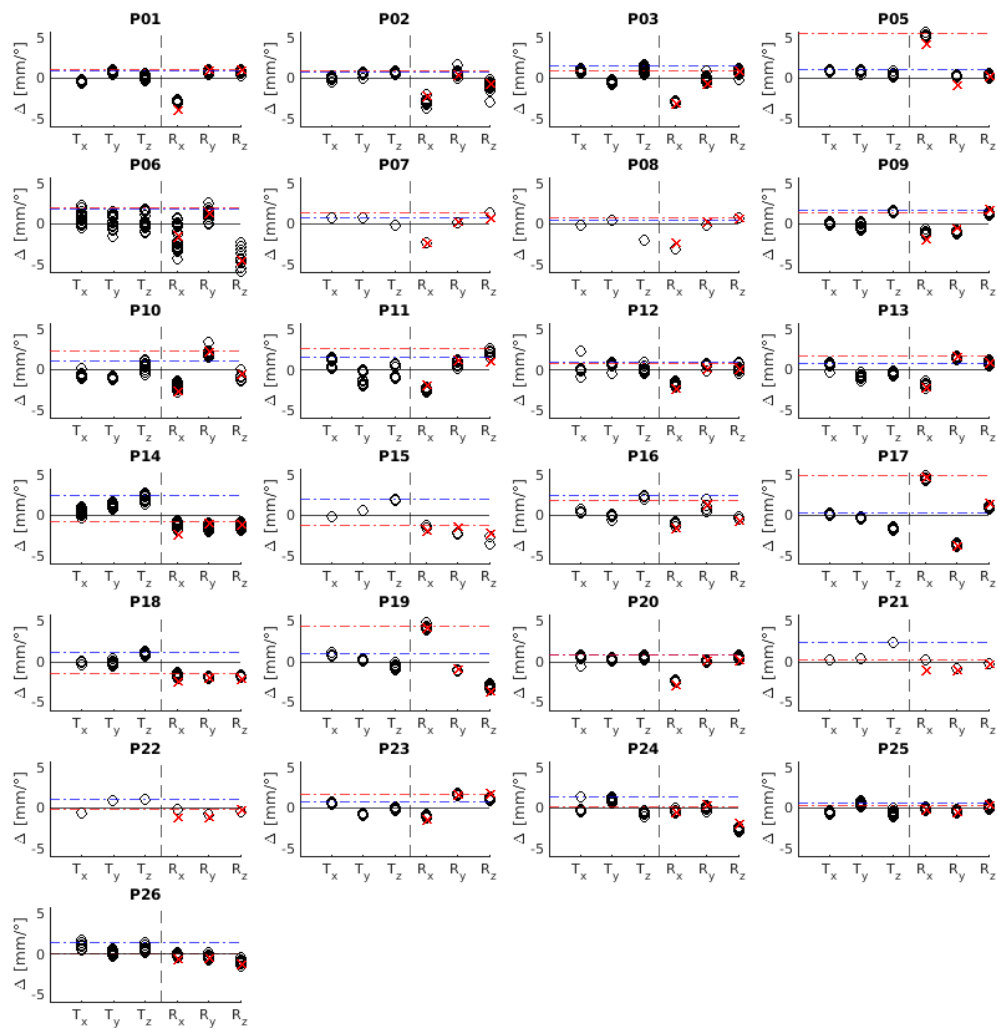
2

3



4

5 *Supplementary Figure S1: Images of two patients who have undergone surgery. Patient 1 (P14): (a) reinserted bone flap (blue*  
6 *box) as seen on conventional CT and (b) its reconstruction on synthetic CT. Patient 2 (P02): (c) removed bone (blue box) as*  
7 *seen on conventional CT and (d) the reconstruction on the synthetic CT.*



8

9

10 *Supplementary Figure S2: Couch shift difference ( $T_x$  (lateral),  $T_y$  (longitudinal),  $T_z$  (vertical)) in mm and couch rotation*  
 11 *difference ( $R_x$  (lateral),  $R_y$  (longitudinal),  $R_z$  (vertical)) in  $^\circ$  for 25 patients (referred as  $\Delta$ ). Red and blue horizontal line represent*  
 12 *the 95th percentile of the couch shift and rotation difference values, respectively. Red crosses mark the rotational difference*  
 13 *between SCT and CT (from rigid registration), due to the variation of mask holder during MRI acquisition.*

14

15