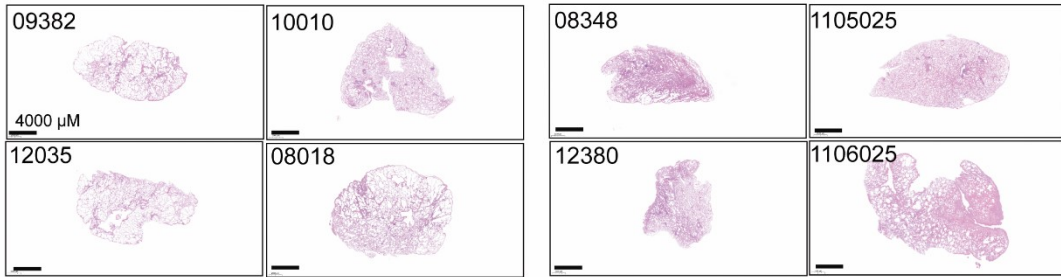


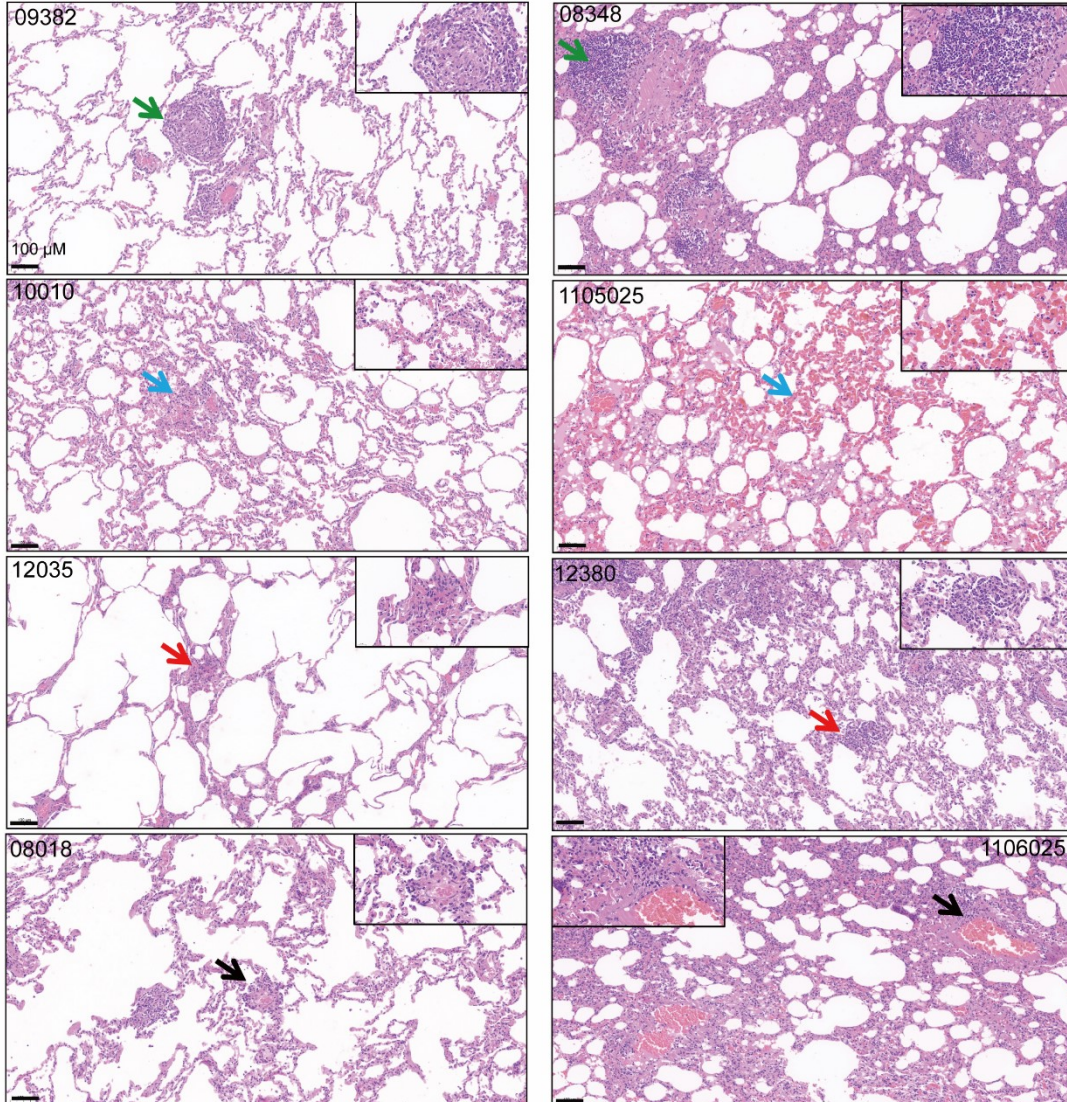
Vaccinated with HR121+IFA

Vaccinated with IFA

a



b



Supplementary information, Fig. S8: Representative histopathological changes in lung tissues of SARS-CoV-2-infected rhesus macaques.

A representative lung tissue section by H&E staining from each rhesus macaque infected with SARS-CoV-2 is presented. Four macaques (ID: 09382, 10010, 12035, 08018) were vaccinated with HR121 plus IFA, and four macaques (ID: 08348, 1105025, 12380, 1106025) were vaccinated with IFA. At least three tissue sections (from upper, middle, and lower lung lobes) were assessed per macaque. **a** A representative scanning image of whole lung tissue section by H&E staining from each rhesus macaque. **b** Representative histopathology in macaques vaccinated with HR121 plus IFA or IFA only. In each layer, the typical histopathological lesions, such as lymphoid proliferation (green arrow), intra-alveolar hemorrhage (blue arrow), alveolar macrophage infiltrates (red arrow), and perivascular macrophage infiltrates (black arrow) are marked.