

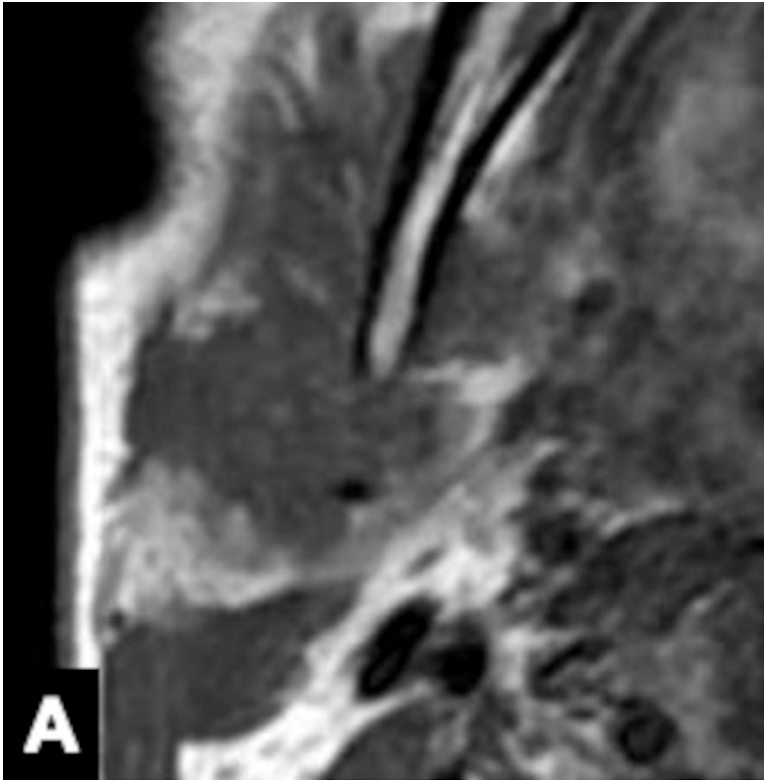Fig. 1' Corona sign on FS-T2WI and CE-FS-T1WI

Invasive CXPA (salivary duct carcinoma) of the right parotid gland in a 77-year-old man. MRI shows a homogeneous low-intensity tumor on axial T1WI (A), mixed high- and low-intensity signals on axial fat-suppressed T2WI (FS-T2WI) (B), and irregularly enhanced signal on axial contrast-enhanced-FS-T1WI (CE-FS-T1WI) (C). The tumor size on FS-T2WI and CE-FS-T1WI was larger than that on T1WI. We defined these MRI findings as corona signs on FS-T2WI and CE-FS-T1WI.

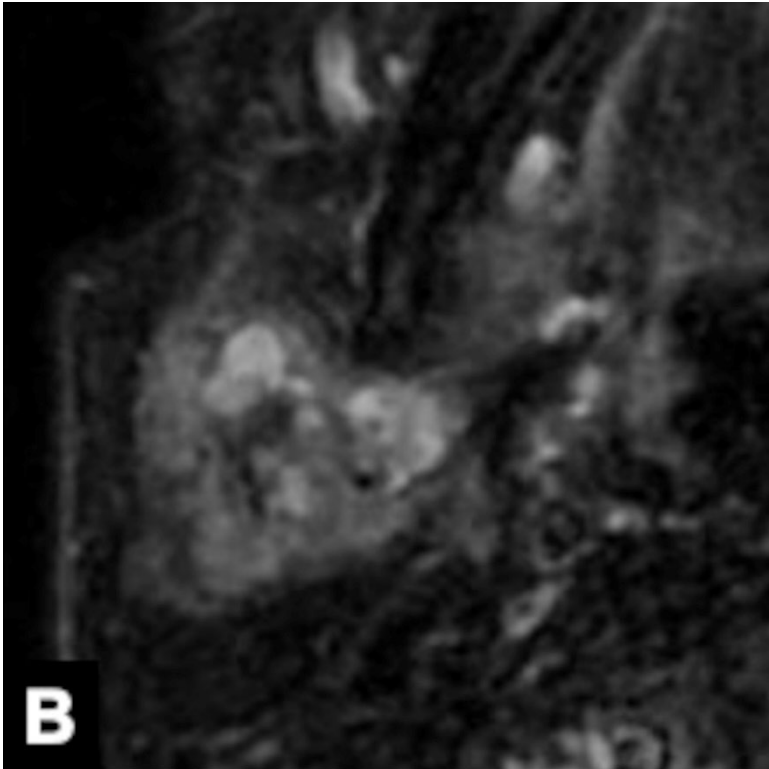


Fig. 1' *Corona sign on FS-T2WI and CE-FS-T1WI*

Invasive CXPA (salivary duct carcinoma) of the right parotid gland in a 77-year-old man. MRI shows a homogeneous low-intensity tumor on axial T1WI (A), mixed high- and low-intensity signals on axial fat-suppressed T2WI (FS-T2WI) (B), and irregularly enhanced signal on axial contrast-enhanced-FS-T1WI (CE-FS-T1WI) (C). The tumor size on FS-T2WI and CE-FS-T1WI was larger than that on T1WI. We defined these MRI findings as corona signs on FS-T2WI and CE-FS-T1WI.

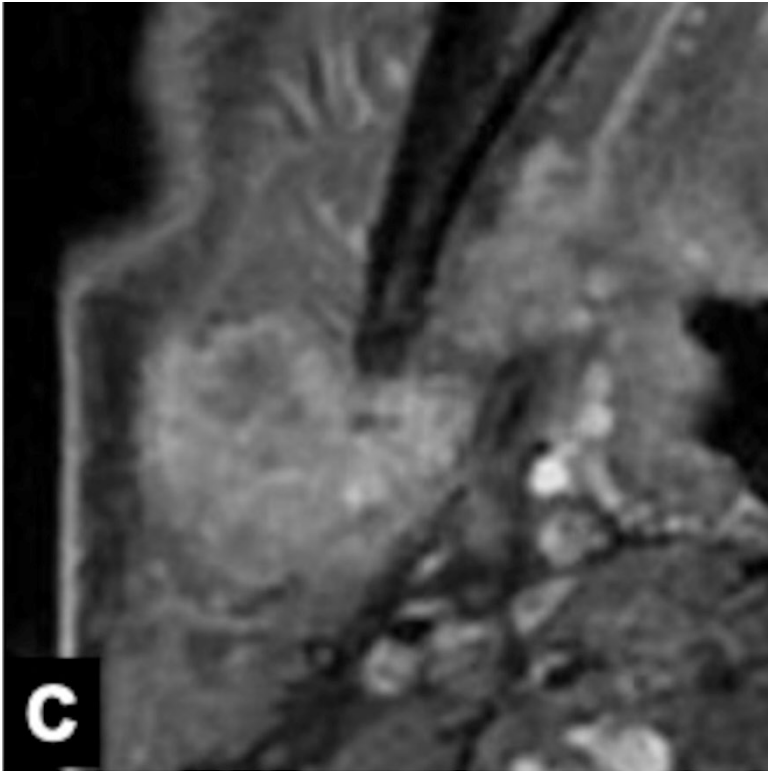


Fig. 1' Corona sign on FS-T2WI and CE-FS-T1WI

Invasive CXPA (salivary duct carcinoma) of the right parotid gland in a 77-year-old man. MRI shows a homogeneous low-intensity tumor on axial T1WI (A), mixed high- and low-intensity signals on axial fat-suppressed T2WI (FS-T2WI) (B), and irregularly enhanced signal on axial contrast-enhanced-FS-T1WI (CE-FS-T1WI) (C). The tumor size on FS-T2WI and CE-FS-T1WI was larger than that on T1WI. We defined these MRI findings as corona signs on FS-T2WI and CE-FS-T1WI.

Supplement. Image evaluation for each evaluator

Border	Rater1	Rater2	Rater3
Case 1	0	0	1
Case 2	0	0	0
Case 3	1	1	2
Case 4	0	1	0
Case 5	1	1	2
Case 6	2	2	2
Case 7	1	1	2
Case 8	1	1	2
Case 9	0	0	1
Case 10	1	1	2
Case 11	1	1	1
Case 12	0	1	1
Case 13	1	1	1
Case 14	0	0	0
Case 15	1	1	2
Case 16	1	1	2
Case 17	0	1	1
Case 18	0	0	1
Case 19	1	1	1
Case 20	0	0	1
Case 21	1	2	2
Case 22	1	1	2
Case 23	1	2	2
Case 24	0	1	2
Case 25	2	2	2
Case 26	0	1	1
Case 27	1	1	0
Case 28	1	2	2
Case 29	0	0	1
Case 30	0	1	1
Case 31	1	1	2
Case 32	1	2	1

Case 33	0	0	1
Case 34	1	2	2
Case 35	0	0	1
Case 36	0	1	2
Case 37	1	1	1

(0:well defined, 1:partially ill-defined, 2:totally ill-defined)

Capsule	Rater1	Rater2	Rater3
Case 1	0	0	1
Case 2	0	0	0
Case 3	2	1	2
Case 4	0	1	0
Case 5	2	1	2
Case 6	2	2	2
Case 7	2	1	2
Case 8	2	1	2
Case 9	0	1	1
Case 10	1	1	2
Case 11	0	1	0
Case 12	2	2	2
Case 13	2	1	2
Case 14	0	1	0
Case 15	1	2	2
Case 16	1	1	2
Case 17	1	1	1
Case 18	0	1	1
Case 19	1	1	1
Case 20	0	0	1
Case 21	2	2	2
Case 22	1	2	2
Case 23	1	2	1
Case 24	1	2	2
Case 25	1	2	2
Case 26	0	2	1
Case 27	0	1	0

Case 28	2	2	2
Case 29	0	0	1
Case 30	0	1	1
Case 31	0	1	2
Case 32	0	1	1
Case 33	1	0	1
Case 34	1	1	1
Case 35	0	0	0
Case 36	0	0	1
Case 37	1	1	1

(0:none, 1:partial, 2: total)

Black ring sign	Rater1	Rater2	Rater3
Case 1	0	0	0
Case 2	0	0	0
Case 3	1	1	1
Case 4	0	0	0
Case 5	1	1	1
Case 6	1	1	1
Case 7	1	1	1
Case 8	0	0	0
Case 9	0	0	0
Case 10	1	1	1
Case 11	0	0	0
Case 12	0	0	0
Case 13	1	1	1
Case 14	0	0	0
Case 15	1	1	1
Case 16	0	0	0
Case 17	0	0	0
Case 18	0	0	0
Case 19	1	1	1
Case 20	0	0	1

Case 21	1	1	1
Case 22	1	1	1
Case 23	1	1	1
Case 24	1	1	1
Case 25	0	1	1
Case 26	0	0	0
Case 27	0	0	0
Case 28	0	0	0
Case 29	0	0	0
Case 30	0	1	0
Case 31	1	1	1
Case 32	0	0	0
Case 33	0	0	0
Case 34	0	1	1
Case 35	0	0	0
Case 36	1	1	1
Case 37	1	1	1

(0:absent, 1:present)

Corona sign on FS-T2WI	Rater1	Rater2	Rater3
Case 1	0	0	0
Case 2	0	0	0
Case 3	1	1	1
Case 4	0	0	0
Case 5	1	1	1
Case 6	1	1	1
Case 7	1	1	1
Case 8	1	1	1
Case 9	0	0	0
Case 10	0	1	0
Case 11	0	0	0
Case 12	0	0	0
Case 13	0	1	1

Case 14	0	0	0
Case 15	0	1	1
Case 16	1	1	1
Case 17	0	1	0
Case 18	0	0	0
Case 19	1	1	1
Case 20	1	1	1
Case 21	1	1	1
Case 22	1	1	1
Case 23	1	1	1
Case 24	1	1	1
Case 25	1	1	1
Case 26	1	1	1
Case 27	1	1	0
Case 28	1	1	1
Case 29	0	0	0
Case 30	1	1	1
Case 31	1	1	1
Case 32	1	1	0
Case 33	0	1	0
Case 34	1	1	1
Case 35	0	0	0
Case 36	0	1	0
Case 37	1	1	1

(0:absent, 1:present)

Corona sign on CE-FS-T1WI	Rater1	Rater2	Rater3
Case 1	0	0	0
Case 2	0	1	1
Case 3	1	1	1
Case 4	0	0	0
Case 5	1	1	1
Case 6	1	1	1

Case 7	1	1	1
Case 8	1	1	1
Case 9	0	0	0
Case 10	0	1	0
Case 11	1	0	0
Case 12	0	0	0
Case 13	0	1	1
Case 14	0	0	0
Case 15	1	1	1
Case 16	1	1	1
Case 17	0	1	0
Case 18	0	0	0
Case 19	1	1	1
Case 20	1	1	1
Case 21	2	2	2
Case 22	1	1	1
Case 23	1	1	1
Case 24	1	1	1
Case 25	1	1	1
Case 26	1	1	1
Case 27	1	1	0
Case 28	1	1	1
Case 29	0	0	0
Case 30	1	1	1
Case 31	1	1	1
Case 32	1	1	1
Case 33	0	1	0
Case 34	1	1	1
Case 35	2	2	2
Case 36	0	0	0
Case 37	1	1	1

(0:absent, 1:present, 2:lack of contrast-enhanced images)