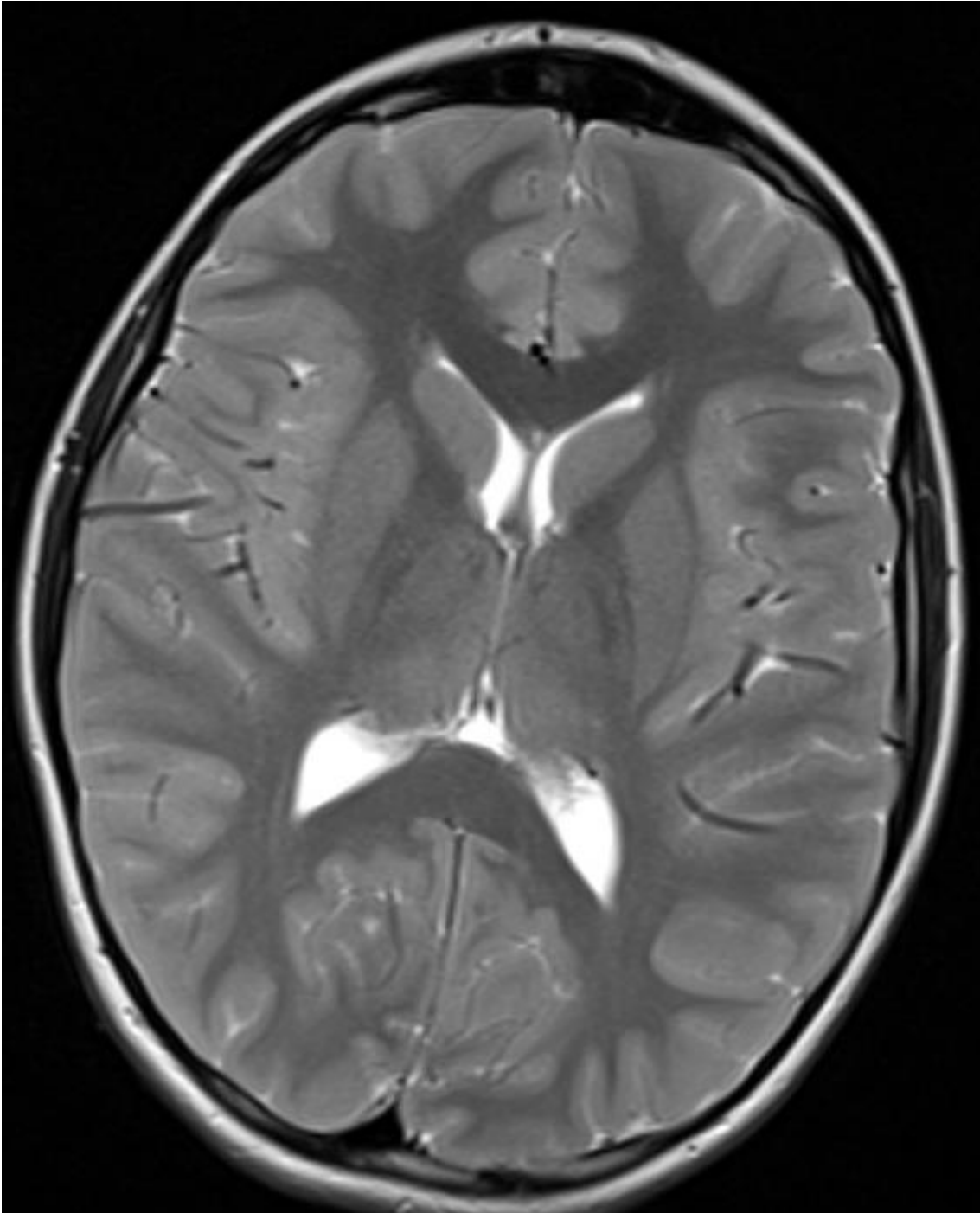
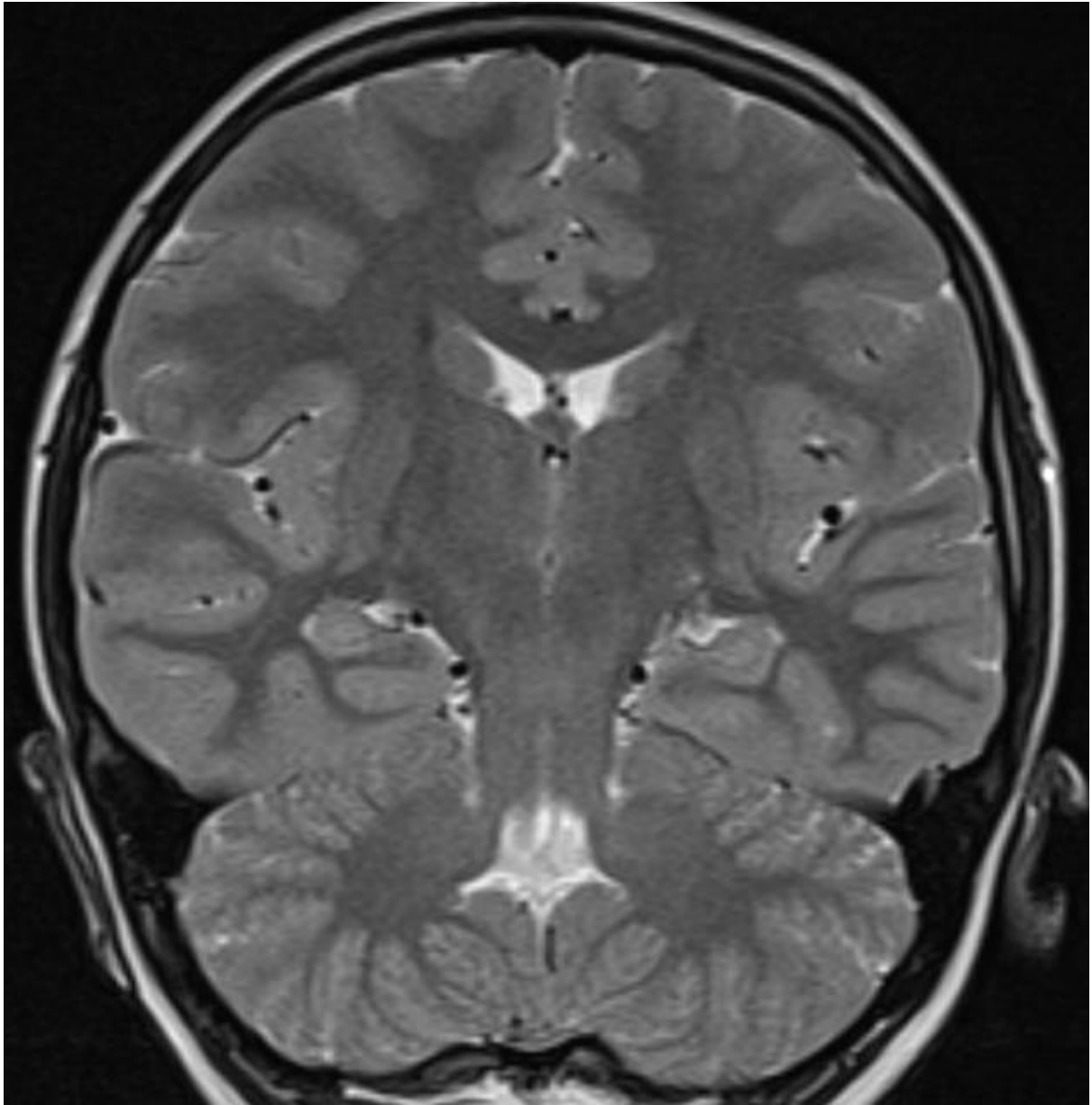


Supplementary Material



Supplementary Image 1: Axial T2-weighted image from MRI study (Patient 3). This was reported as normal.



Supplementary Image 2: Coronal T2-weighted image from MRI study (Patient 3). This was reported as normal.