

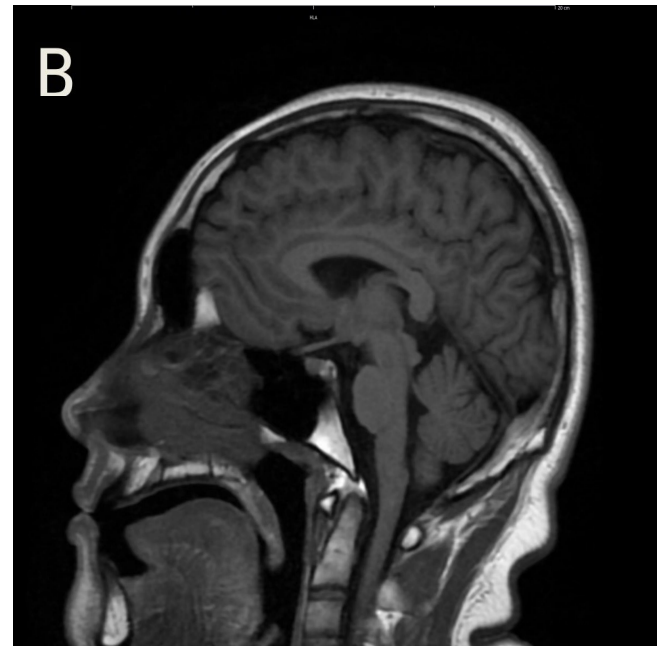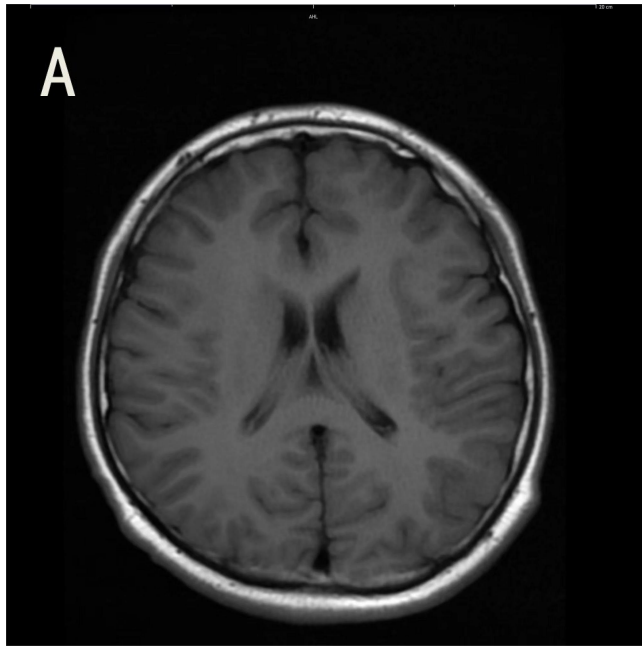Figure1: Brain MRI was normal at 7 years old. MRI. (A, sagittal T1; B, axial FLAIR)

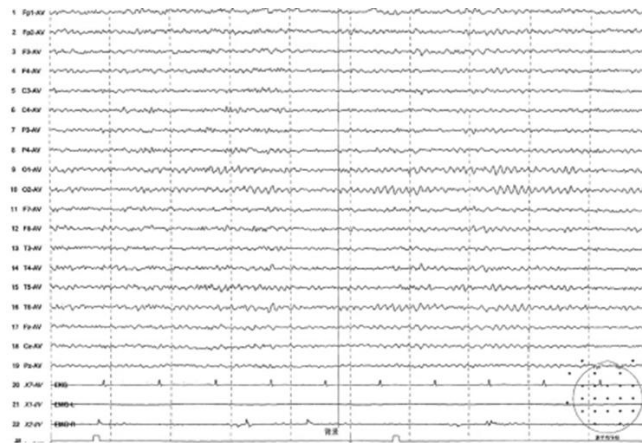


Figure2: EEG was normal at 7 years old.