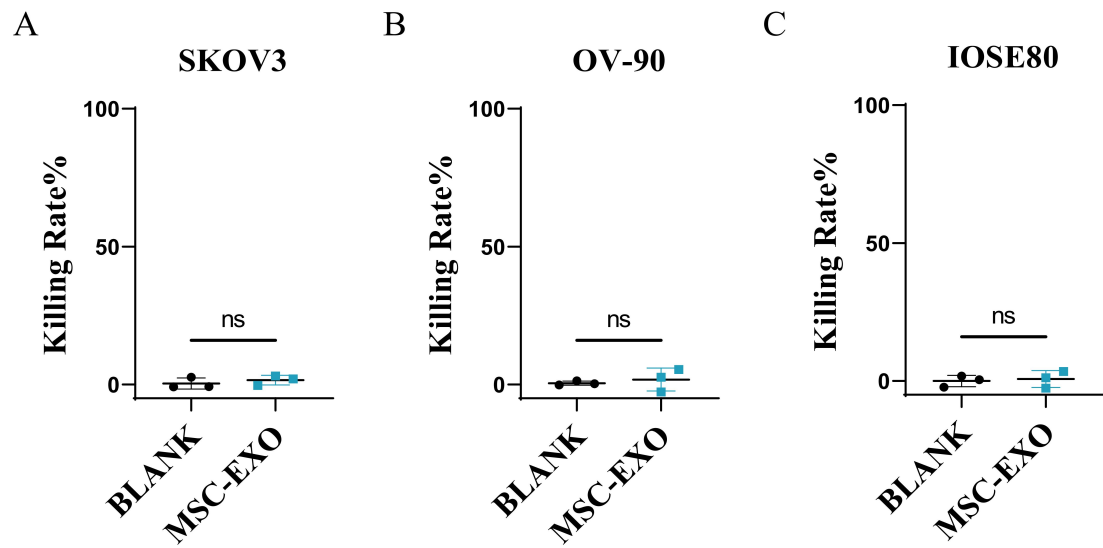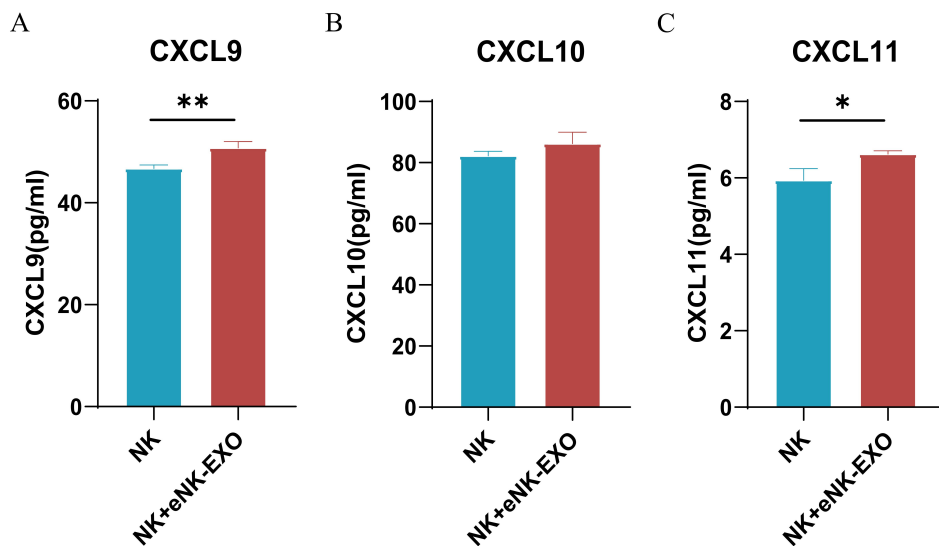


Supplementary Figure S1 Anti-tumor activity of MSC-exo *in vitro*. CCK-8 assay showing the cytotoxicity of MSC-exo against SKOV3(A), OV-90(B) and IOSE80 (C) (n=3, mean \pm SEM).



Supplementary Figure S2 ELISA measurement of CXCL9(A), CXCL10(B) and CXCL11(C) level in the supernatants of eNK-EXO treated NK cells (n=3, mean \pm SEM, ** $p < 0.05$, *** $p < 0.01$).

Supplementary Table S1 The clinicopathological features of 7 ovarian cancer patients.

NO.	Age (year)	Pathologic type	FIGO stage	Peritoneal metastasis
#1	33	Malignant ovarian cancer	IV	Yes
#2	53	High-grade serous carcinoma	IIIC	Yes
#3	45	Mucinous cystadenocarcinoma	IC	NO
#4	63	Clear cell carcinoma	IIA	Yes
#5	55	High-grade serous carcinoma	IIIC	Yes
#6	69	High-grade serous carcinoma	IIIC	Yes
#7	44	High-grade serous carcinoma	IIIC	Yes