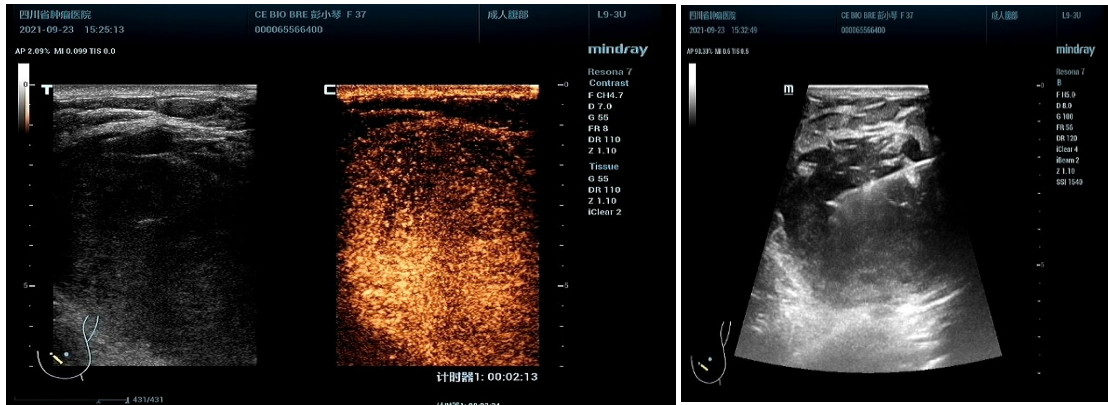
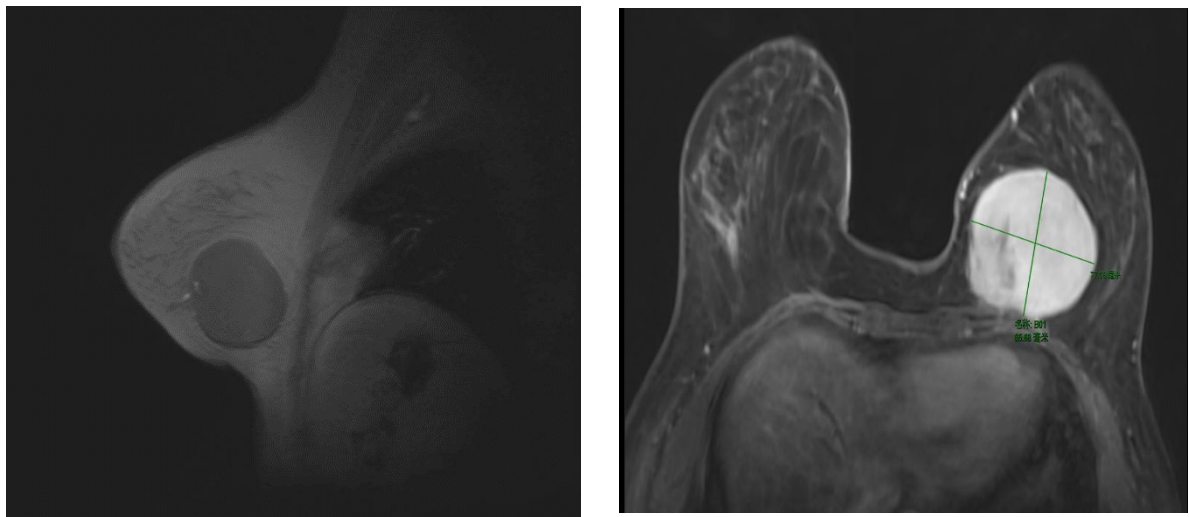


First visit

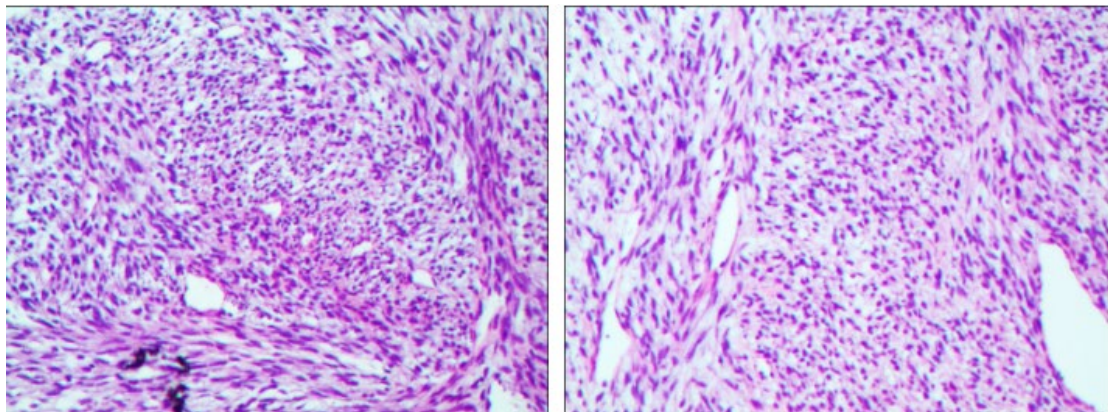
Contrast-enhanced ultrasound and needle biopsy were performed



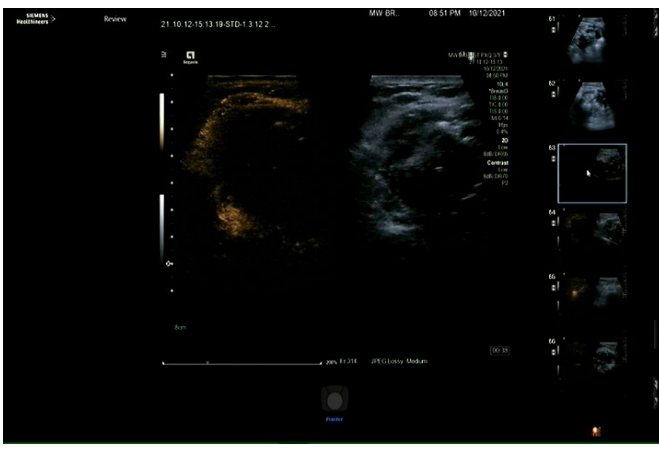
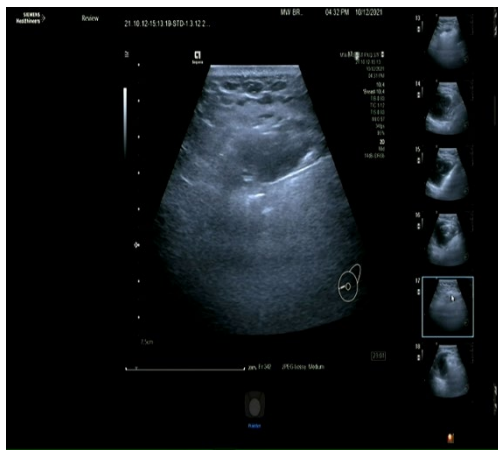
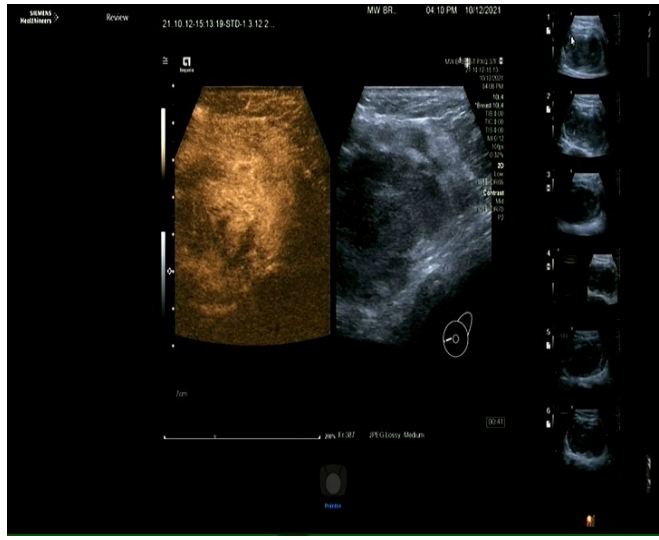
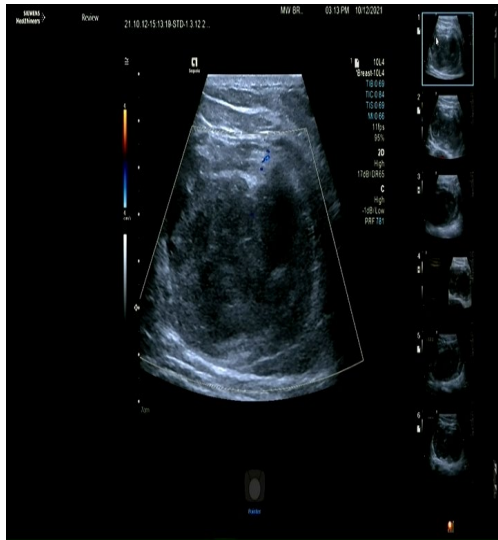
MRI



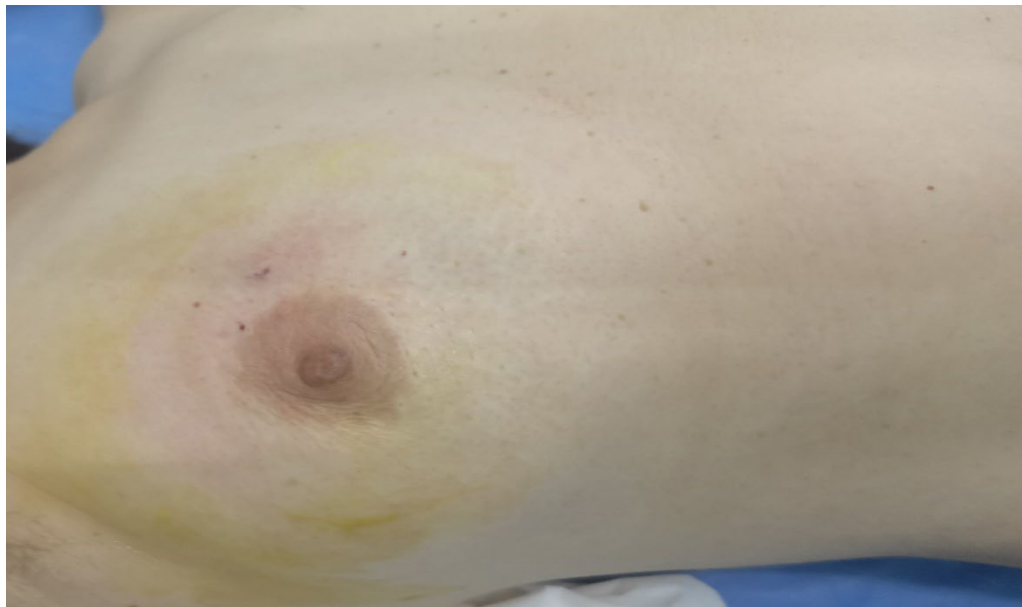Pathology



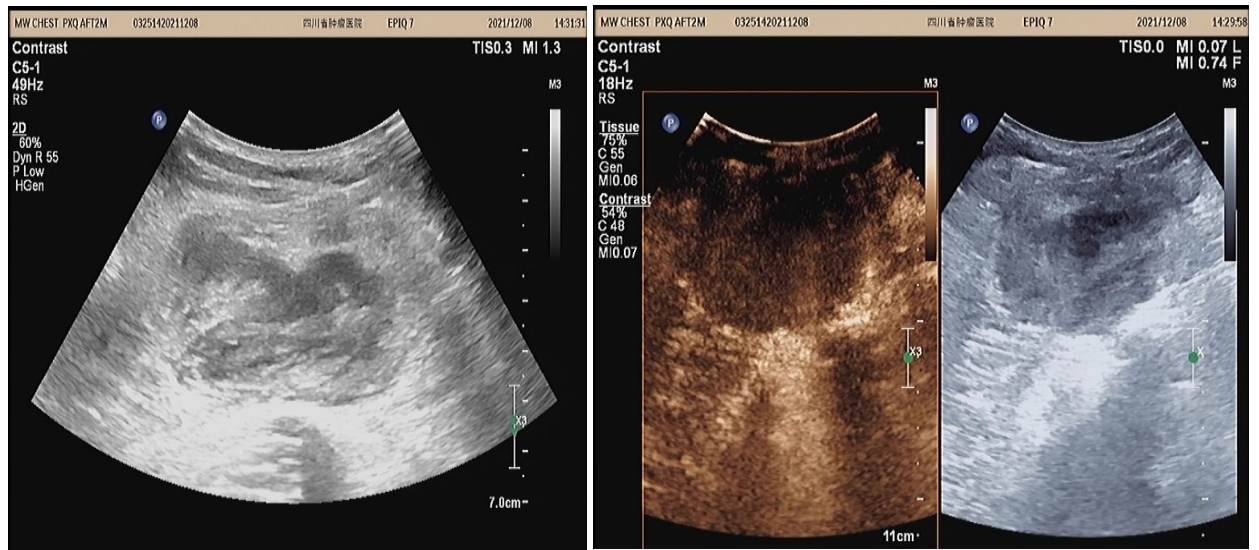
microwave ablation



Postoperative breast appearance



The patients were followed up after 3 months



The patients were followed up after 10 months

