

Supplementary materials

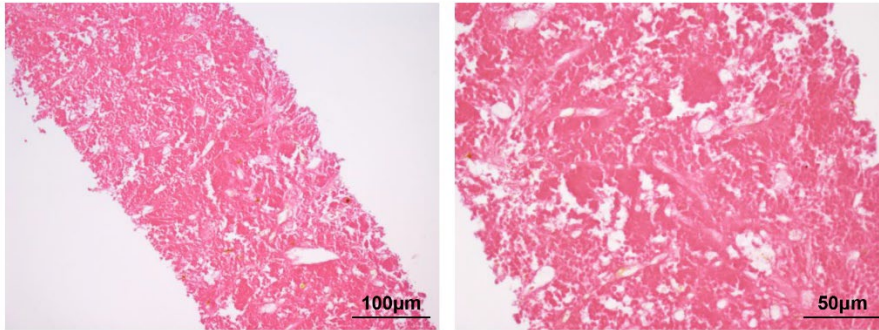


Figure S1 Hematoxylin and eosin staining of neck mass (original magnification: 100 \times and 200 \times). The pathological examination revealed the necrosis of neck mass 1 month after CAR-T cell therapy combined with cryoablation.